This is a digital copy of a book that was preserved for generations on library shelves before it was carefully scanned by Google as part of a project to make the world's books discoverable online.

It has survived long enough for the copyright to expire and the book to enter the public domain. A public domain book is one that was never subject to copyright or whose legal copyright term has expired. Whether a book is in the public domain may vary country to country. Public domain books are our gateways to the past, representing a wealth of history, culture and knowledge that's often difficult to discover.

Marks, notations and other marginalia present in the original volume will appear in this file - a reminder of this book's long journey from the publisher to a library and finally to you.

Usage guidelines

Google is proud to partner with libraries to digitize public domain materials and make them widely accessible. Public domain books belong to the public and we are merely their custodians. Nevertheless, this work is expensive, so in order to keep providing this resource, we have taken steps to prevent abuse by commercial parties, including placing technical restrictions on automated querying.

We also ask that you:

+ *Make non-commercial use of the files* We designed Google Book Search for use by individuals, and we request that you use these files for personal, non-commercial purposes.
+ *Refrain from automated querying* Do not send automated queries of any sort to Google's system: If you are conducting research on machine translation, optical character recognition or other areas where access to a large amount of text is helpful, please contact us. We encourage the use of public domain materials for these purposes and may be able to help.
+ *Maintain attribution* The Google "watermark" you see on each file is essential for informing people about this project and helping them find additional materials through Google Book Search. Please do not remove it.
+ *Keep it legal* Whatever your use, remember that you are responsible for ensuring that what you are doing is legal. Do not assume that just because we believe a book is in the public domain for users in the United States, that the work is also in the public domain for users in other countries. Whether a book is still in copyright varies from country to country, and we can't offer guidance on whether any specific use of any specific book is allowed. Please do not assume that a book's appearance in Google Book Search means it can be used in any manner anywhere in the world. Copyright infringement liability can be quite severe.

About Google Book Search

Google's mission is to organize the world's information and to make it universally accessible and useful. Google Book Search helps readers discover the world's books while helping authors and publishers reach new audiences. You can search through the full text of this book on the web at `http://books.google.com/`

Transactions

American Medical Association. Section on orthopedic surgery

Digitized by Google

THE UNIVERSITY OF MICHIGAN · LIBRARIES ·
THE UNIVERSITY OF MICHIGAN
1817
Digitized by Google

Digitized by Google

Digitized by Google

TRANSACTIONS OF THE

SECTION ON

Orthopedic Surgery

of the
American Medical Association
at the Sixty-Sixth Annual
Session, held at San Francisco,
June 22 to 25, 1915

AMERICAN MEDICAL ASSOCIATION PRESS
CHICAGO: NINETEEN HUNDRED AND FIFTEEN

Digitized by Google

med
[illegible]5
A5
M5
A8or
1915

Reprinted from
THE JOURNAL
of the
AMERICAN MEDICAL ASSOCIATION

Copyright 1915
by the
American Medical Association

Digitized by Google

Gift 8/1/17

OFFICERS FOR 1914-1915

CHAIRMAN

NATHANIEL ALLISON - - - - - - - - ST. LOUIS

VICE CHAIRMAN

R. A. HIBBS - - - - - - - - - - - NEW YORK

SECRETARY

EMIL S. GEIST - - - - - - - - MINNEAPOLIS

EXECUTIVE COMMITTEE

ARTHUR J. GILLETTE, ST. PAUL
NEWTON M. SHAFFER, NEW YORK
LEONARD W. ELY, SAN FRANCISCO

OFFICERS FOR 1915-1916

CHAIRMAN

RUSSELL A. HIBBS - - - - - - - - NEW YORK

VICE CHAIRMAN

E. W. RYERSON - - - - - - - - - - CHICAGO

SECRETARY

EMIL S. GEIST - - - - - - - - MINNEAPOLIS

EXECUTIVE COMMITTEE

NEWTON M. SHAFFER, NEW YORK
LEONARD W. ELY, SAN FRANCISCO
NATHANIEL ALLISON, ST. LOUIS

Digitized by Google

Digitized by Google

LIST OF OFFICERS

The Section was created in 1912, and has been served by the following officers:

1912-13	Chairman, Newton M. Shaffer, New York. Secretary, John Ridlon, Chicago.
1913-14	Chairman, Leonard W. Ely, San Francisco. Vice Chairman, Nathaniel Allison, St. Louis. Secretary, Emil S. Geist, Minneapolis.
1914-15	Chairman, Nathaniel Allison, St. Louis. Vice Chairman, R. A. Hibbs, New York. Secretary, Emil S. Geist, Minneapolis. Delegate, John Ridlon, Chicago.
1915-16	Chairman, Russell A. Hibbs, New York. Vice Chairman, E. W. Ryerson, Chicago. Secretary, Emil S. Geist, Minneapolis. Delegate, John Ridlon, Chicago.

Digitized by Google

Digitized by Google

CONTENTS

PAGE

List of Officers 5

Proceedings of the Section 9

Chairman's Address: Orthopedic Surgery and the Crippled. Nathaniel Allison 13

Late Results of Excision of the Transverse Process of the Fifth Lumbar Vertebra. Fred J. Fassett 19

Lesions of the Lumbosacro-Iliac Region. A Study of the Various Types. Harry Leslie Langnecker 30

Operative Treatment of Bunions by the Mayo Method. Melvin S. Henderson 39

Anteversion of the Neck of the Femur in Connection with Congenital Dislocation of the Hip. Russell A. Hibbs .. 48

Congenital Dislocation of the Hip Reduced by Manipulation Followed by Arthrotomy. James T. Watkins 52

Structural Changes in Congenital Hip Dislocation. Wallace Blanchard 58

Painful Feet, Causes and Treatment. Henry W. Frauenthal 67

Lymphoid Marrow and Tuberculosis. An Experimental Study. Leonard W. Ely 84

The Roentgenographic Appearances in Rickets with a Comment on Differential Diagnosis. Robert W. Lovett 99

Subperiosteal Resection in Osteomyelitis. A Clinical and Experimental Study. D. B. Phemister 109

Knee Joint Disability Caused by Hypertrophy of the Alar Ligaments. Roland O. Meisenbach 127

Modern Treatment of Fractures of the Long Bones from the Orthopedic Point of View, with Clinical Observations and Conclusions. J. W. Cokenower 138

Fractures. New Ideas and New Instruments. H. R. Allen 145

The Experimental Transplantation of the Epiphysis with Observations on the Longitudinal Growth of Bone. S. L. Haas 155

Digitized by Google

CONTENTS—Continued

PAGE

The Rôle of the Nose, Throat and Accessory Sinuses in the Etiology of Chronic Infectious Arthritis. Roland Hammond 176

The Clinical Type of Arthritis Originating About the Teeth. Thomas B. Hartzell..... 184

Syphilis of the Spine. Its Frequency and the Value of Its Characteristic Lesions as a Diagnostic Sign of Syphilis. James L. Whitney and Walter I. Baldwin... 196

Juvenile Deforming Osteochondritis of the Hip. George J. McChesney 210

Report of Committee on Therapeutic Methods and Results in Joint Tuberculosis. L. W. Ely, J. A. O'Reilly and H. W. Orr..... 219

Index 221

Digitized by Google

PROCEEDINGS OF THE SECTION

TUESDAY, JUNE 22—AFTERNOON

The meeting was called to order at 2 p. m. by the chairman, Dr. Nathaniel Allison, St. Louis.

Dr. Allison then read the chairman's address, entitled "Orthopedic Surgery and the Crippled." No discussion.

Dr. Fred J. Fassett, Seattle, read a paper on "Late Results of Excision of the Transverse Process of the Fifth Lumbar Vertebra." Discussed by Drs. M. S. Henderson, Rochester, Minn.; E. W. Ryerson, Chicago; Wallace Blanchard, Chicago; Roland O. Meisenbach, Buffalo; J. P. Lord, Omaha, and Fred J. Fassett, Seattle.

Dr. H. L. Langnecker, Boston, read a paper on "Lesions of the Lumbo-Sacro-Iliac Region." Discussed by Drs. C. C. Crane, San Francisco; Fred J. Fassett, Seattle; Leonard W. Ely, San Francisco; J. T. Rugh, Philadelphia; John Ridlon, Chicago; C. E. McClure, Portland, Ore.; Roland O. Meisenbach, Buffalo; C. L. Lowman, Los Angeles, and H. Langenecker, San Francisco.

Dr. M. S. Henderson, Rochester, Minn., read a paper on "Surgical Treatment of Bunions (Mayo Method)." Discussed by Drs. E. W. Ryerson, Chicago; John Ridlon, Chicago; J. P. Lord, Omaha; John F. Golden, Chicago; Leonard W. E.y, San Francisco; J. T. Rugh, Philadelphia; B. M. J. Conlin, Long Beach, Calif., and M. S. Henderson, Rochester, Minn.

The following papers were read as a symposium on "Congenital Hip Dislocation":

Dr. Russell A. Hibbs, New York: "Anteversion of Neck of Femur Causing Failure in Treating Congenital Hip Dislocation."

Dr. James T. Watkins, San Francisco: "Congenital Dislocations of the Hip, Reduced by Manipulation Followed by Arthrotomy."

Dr. Wallace Blanchard, Chicago: "Structural Changes in Congenital Hip Dislocations."

Discussed by Drs. John Ridlon, Chicago, and Leonard W. Ely, San Francisco; Russell A. Hibbs, New York; James T. Watkins, San Francisco, and Wallace Blanchard, Chicago.

Digitized by Google

Thursday, June 24—Morning

Minutes of the 1914 meeting of the Section were approved as read.

Nomination and election of officers for the ensuing year resulted as follows: Chairman, Dr. Russell A. Hibbs, New York; Vice-Chairman, Dr. E. W. Ryerson, Chicago; Secretary, Dr. Emil S. Geist, Minneapolis; Delegate to the House of Delegates, Dr. John Ridlon, Chicago; Alternate, Leonard W. Ely, San Francisco.

Report of Committee on "Therapeutic Methods and Results in Joint Tuberculosis" approved as read.

Motion made, seconded and unanimously passed that the above committee be continued, and that the chairman be allowed to change its personnel with the consent of the committee.

Dr. Henry W. Frauenthal, New York, read a paper on "Painful Feet." Discussed by Drs. Robert W. Lovett, Boston; John Ridlon, Chicago; Emil S. Geist, Minneapolis; Roland O. Meisenbach, Buffalo; E. A. Rich, Tacoma; Fred J. Fassett, Seattle; E. W. Ryerson, Chicago, and Henry W. Frauenthal, New York.

Dr. Leonard W. Ely, San Francisco, read a paper on "Tuberculosis and Red Marrow." Discussed by Dr. John Cowan, San Francisco.

Dr. Robert W. Lovett, Boston, read a paper on "Roentgenographic Characteristics of the Bone Changes in Rickets." Discussed by Drs. H. W. Frauenthal, New York; Roland O. Meisenbach, Buffalo; H. R. Allen, Indianapolis; J. T. Rugh, Philadelphia, and R. W. Lovett, Boston.

Dr. D. B. Phemister, Chicago, read a paper on "Subperiosteal Resections in Osteomyelitis." Discussed by Drs. Thomas W. Huntington, San Francisco; J. P. Lord, Omaha; Leonard W. Ely, San Francisco; E. W. Ryerson, Chicago; Roland O. Meisenbach, Buffalo; James Franklin Smith, San Francisco; J. T. Rugh, Philadelphia, and D. B. Phemister, Chicago.

Thursday, June 24—Afternoon

Dr. Roland O. Meisenbach, Buffalo, read a paper on "Knee Joint Disability Caused by Hypertrophy of the Alar Ligaments." Discussed by Drs. Fred J. Fassett, Seattle; J. T. Rugh, Philadelphia, and Roland O. Meisenbach, Buffalo.

Dr. J. W. Cokenower, Des Moines, Iowa, read a paper on "Treatment of Fractures of Long Bones from an Orthopedic Point of View, with Clinical Observations and Conclusions." Discussed by Drs. Roland Hammond, Providence, R. I., Roland O. Meisenbach, Buffalo, and J. W. Cokenower, Des Moines, Iowa.

Digitized by Google

Dr. H. R. Allen, Indianapolis, read a paper on "Fractures—New Ideas and New Instruments." Discussed by Drs. P. C. H. Pahl, Los Angeles; H. M. Sherman, San Francisco, and H. R. Allen, Indianapolis.

Dr. Walter I. Baldwin, San Francisco, read a paper by himself and James L. Whitney on "Syphilis of the Spine." Discussed by Drs. Henry W. Frauenthal, New York; James L. Whitney, San Francisco; D. B. Phemister, Chicago; Carl C. Crane, San Francisco, and Walter I. Baldwin, San Francisco.

Dr. S. L. Haas, San Francisco, read a paper on "Experimental Transplantation of the Epiphysis with Observations on the Longitudinal Growth of Bone." Discussed by Drs. D. B. Phemister, Chicago; J. T. Rugh, Philadelphia; Roland O. Meisenbach, Buffalo, and S. L. Haas, San Francisco.

Dr. George J. McChesney, San Francisco, read a paper on "Juvenile Osteochondritis of the Hip Joint—Report and Exhibition of Three Patients." Discussed by Dr. H. M. Sherman, San Francisco.

The following papers were read as a symposium on "Arthritis":

Dr. Roland Hammond, Providence, R. I.: "Rôle of the Nose, Throat and Accessory Sinuses in Etiology of Chronic, Infectious Arthritis."

Dr. Thomas B. Hartzell, Minneapolis: "The Clinical Type of Arthritis Originating About the Teeth." Discussed by Drs. J. W. Cokenower, Des Moines, Ia.; Emil S. Geist, Minneapolis; Henry W. Frauenthal, New York; H. R. Allen, Indianapolis; M. C. Harding, San Diego; J. P. Lord, Omaha, and Thomas B. Hartzell, Minneapolis.

Digitized by Google

Digitized by Google

ORTHOPEDIC SURGERY AND THE CRIPPLED *

NATHANIEL ALLISON, M.D.
ST. LOUIS

There are certain obvious truths concerning orthopedic surgery and the orthopedic surgeon to which it is my privilege as your chairman to call your attention. Orthopedic surgery is best defined as the special branch of surgery which includes the consideration of the deformities of the framework of the human body; of the diseases and lesions of the bones and joints; and of the peculiarities or defects in the muscular system. The orthopedic surgeon takes an especial interest in the surgical problems which arise within the boundaries just defined. Of necessity he finds the major portion of his work in lessening the difficulties that face the cripple. In not so very remote times our specialty considered only the correction of deformities which had been established by either accident or disease. At present we may divide the crippled into two classes: the actual cripple, that is, he who is either deformed or made lame and will remain so; and the potential cripple, he who is diseased or injured in such a way that before him lies the possibility either of becoming an actual cripple or of having such a condition prevented or alleviated.

In our various relations as orthopedic surgeons to the cripple it might be said that we are chiefly interested in the potential cripple. Here we still have the chance to prevent deformity, and we spend our efforts in the careful analysis of the causes of disease and disability with this end in view. We attempt constantly to improve our methods of surgical treatment

* Chairman's Address.

Digitized by Google

which are focused on repair and restitution of function. Indeed, our minds become so absorbed in these surgical problems that we for the time may lose sight of the fate of those of our patients who are doomed to a greater or less degree of crippledom throughout life.

Orthopedic surgery may be said to be essentially conservative in its character. For those who are potentially crippled we have our hospitals and convalescent homes, our fresh air and sunshine wards in the open country, in the mountains and at the seaside. We are familiar with the work accomplished in this way, but we realize that, nevertheless, from these places, after all our care and skill have been exerted, there comes a varying percentage of the actually crippled. Again, from the more inaccessible districts of our country and from the metropolitan slum there also comes the neglected case, either an actual or a potential cripple, and we realize that it is in our province to determine the exact status of this cripple; his possibilities for recovery; his chances for assuming a normal place with his fellows in life. We realize our responsibility in believing that well-trained, competent orthopedic surgery must pass both verdict and sentence in this case and that on it falls the burden of decision in separating and classifying the various types and degrees of crippledom, and in being sagacious enough to so judge that even the more remote possibilities of return of physical function and usefulness are included in the vision.

It is to the status of the actual cripple that I wish to call your attention. In former times the cripple remained a cripple, was dependent either on his relatives or the community, and was reduced to the submerged position in society. He became a professional beggar or worked at some occupation that threw into the foreground his pitiable condition and his appeal for sympathy and charity. We realize more fully

Digitized by Google

today the set of problems that faces him and those on whom he naturally depends, but we must realize also the moral claim he has on us as orthopedic surgeons.

Most of us are familiar, I believe, with the excellent report written by Miss Edith Reeves for the Russell Sage Foundation, on the care and education of crippled children in the United States. In this volume is set forth what is being done today in this direction. Among the more important factors brought to light are the following:

There are in the United States thirty-seven places where especial attention is given to the care of crippled children. Four of our states have taken on themselves the establishment of state institutions for their care. Minnesota, New York, Massachusetts and Nebraska have set aside funds and established modern hospitals and schools devoted to the conservation of their crippled children. Primary legislation for institutions of this kind has been adopted in Ohio and Illinois. Michigan and Wisconsin are caring for a small number of cripples in their state homes for dependent children.

The distribution of the thirty-seven institutions listed in this report is as follows: Maine 1; Massachusetts 2; Connecticut 1; New Jersey 3; New York 12; Pennsylvania 6; Maryland 2; Ohio 1; Illinois 4; Michigan 1; Minnesota 2; Nebraska 1; and Washington 1. Ten of the thirty-seven institutions are in two cities; namely, in New York and Philadelphia. Of the thirty-seven ten are classed as hospitals, fourteen as convalescent hospitals and homes, and thirteen as asylum homes. Seven of these thirteen homes care only for white children, and there is but one asylum home for colored children. There is no institution for crippled children west of Omaha, except in Seattle, and none south of Baltimore. Orthopedic surgery is done in the general hos-

Digitized by Google

pitals in the South and West in cities like Charleston, Atlanta, New Orleans, Galveston, Los Angeles and San Francisco, but the work leaves the rural districts practically untouched.

As to the number of children cared for during the year, it is stated that in ten hospitals 662 were treated; in the convalescent hospitals and homes 945; and in the asylum homes 361; making a total of 1,968.

Let us turn now to the actual number of crippled persons in the United States. H. Winnett Orr has stated that with a population of one million there are cripples to the number of 3,500. According to Sir John Beyers there are a half million cripples in Germany, and the census of England shows that there are over 400,000 in that country. Professor Lange has stated that there are 98,000 crippled children in Germany. We have no accurate means of knowing what the numbers are in the United States, as our present census arrangement does not consider the taking of this information, but, according to the proportion of crippled persons in Germany, we should have about 133,000 crippled children under 14 years of age. Estimates run from 50,000 to 250,000 and vary with the enthusiasm of the person making the calculation. Of this, however, we are certain, that only about 2,000 annually are being cared for in properly equipped institutions. It seems, therefore, that what work is being done is located in our large centers, that orthopedic surgeons are collected in these centers, and that the rural districts are uncared for, and that on the whole the work in behalf of the cripple is truly in its infancy.

Much information on this subject is set forth in the excellent journal published by the Federation of Associations for Cripples and edited by Douglas C. McMurtrie of New York. This valuable adjunct to the work is also young, the first volume having appeared in 1914. In the pages of this journal one

Digitized by Google

may trace the history of the effort in various countries of the world to better the physical and economic condition of the cripple. We as orthopedic surgeons may take considerable pride in the fact that always the orthopedic surgeon has inspired and advanced this effort. In our own land most of the work so far done has been accomplished by a comparatively few men. In the introduction to the report of the Russell Sage Foundation the following statement is particularly pleasant and gratifying to us:

> It is fair to say that the credit for this unique spirit in institutions for crippled children is due chiefly to the unselfish devotion of the orthopedic surgeons who lead the movement. Their spirit does not differ in kind from that of their brothers in other hospitals and other kinds of medico-philanthropic work, but this particular field offers a peculiar opportunity for the development and manifestation of altruism in its highest perfection. The patients are under care for a longer period than those in other hospitals, and the results are notable because of the special handicap.

To accept this praise is to admit our responsibility.

The Section on Orthopedic Surgery of the American Medical Association has peculiar possibilities for the advancement of this most human of works. To me it seems that each member of this section who calls himself an orthopedic surgeon should realize the obligation that rests on him to educate his community and his state to the realization of the following facts: First, that the education of crippled children should be a special education, and second, that vocational training suited to the individual's capacity should be carried out and that this training should be given in a place suited to the physical condition of the cripple. Above all, that this special education is not an affair of private charity or philanthropy, but that it is the duty of the state—a duty made imperative not only by humanitarian considerations, but also by economic reasons.

It will be our privilege as orthopedic surgeons to stimulate proper legislative measures in our various

Digitized by Google

states and to direct and advise the state authorities in this field of administration, and we must fit ourselves for this great mission.

If 50,000 crippled individuals lead lives of dependence and economic uselessness in our country, the fault is due to ignorance, and if ignorance exists on this vital topic the fault is largely ours. When we as orthopedic surgeons fully realize our place in the scheme of things, when we see with clear eyes our privileges, our duties, and our possibilities, then we shall have justified our position and our claims.

Humboldt Building.

Digitized by Google

LATE RESULTS OF EXCISION OF THE TRANSVERSE PROCESS OF THE FIFTH LUMBAR VERTEBRA

FRED J. FASSETT, M.D.
SEATTLE

Notwithstanding the study given to the region of the lumbosacral junction in the past decade, so few reports of the results of excision of the transverse process have appeared that these three cases may be worth putting on record.

CASE 1.—A man, aged 24, formerly a sailor now a book salesman, was first seen, April 4, 1910. His complaint was of a "binding" feeling and increasing pain of gradual onset from the hip to the heel on the back of the left lower extremity. He recalled no strain or other injury. The examination was negative except as follows: There was a marked tenderness at about the top of the left sacro-iliac joint, a moderate list to the right and muscle spasm limiting all motions of the lower spine; when the knee was fully extended the left hip could not be flexed more than 45 degrees.

The roentgenogram was negative except as to the transverse processes of the fifth lumbar vertebra; that on the left (the side on which there was pain) was of moderate size and its shadow did not, in this plate, overlap the ilium or sacrum. The process on the right was much larger, distinctly bifid and appeared to articulate with both the ilium and the sacrum (Fig. 1).

During the two months following this examination, adhesive strapping, a canvas belt, plaster jackets in the erect posture and in hyperextension, and plaster spicas were applied. Meanwhile the symptoms all increased. The pain became so severe and constant that the patient eagerly accepted the suggestion of operation even though he knew that it was decidedly experimental in character. At that time I knew that such an operation had been done by Dr. Z. B. Adams of Boston, but was unable to learn either his technic or his results.

Operation was performed in June, 1910. An incision about 4 inches long was made midway between the spinous processes and posterior-superior spine of the right ilium through skin,

Digitized by Google

fascia, and muscle to the bone. It will be noted that this operation was on the side opposite to the side on which there was pain. We removed as much of the bony process which we encountered as we dared, considering that the work had to be done almost exclusively by the sense of touch. The fascia was closed with catgut and the skin with silkworm-gut. The patient was in the hospital ten days. The pain at night, which during the month before the operation had been the most distressing symptom, was temporarily relieved. The pain about the left sacro-iliac joint persisted. A roentgenogram taken two weeks after the operation showed that the transverse process had been possibly thinned but not removed by the operation.

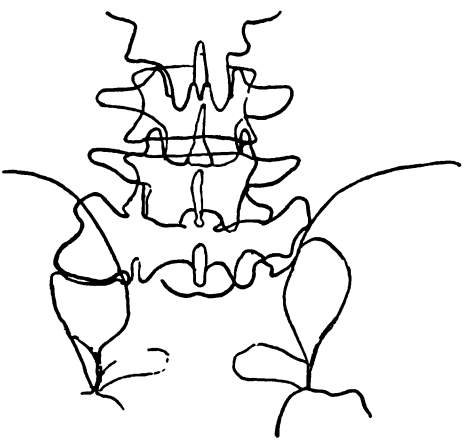

Fig. 1.—Appearance of right transverse process of fifth lumbar vertebra in Case 1 before operation.

In October, four months after the first operation, the old symptoms had all returned. October 18, a second operation was performed (Fig. 2). The incision was made nearer to the crest of the ilium than before. This made the approach to the transverse process more easy, but it was still very difficult. To serve as a landmark, the transverse process of the fourth lumbar vertebra was first identified and, because it might give more room, removed with a wire saw. The transverse process of the fifth was then exposed and an attempt made to pass a wire saw around it in the same manner but without success. The process was then freed from the ilium and sacrum by blunt dissection and from the vertebra by the chisel. At this point the fragment tipped forward on a hinge of fibrous tissue and was recovered and removed with great difficulty. During this procedure there were several sharp twitches in the muscles of the right leg. The wound was then closed as

Digitized by Google

before. During the next ten days the patient became gradually more comfortable, except for slight muscular stiffness in the back and paresthesia in the right foot. The pain and stiffness decreased very rapidly so that the man was soon able to work. He has worked steadily during the past four years. I have seen him occasionally during that time. His only complaint is of a weakness in the right foot. This appears to be a slight but actual paralysis of the muscles of the anterior tibial group, for which no other cause can be found than trauma to the nerve roots at the time of operation. In spite of this symptom the patient regards the operation as a distinct success.

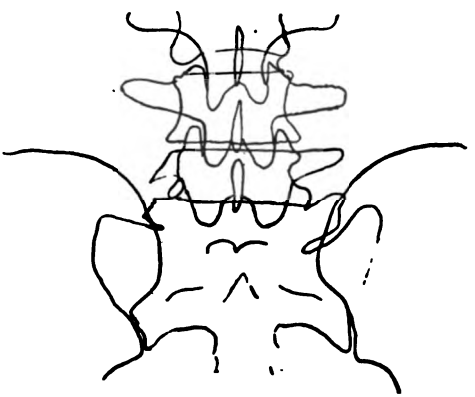

Fig. 2.—Appearance of right transverse process of fifth lumbar vertebra after second operation.

Case 2.—A man, aged 20, a shingle weaver, was first seen July 6, 1911. He gave a history of trouble with the back for the preceding two or three years. The disability had increased much more rapidly in the previous four months and had completely incapacitated him from work. The roentgenogram showed a transverse process of the sacral type on the left side of the fifth lumbar vetebra which formed a distinct articulation with the ilium. There was a marked scoliosis, left dorsal, right lumbar. It was impossible for the man even to approximate an upright position on account of the pain. There was distinct tenderness over the left sacro-iliac joint.

On July 15, 1911, operation was performed essentially as in the second operation on the patient in Case 1, except that the operation was on the same side as the pain and the transverse process of the fourth was not disturbed. The roentgenogram taken soon after the operation showed that the transverse process of the fifth had been removed save for a narrow spur along the lower margin.

Digitized by Google

Clinically the pain was considerably relieved and the posture much improved. The man returned to work, but was unable to work all day because of the return of pain in his back. A year and a half from the first operation the symptoms were still present and a second operation was performed. During this operation there was distinct jerking of the leg muscles. Following the operation there was severe pain in the leg on the operated side. This gradually disappeared but there remained a partial paralysis and atrophy in the anterior tibial group of muscles of the left leg.

The man was last seen May 1, 1915, two and one-half years after the last operation. The pain has been wholly absent for more than two years; the posture shows no trace of the former scoliosis. The weakness in the anterior tibial group of muscles is still present, and the patient says that this occasionally troubles him in running. He regards this, however, as of very slight importance compared with the disability from which he was relieved by the operation. A roentgenogram taken six months after the operation and another taken this year are suggestive of partial regeneration of the process and raise the question whether this regeneration might be expected to occur.[1]

Case 3.—A man, aged 35, an electrician, was first seen Jan. 6, 1914. For several years, on making certain motions, he had "catches" in his lower back. These have several times been so severe that the patient was taken home in the ambulance. The examination was negative except as to the posture and as to the roentgenogram. The patient stood with an exaggerated lordosis, but no lateral deviation. When the lordosis was most marked, that is, when the patient wholly relaxed, there was slight pain in the middle line where the spinous process of the fifth lumbar appeared to overlap the spinous process of the first sacral. There was little muscle spasm, but previous experience had made the patient very loath to attempt certain movements, especially forward bending followed by rotation to the left.

The roentgenogram showed a fifth lumbar vertebra with transverse processes of an intermediate type, the shadows of which overlapped the shadows of the ilium in varying degrees in different plates (Fig. 3). There appeared to be no such complete articulation as was found in the preceding cases. All the customary methods of fixation were faithfully tried, but nothing short of a full-length plaster jacket was adequate to protect against the painful attacks. As this interfered seriously with the man's occupation, he sought relief from practitioners who promised more than I could conscientiously

1. This man was a patient of Dr. Park Weed Willis of Seattle, who showed me the patient while under his treatment, and permits me to include the case in this report. This case and the preceding one were reported by Dr. H. B. Thompson in Northwest Medicine in 1913.

Digitized by Google

promise. One week later he was found in a hospital in genuine agony as a result of an osteopathic or chiropractic "adjustment" received the previous day. The patient had spent the night on the floor of the practitioner's office quite unable either to move or to be moved.

Two weeks later (April 1, 1914) operation was performed on the right side in a manner much like that of the second operation in Case 1. This operation was followed by almost complete sensory paralysis in the right leg. There was no loss of motor power. On the twenty-fifth day the pain was largely relieved and the anesthesia had given place to a paresthesia. The patient left the hospital, but used crutches for about ten days. During the summer, fall and winter of

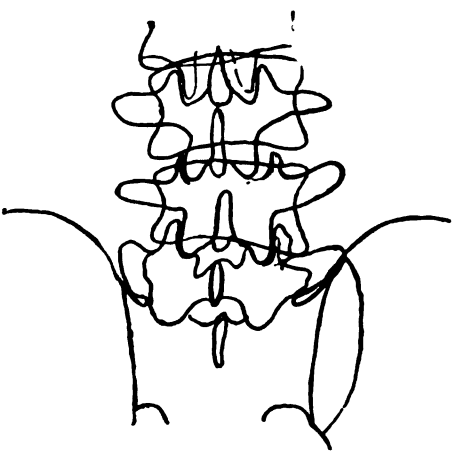

Fig. 3.—Appearance of transverse process of fifth lumbar vertebra in Case 3 before operation.

1914, the patient was able to do hard work as an electrician, crawling into low and narrow spaces with no return of his old pain. The side of the back which was operated on has remained free from pain from that time until the patient was last seen, May 20, 1915 (Fig. 4).

In January, 1915, however, the patient worked for a long time leaning over a low railing. This was followed by a series of "catches" somewhat similar to the old ones, but less severe and strictly confined to the left (the unoperated) side. The patient had been so impressed by the relief obtained on the other side that he argued that the two sides looked so much alike in the roentgenogram that operation should be done on the other side as well. In preparation for this operation, some dissections were made with this problem in mind: Could an approach to the transverse process be found

Digitized by Google

so that, guided by the sense of sight as well as touch, the operator might excise the bone? As a result of these studies a method was devised which was employed in the next operation, which was performed Feb. 2, 1915. A curved incision with its convexity outward was made from the second lumbar to the third sacral spine. The skin flap was reflected inward to the middle line. A muscle flap, consisting of the lower end of the erector spinae group and its aponeurosis, was detached from the crest of the ilium, the posterior surface of the sacrum and from the lumbar spinous processes and reflected upward. This left a fossa having for its walls the crest of the ilium on one side and the spinous processes and laminae on the other; and for its floor the articular processes, and,

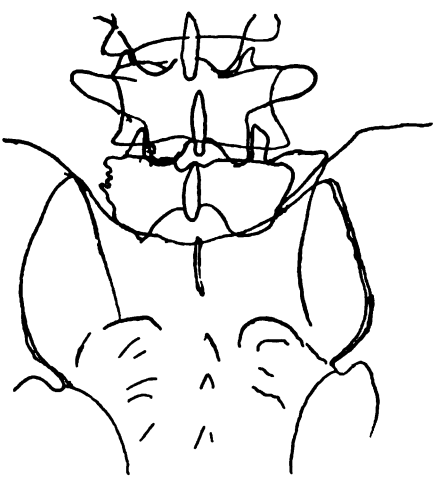

Fig. 4.—Appearance of transverse process of fifth lumbar vertebra in Case 3 after first operation.

at a much deeper level, the transverse processes of the fourth and fifth lumbar vertebrae. The transverse process of the fifth was separated from the vertebra with a chisel. It was found attached to the ilium by a strong fibrous band. As to whether or not anything representing a bursa was present, I am unable to say. The process was separated from the ilium and from the ligaments and from the layer of fat on its ventral surface by blunt dissection. The muscle flap was replaced and its aponeurosis was sutured in place with kangaroo tendon and heavy chromic catgut. The skin flap was replaced and sutured with silkworm-gut. No fixation was applied.

The symptoms following this operation were less severe than those following the first. There was paresthesia but no

Digitized by Google

anesthesia in the lower extremity, and the hospital stay was one week less than before. The convalescence appeared to be quite promising when on February 22, the patient slipped and fell backward, striking the exact center of the field of the second operation against the sharp corner of a heavy chair.

This was followed by severe pain and stiffness in the muscles of the back and an increase of the paresthesia and tenderness in the leg and foot. After a few weeks' rest, massage of the back was employed, which distinctly hastened the disappearance of symptoms both in the back and the leg. This man was last examined May 20, 1915 (almost four months after the last operation); he was just beginning to go without his crutches, and to do gymnastics, which he had found helpful in restoring his strength after his first operation. His greatest complaint at that time was of an intense tenderness and burning in the foot, but especially in the upper surface of the foot and the anterior surface of the leg.

It is to be regretted for many reasons that the question of the relative merits of the two methods of approach has been beclouded by the unfortunate fall which marred what appeared to be an otherwise satisfactory convalescence.

COMMENTS

These three men appear to have obtained, through this operation, permanent relief from lumbar or sciatic pain which had not been relieved by a faithful trial of many other methods.

The difficulties and dangers of this operation are sufficiently great to cause it to be regarded only as a method of last resort.

The chief danger appears to lie in injury to the great nerve trunks, and of these, the trunk containing the fibers which go to the anterior tibial nerve appears to be particularly exposed. Since these fibers are usually traced to the first and second sacral nerve roots the reason for this vulnerability is not obvious.

The question of the mechanism by which the pain associated with these transverse processes is brought about has been the subject of considerable study. The fact that in one of the cases relief followed the removal of the process on the same side as the pain, and in another the removal of the process on the side opposite the pain, makes the theory of simple pressure of the process against the nerve trunk seem hardly

Digitized by Google

adequate. The theory that the process furnishes a point about which, as a fulcrum, an extreme leverage is brought into play when the upper parts of the body start to rock on the lumbosacral joint, seems to me quite plausible. Such a leverage, in an unguarded movement, would strain every joint in its neighborhood including, of course, the sacro-iliac joints. It has been suggested that certain anatomic types are prone to sacro-iliac trouble, and certain other types to lumbosacral trouble. Is it not possible that the unfortunate leverage above described is one very efficient means of straining the sacro-iliac joint? If it be this function of a fulcrum in which inheres the possibility of trouble, it would seem advisable not only to remove the part of the process in actual contact with the ilium, but to amputate the process as near the body of the vertebra as possible. In other words, it is desirable that even in the position of maximum lateral bending the process should be unable to touch the ilium or the top of the sacrum.

At least four methods of approach to this joint have been suggested: the simple incision through the erector spinae muscles, the osteoplastic reflection of a portion of the crest of the ilium, the ventral route, and the muscle-flap method herein described. These three cases simply show that the process can be removed without serious damage by the first method or by the last. It would appear that a certain number of cases will present themselves in which the excision of the transverse process is the proper method of treatment. In view of this fact the question as to the best method of approach is one which is worthy of further study.

1163 Empire Building.

ABSTRACT OF DISCUSSION

Dr. M. S. Henderson, Rochester, Minn.: While these spinal abnormalities are not common, they do occur in the cervical and in the dorsolumbar regions. In the fifth lumbar we frequently see a transverse process which is really an

Digitized by Google

exaggeration of the costal process of the transverse lumbar vertebra. I think in the majority of cases they give no symptoms, but when definite and severe symptoms are present they should be operated on. I have seen probably thirty of these cases and operated on only three. My technic has been a little different from Dr. Fassett's, in that I have not considered it necessary to chip off the entire process, but simply knock off the exaggerated costal element of the transverse process so it would not impinge on the ilium. Whether this is sufficient or not, I cannot say, because my cases have not been numerous enough. One patient did not do very well. One, so far as I know, is cured, and the other is too recent to report as to the definite end-results; I operated on her only two months ago, but her pain has ceased. It is difficult to chip off the process, and I think Dr. Fassett's method of performing the operation is good. None of my patients has had disturbances of the nerve afterward, perhaps because I did not go far enough to remove the entire process. There certainly is a group of cases which should be operated on, but I believe the majority of cases, as in cervical ribs, give no symptoms, and probably should be let alone.

Dr. E. W. Ryerson, Chicago: I have operated on only one of these patients, a woman from South Carolina, who had a very large bifid process. She had undergone two laparotomies on the left side and nothing was found, so that it was pretty evident she had a great deal of pain from this condition. I found the operation unusually difficult, but it was easy to get down to the process by making an incision well to the outer side of the erector spinae muscles. If one goes through the muscles not sufficient room can be gained, and it is not perhaps well to cut through such a large body of muscle; but going just to the outer side of the muscle the access is very easy to the outer part of this transverse process, although it is extremely difficult to get it out. In this operation I only got out the upper half of this bifid process. Nevertheless this patient was much relieved. She had paresthesia for three or four days afterward, but this entirely disappeared. Apparently she is at present free from symptoms. The difficult thing to understand is why removing the top of a bifid process which was not articulating with the ilium, should do any good, but the fact is that it has relieved this patient. We do not know all about the nerve disturbances and nerve supplies, because, as Dr. Fassett said, the supply for the anterior tibial nerve comes from higher up; but the paresthesia my patient complained of was distinctly over the anterior tibial region. I cannot see how these patients can get more relief than by submitting to an operation, because they will not consent to wear through life a long plaster jacket or other apparatus.

Digitized by Google

Dr. Wallace Blanchard, Chicago: I reported at the last meeting of the American Orthopedic Association removal of the transverse process of the fifth lumbar vertebra that impinged on the wing of the ilium. It showed an elongation about twice the normal, as compared with the transverse process of the other side. A perpendicular incision of about 5 inches through the erector spinae muscles and direct down to the transverse process, removing by chisel and forceps, was not an overdifficult operation. The transverse process could be easily reached and removed. After resection the Roentgen ray showed a stump and a space between the stump and the wing of the ilium. There were no bad symptoms following the operation — of anesthesia, hyperthesia, etc., that have been told of by Dr. Fassett, and the patient made a good recovery. The patient had been paralyzed from the shoulder down through the left side to the left leg, and had had two abdominal operations, and the appendix had been removed, all in the hope of relieving painful conditions that were undoubtedly caused by the impingement of the transverse process and the ilium. The cure was immediate and there were no bad symptoms following the operation.

Dr. Roland Meisenbach, Buffalo: In connection with the operation for the removal of the transverse process of the fifth lumbar vertebra, a point that should be emphasized is that great care must be taken so as not unduly to divide nerve structures in the region of the lumbar plexus. I think that operation of these cases should only be undertaken in the severe type, and all other means should first be attempted to relieve the symptoms. There is one case that is of interest, which is rather unique, and which was sent to me for relief. It was a man of good musculature who had been employed at heavy work. At the time of the accident he was holding a rope taut. The rope suddenly parted and he was thrown backward to the ground. He complained of severe pain in the lower part of his back and was taken to the hospital. At the time I saw him, a few months after the accident, he complained of severe pain whenever he turned around in bed or attempted to walk, or on any lateral motion of the body. The radiograph showed that the transverse process of the fifth lumbar vertebra had been obliquely fractured and the fragments separated and displaced, so that the outer portion was drawn downward. A large callus had formed. This callus expanded and amalgamated with the ilium and the sacrum. To give the man relief it was necessary for me to remove the process, which was done. I think in general that a small incision should be made. By a small incision I mean after the first layer of muscles has been divided, and I also think it is much better to divide the muscle fibers with blunt dissectors until one

Digitized by Google

reaches the transverse process. This minimizes the hemorrhage and facilitates the removal of the process. If the periosteal dissector or a chisel is used to peel the periosteum of the process, the chain saw may be brought around and the process removed. I think the use of a chain saw is much better than the use of a chisel, because with the chisel the process is brought out in a piecemeal fashion and there is more danger of injuring the structures. I wish also to emphasize the fact that just anterior to the process one is apt to meet nerve structures and ganglia that should not be touched with the instrument. In one instance I remember that the patient suddenly stopped breathing when these were touched, and I only mention it as a point of interest which should be kept in mind in removing the transverse process of the fifth lumbar vertebra.

Dr. J. P. Lord, Omaha: I wish to report the development of pain on the second day of a recent case. The pain became progressively worse after twenty-four hours. Coming on so late, it occurred to me that it was induced by hemorrhages and infiltration. This might readily be imagined to take place because of the loose tissues in this region, the exudate enveloping these nerve trunks. There was muscle paralysis also, and this lasted for four or five days, when rapid improvement ensued. I would suggest this as a possible explanation of the pain.

Dr. Fred. J. Fassett, Seattle: There is only one thing to add, and that is on the matter of a choice between a chisel and the wire saw. With me it was not a matter of choice at all. I started in equipped with very little except my knife and wire saw, it looked so easy in the roentgenogram. But in none of these cases did I use the wire saw, except when I removed the fourth process. When it comes to the fifth, the passing of the wire saw around the neck of the process required more nerve than even I have developed.

Digitized by Google

LESIONS OF THE LUMBOSACRO-ILIAC REGION

A STUDY OF THE VARIOUS TYPES

HARRY LESLIE LANGNECKER, M.D.
SAN FRANCISCO

In asking your indulgence for a few minutes in the consideration of lesions involving the lumbosacral and the sacro-iliac articulation, I do so because of the importance of recognizing the underlying conditions as early as possible.

In an endeavor to understand the mechanism of the lumbosacral joint, with its many peculiarities, and the too frequently resulting strains to the sacro-iliac joints, it must be remembered that the lumbosacral joint is intimately associated with the sacro-iliac joint function.

Statistics, which I have gathered from my study of occupational or industrial diseases, show lesions of the lower back to be one of the most frequently occurring conditions.

Anatomic variations from the normal structure of the bones of this region are very common. Very often these anomalies do not become evident until excessive or repeated joint strain bring them under observation.

In the study of cases representing the various types, it is impossible to isolate a type as belonging to only one group. For a traumatized joint may later become the seat of an inflammatory process. An abnormal bone formation does cause a lateral curvature. Relaxed ligaments have produced a defective balance of the whole body. With this point in mind, however,

Digitized by Google

namely, the interrelation of the different types, I have grouped these lesions into, first, traumatic, with or without anatomic variations; second, static; and third, toxic.

In the traumatic group are included cases in which injury is the principal factor. These lesions are further classified into, first, acute types, in which the trauma is recent and primary, and second, chronic, in which the trauma is recurrent and of longer duration.

In the acute types the lesion is unilateral, with or without bone displacement. It is the result of direct strain or indirectly through muscular action. In these cases, the sacro-iliac joint receives the entire force of the effort and the bony surfaces of the sacrum or the ilia may slip, or a rupture of the ligaments may occur.

These conditions are demonstrated when bending forward in the act of lifting a heavy object; or in jumping and giving the trunk a sudden twist on the pelvis; or when in swimming and diving, quick hyperextension of the lumbar spine occurs; or during childbirth, when instrumental interference is necessary; or during or following surgical operations with a general anesthesia.

The symptoms depend on the amount of injury rather than on the severity of the cause producing it. Pain usually accompanies the injury. It is sharp and lancinating in character and is increased by all motions. It is present about the affected joint or is referred up the back, over the buttocks, or down the leg. Deformity shows as a forward stoop, a list to one side or flexed leg at hip. Regular tests demonstrate all motions limited. The local signs are obliteration of the lumbar curve, tenderness, or very often, a slight bony prominence over the injured area. The Roentgen ray may show an anatomic variation or a displacement of one of the bones of the lumbosacro-iliac articulations.

Digitized by Google

In the chronic types, because of repeated strains, there is relaxation with occasional displacement. Adhesions are present. The lesion is unilateral although later involvement of the other sacro-iliac joint does take place. Cases vary considerably in character. For example, lesions may result from repeated movement of a broad transverse process of the fifth lumbar vertebra pressing on the ilium until a backward displacement of the sacrum on the opposite side is produced, as in wood chopping; or continual slipping of the flattened articulating processes of the fifth lumbar vertebra, as in automobile repairing; or too often sliding of articulating surfaces of sacrum and ilia on each other, as in marked relaxation of the joint; or subluxation of an intervertebral cartilage, as in repeated displacements of the lumbosacral joint.

The symptoms are intensified with each new strain. Pain may be slight or severe. Irritation of the lumbosacral nerves, after their emanation from the vertebral foramina, gives pain over buttocks, hip and down the leg. This is increased by standing or walking and is less severe after lying down. Deformity may show as a decided forward bending or list to one side with prominence of the hip on the opposite side. The lumbar spine is flattened. In many of these cases the deformity can be corrected, but relapse occurs if sufficient support is not used. Regular tests elicit limitation of motion only in certain directions. Locally, there is considerable tenderness over the affected joint. Referred pain can be started by pressure in this region. There is spasm of the muscles; movement of the joint is guarded and painful. The Roentgen ray usually demonstrates separation or displacement of bones of the joint. Bony anomalies likewise are thus discovered.

In the static group, faulty posture is the most striking feature presented. The muscles and ligaments and therefore the joints of the lumbosacro-iliac region are relaxed. The continual strain on these

Digitized by Google

joints increases the lumbar curve and tilts the top of the pelvis forward. In the variation from the proper poise, the mechanics are disarranged and the physiologic functions of the body are disturbed. This type of lesion is usually bilateral.

A defective posture may result from general debility, which reduces the quality of the muscles and ligaments; or anatomic variations, which may cause a lateral curvature and later a scoliosis; or incorrect clothing, which may compress the trunk or give inadequate support; or lipomatosis or general increase in weight, which increases the strain on the muscles and ligaments of the pelvic girdle; or faulty foot or leg conditions which give unequal base of support; or pregnancy when relaxations of the pelvic joints are very marked; or certain occupations which require fixed positions; or sagging abdominal walls with the accompanying visceroptosis. The long, slender, loose-jointed type of individual, with few exceptions, makes up the greatest number of cases in this group.

The symptoms of the static type are easily recognized. The onset is gradual. The slumped or relaxed attitude in standing is marked. There is a general weakness in walking and standing rapidly causes fatigue. Patients cannot lie comfortably on the back, are restless at night, usually sleep on the side with the thighs flexed. Backache is most constant. Locally, tenderness over all the joints is found. There is always a lordosis, while the posterior back muscles are in a state of spasm. The regular tests show unusual mobility and relaxation of the joint. The Roentgen ray is useful in this group as a method of eliminating the other group types.

In the toxic group are found those types of cases in which the inflammatory element predominates. Continual irritation of the lumbosacral and the sacroiliac articulation, usually with relaxation, produces a chronic congestion in this region and thus infection is easily started.

Digitized by Google

While tuberculous, syphilitic, typhoid and gonorrheal lesions frequently occur in this region, still infection, or toxins, primarily involving the nasal, oral, pharyngeal and gastro-intestinal tracts, produce a pathologic process — an osteo-arthritis — which demands much attention in diagnosis and prognosis. Extension of disease from the pelvis, or following gynecologic procedure, or obscure toxemias resulting from improper metabolism, gradually settle in this region and cause an arthritis.

The symptoms show the onset to be gradual, and secondary to inflammation or toxemia, present elsewhere in the body. When acute, the joints are swollen, the soft tissues are thickened and very tender. The condition is aggravated by standing, sitting or walking. The joints are extremely sensitive to any motion which will induce strain on the pelvic girdle. In the chronic cases, a burning, aching pain is experienced over the sacro-iliac area. Pain, usually dull in character but with sharp paroxysms, may be referred up the back, over the buttocks and hips, and down the posterior aspect of the leg to the heel. Frequently there is disturbance of sensation in the lower extremities. Posture does not relieve the pain. It is in this group of cases that narcotics are resorted to most often to overcome the pain. The deformity causes the patient to hold the lower back stiffly. A marked forward bending or a list to one side is present. There is no lumbar curve, but a prominence of the dorsal spine. The regular tests are usually restricted in every direction. Locally, the flat, rigid lumbar spine, the muscular spasm, the limited area of tenderness and the impossibility of attempted motion are observed. The Roentgen ray usually shows a pathologic process involving some part of the lumbo-sacro-iliac articulation.

In conclusion, I wish to state that differentiation of the various types is not difficult if one bears in mind the fact that in the traumatic group, injury

Digitized by Google

with the sudden onset of symptoms is most important; in the static group, the defective posture with marked relaxation of the joints is present; and in the toxic group, the history of an inflammatory process with the tendency to fixation of the joints is found.

Surgical Division, Leland Stanford Junior University, School of Medicine.

ABSTRACT OF DISCUSSION

Dr. C. C. Crane, San Francisco: While I wish to elaborate somewhat on the anatomic variations to which Dr. Langnecker referred, I also wish to challenge his statement that "Posture does not relieve pain." Radiograms which I have show various mechanical faults which are productive of pain, deformity and disability. I have divided them into three classes. Potential trouble makers, actual trouble makers and proximal trouble makers. The symptoms presented by the patients were various and numerous but all of them were relieved by conservative measures.

Dr. Fred. J. Fassett, Seattle: I think it would not be out of the way to have some one who has the facilities and the clinical material make a routine examination of a large number of normal adults, so that we may form some sort of an estimate as to how many people are going about with large transverse processes and other anatomic variations without any symptoms at all. Of course, it is only the ones with symptoms that come to the physician, and it seems to me that we have a very one-sided view of the subject thus far.

Dr. Leonard W. Ely, San Francisco: In the orthopedic department of Stanford University with a complete outfit and all the facilities to work with, we are entirely at sea on this subject of lumbo-sacro-iliac lesions. I have become discouraged trying to replace these so-called slipped joints —in trying to get the painful ones relieved—and we are ready and eager to put all the facilities that we have at the disposal of anybody who will undertake to help us clear this matter up. I have become discouraged, but a ray of hope, I may say, has broken on me from what Dr. Langnecker has said.

Dr. J. T. Rugh, Philadelphia: In regard to Dr. Fassett's request, I had one of the leading roentgenologists in Philadelphia for the past six months make a study of the cases which came under his care for all abdominal conditions. He has told me, after looking over a series of probably four or five hundred of these cases, that he finds some anomalies in this part of the spine in a very large percentage

Digitized by Google

of the cases. In fact he is coming to look on it as rather unusual to find the normal.

Dr. John Ridlon, Chicago: I should like to ask that in closing, Dr. Langnecker say whether in any of these strained or slipped joints—sacro-iliac or lumbosacral region—he has had anything in the nature of atrophy of the limb develop on the painful side.

Dr. C. R. McClure, Portland, Ore.: At present through the courtesy of Dr. Coffey's office in Portland we are having observations made on this region of the lower back, and I hope at some future meeting to make some reports concerning our study of this region. We see a great many of these cases, and, like many of the men here, I sometimes doubt the value of the Roentgen ray in a diagnostic way because of the frequency with which these anomalies are found in people who have no symptoms one way or the other.

Dr. Roland Meisenbach, Buffalo, N. Y.: That the pelvic joints, especially the sacro-iliac and sacrolumbar, are so frequently involved in the sciaticas and the backaches which are met with, can no longer be doubted. The results of the treatment for these conditions, with the relief given the patient, have spoken for themselves. I believe that the most important matter for our consideration in diagnosis is to differentiate between the sacro-iliac and the sacrolumbar lesions. It is true that in some we have both these joints involved; it must also be remembered that occasionally we may have backache due to the strain or injury to the sacrolumbar joint in a person who may have other conditions present; as, for instance, a very heavy person with leukemia may sustain an injury to the sacrolumbar joint due to the actual weight of the abdomen, and in relieving the strain we are naturally relieving but one of the symptoms. Another type of sacro-iliac and sacrolumbar lesion which is more frequently met with is one of trauma, in which there also exists pelvic inflammation, or glandular inflammation, which has attacked the pelvic joints or has weakened them so that they are subject to trauma. One has only to remember his anatomy and note the variations in the sacrolumbar joint, both as regards the articular processes and also the variations in the transverse process in different individuals. I have met many times a type of sacrolumbar lesion in which the patient has had recurrent backache, which I am sure has been due to a very shallow sacrolumbar articulation. In this type it has been sometimes difficult to illustrate the condition by means of a roentgenogram. In regard to the roentgenogram, I cannot agree with Dr. Langnecker. If he had used the word "occasionally" instead of "usually," I think it would have been more to the point. In cases with a long or thickened trans-

Digitized by Google

verse process of the fifth lumbar vertebra, which may or may not articulate with the sacrum or ilium, or in cases in which the sacro-iliac joint has opened and the sacrum has dropped or tilted, it is not very difficult to illustrate by means of the roentgenogram; but those cases (and they are frequently met with) in which the sudden movement of the body may quickly incapacitate the individual, causing such a severe pain that the person is unable to take another step, are rather difficult to illustrate by means of the roentgenogram. I believe this type of case to be that of the shallow sacrolumbar joint, in which the joint articulations are of such construction that they easily become dislodged. Many of these do not seek relief at the first attack, but usually after having rested or having had several attacks. Also in the type of loose sacrum it is difficult to demonstrate by means of the roentgenogram; that is, the single flat plate will show nothing, but the stereoscopic roentgenogram will often show the sacrum slightly tilted. Dr. Langnecker has covered the ground of symptoms very well. One of the best illustrations of the severe sciatica which was caused by motion in the sacro-iliac joint is that of metastatic carcinoma of the sacrum following, as in the case I have presented, a removal of the breast for carcinoma. In this case, the slightest motion of the ilium on the side in which the sacro-iliac joint is involved causes a severe sciatica.

Dr. C. L. Lowman, Los Angeles: We have a skeleton which shows an anomaly of the first sacral—just a small lateral process on one side, like a lumbar vertebra, the full length and width of ala on the opposite side, with a joint between it and the second sacral; an absolutely flat articular process on the right side, and a vertical process on the other. This allowed a great deal of rotation of the sacrolumbar segment forward around this vertical process as an axis, with a narrowing of the posterior foramina. Another similar case was presented to me by my radiographer. This case was treated by a chiropractor as a tuberculous spine. The roentgenogram showed an assimilation of the first sacral, which tried to be a lumbar on one side.

Dr. H. L. Langnecker, San Francisco: In reply to Dr. Ridlon's question, I would say that in a great number of cases, especially those of the lumbosacral region, there seems to be an atrophy of the muscles of the anterior part of the thigh, the atrophy of the other muscles having been consistently noted.

Dr. John Ridlon, Chicago: By measurement?

Dr. H. L. Langnecker: Yes, by measurement. It is one of the signs. These conditions are usually studied by stereoscopic roentgenograms; all the important ones were

Digitized by Google

in my cases. I found that the study of this class of cases was extremely interesting. There is much, as yet, to be said about them. I can only repeat what one of the orthopedic surgeons—a man who has done more, probably, on lesions in the sacro-iliac region than anybody else in the country—told me. He said that there was a great deal yet to be known about lesions in this part of the body, and that he thought when the final verdict was given it would be an anatomic one.

Digitized by Google

OPERATIVE TREATMENT OF BUNIONS

BY THE MAYO METHOD

MELVIN S. HENDERSON, M.D.
ROCHESTER, MINN.

DEFINITION

The bunion is a painful bursitis superimposed on a hallux valgus. The degree of hallux valgus is by no means a criterion of the severity of the bunion (Fig. 1). The Mayo operation for bunion is for the relief of the painful bursitis and not a cosmetic operation for doing away with the deformity of the hallux valgus, though incidentally the deformity is reduced. For many years the operation[1] about to be described has been used in the Mayo Clinic and has given such satisfactory results that I think it wise to further emphasize its usefulness.

ANATOMY

Briefly we may consider the anatomic findings in this deformity. It is not seen in children who have never worn stiff shoes nor is it noted in individuals who have always gone barefoot. In these normal feet the great toe is in line with or turns slightly inward from the inner border of the foot. It has been stated that in the bunion foot the great toe is the longest, whereas the second toe should be of the same length or even a little longer. While this is not invariably true, still in this type of foot, that is, with the great toe the longest, the deformity is often present. In hallux valgus a line drawn through the anteroposterior axis of the great toe courses anteriorly outward at

1. Mayo, C. H.: The Surgical Treatment of Bunion, Ann. Surg., 1908, xlviii, 300.

Digitized by Google

an angle of 30 degrees or more. The condition has generally been caused by wearing too short a shoe and this information is many times voluntarily given by the patient. The tendon of the extensor proprius hallucis becomes displaced outward and further increases the deformity. The pressure and irritation of the shoe causes more or less of a chafing action on the skin over the prominent inner aspect of the head of the first metatarsal bone. This irritation in many cases causes a distinct hypertrophy of the end of the bone and small bony exostoses occasionally form. Nature comes to the rescue with the formation of a bursa and we then have a bunion. It is only when this bursa becomes inflamed, mechanically or by infections, that tenderness results and surgery is indicated. Many cases go on to sepsis. When this occurs, operation should not be undertaken until the infection has completely subsided. Complete rest and alcohol dressings usually promptly clear up the infection. On top of the bursa may come a corn, adding further to the distress and inconvenience of the patient. Thus it may be stated that the symptoms depend not on the deformity but on the inflammatory changes in the bursal sac causing oftentimes continual discomfort and pain. The proximal phalanx of the first toe articulates often only against part of the head of the first metatarsal, the inner portion of the head impinging against the skin of the inner side of the foot. Often in patients in middle life or beyond, rarely in the young, there is an associated arthritis with deposits. These patients do not obtain the great relief accorded the nonarthritic cases. They should not on this account be denied the benefits of the operation, since formation of the new joint is a great relief.

All cases of hallux valgus do not cause inconvenience and many cases of moderate bunion had better not be interfered with surgically. Too often the cases are passed over lightly by the surgeon when the complaint is really a serious and disabling one to the patient and

Digitized by Google

Fig. 1.—Moderate hallux valgus with painful bunion.

Digitized by Google

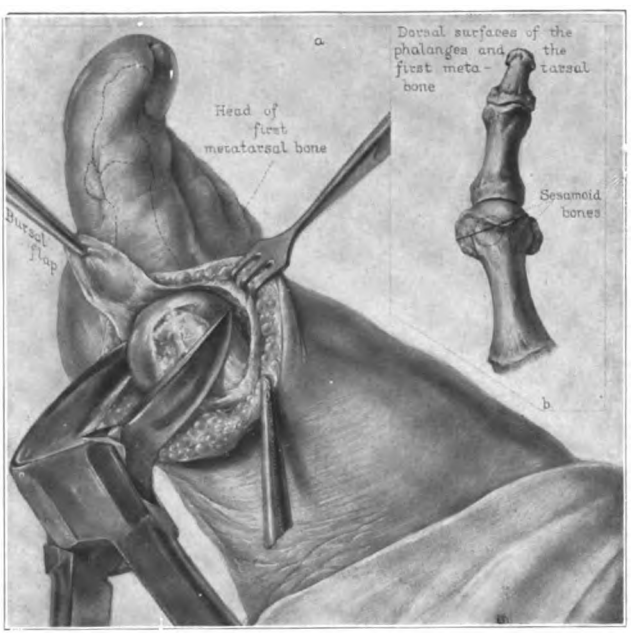

Fig. 2.—*a*, Removal of head of first metatarsal bone. Bursal flap dissected free; *b*, angle at which head of metatarsal is removed, showing short incision at right angles to long incision. The short incision removes the hypertrophy of the bone.

Digitized by Google

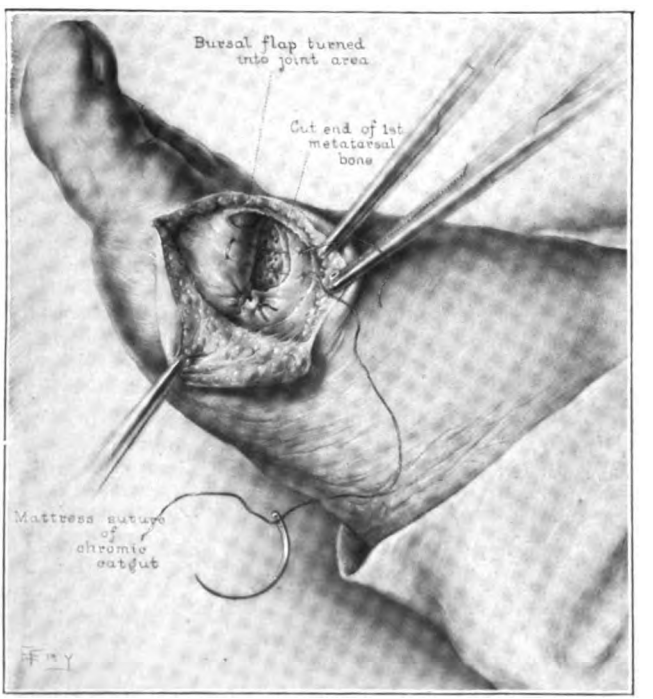

Fig. 3.—Head of bone removed. Bursal flap tucked in and approximated to periosteum of first metatarsal by two mattress sutures of chromic catgut.

Digitized by Google

Fig. 4.—Greater part of metatarsal head removed, leaving sufficient of the expansion for weight-bearing.

Digitized by Google

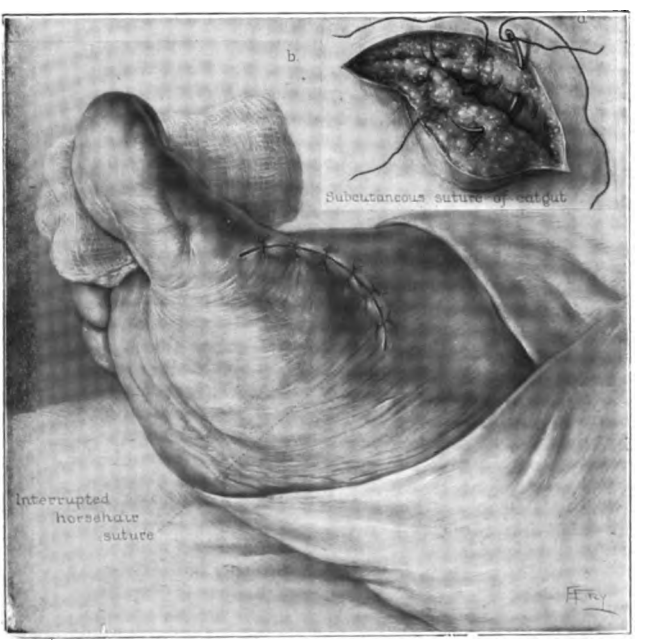

Fig. 5.—*a*, subcutaneous tissue sutured with interrupted catgut sutures; *b*, location of scar where shoe will not press on it. A pad of gauze is placed between the first and second toes to maintain the correct position of the great toe.

Digitized by Google

Digitized by Google

demands surgical interference. Bunion has long been looked on as a trifling condition, but to the individual with the pain it is anything but trifling.

OPERATIONS

Heuter[2] advised excision of the head of the first metatarsal bone for the relief of the condition. Hamilton[3] later reported eleven cases and his name is often mentioned in connection with the operation. Schede[4] advised excision of the bursa and removal of part of the head of the first metatarsal not in contact with the phalanx. Barker and Reverdin advised removal of the exostoses and of a wedge of the metatarsal just above the head. Various other operations have been suggested, such as removal of part of the proximal phalanx and part of the head of the metatarsal. It has been suggested that the head of the metatarsal bone be removed by an incision between the great and second toes, thus doing away with an incision on the inner side of the foot. The objection to an incision on the inner part of the foot we have found to be theoretic rather than real. By making a curved elliptical incision with the curve upward, it can be so arranged that the pressure of the shoe comes below and not on the line of incision. The operation has been performed in our clinic in 148 cases, nearly all of them double, with, on the whole, most gratifying results.

Many patients have the condition associated with hammer toe, callosities on the bottom of the feet, etc., and unless it is carefully explained beforehand to the patients what they may expect from the operation, they may be disappointed that they are not relieved of all their foot trouble. However, in cases carefully selected, the results have been most excellent. Great

2. Heuter: Quoted by Holmes, T., in System of Surgery, Philadelphia, Henry C. Lea's Son & Co., 1882, iii, 372.
3. Hamilton: Quoted by Holmes, T., in System of Surgery, Philadelphia, Henry C. Lea's Son & Co., 1882, iii, 372.
4. Schede: Quoted by von Bergmann, von Bruns, and von Mikulicz in A System of Practical Surgery, Philadelphia, Lea & Febiger, 1904, iii, 854.

Digitized by Google

care must be exercised in patients with flat feet to see that too much of the head is not excised. At the same time, enough must be excised to relieve the condition.

TECHNIC

The actual technic of the operation may be briefly stated: A semilunar incision with the curve upward is made at the metatarsal phalangeal joint of the great toe. The skin is dissected back, being careful not to puncture it. A flap including the bursa is then taken with its base attached to the proximal phalanx, having its convexity extending on to the head of the first metatarsal (Fig. 2a). The fat is then pushed back from around the head of the bone and a large bone-biter is introduced from without inward, aiming to take off most of the articulating surface of the head of the metatarsal bone, leaving sufficient of the enlarged end to serve as a weight-bearing portion (Fig. 3). This bone-biter is introduced at an angle of about 75 degrees so that the outer side of the metatarsal bone is a little longer than the inner side after the piece is removed (Fig. 4). With a rongeur bone-biter the prominence left on the inner side is smoothed down (Fig. 2b). The flap is then tucked in and the base of the flap sewed to the periosteum of the first metatarsal by two mattress sutures of chromic catgut (Fig. 3). This serves to straighten the toe and put it in its proper line. The skin is then closed with one or two sutures of silkworm gut and closer approximation is secured by interrupted horsehair sutures. A pad of gauze is inserted between the great and second toes to straighten the great toe (Fig. 5). A dressing soaked with alcohol is applied and carefully bandaged.

AFTER-CARE

No splints are necessary. Pressure of the bed clothes is removed by the use of half barrel-hoops. Twice daily the bandage is opened enough at the end of the great toe to allow pouring in of alcohol, thus soak-

Digitized by Google

ing the dressing and adding greatly to the comfort of the patient. Stitches are removed in a week, weight-bearing permitted in ten days and the patient encouraged to use the feet as soon as possible. A small pad of gauze or cotton is to be worn between the first and second toes for a few weeks. The wearing of shoes with a proper straight inner side is insisted on. All patients will not follow this advice, but by carefully explaining why it is to be desired, the responsibility is then placed on them.

ABSTRACT OF DISCUSSION

Dr. E. W. Ryerson, Chicago: It is a rather difficult thing for me tactfully to say what I think about the Mayo operation, because I do not think it should often be done, unless it is impossible to bring the end of the first metatarsal bone and the phalanges of the toe into a straight line without undue force. It is undoubtedly true that a great many people have the wrong view of the Mayo operation. I have myself operated under the idea that it consisted in removing the entire head of the first metatarsal bone. That should never be done. It disturbs the balance of the foot so markedly, that people who have had the entire end of the first metatarsal removed are always more or less incapacitated. I have seen some thirty patients, about twenty of whom were operated on by me, and the others were operated on by other men, all of whom have had trouble after the Mayo operation. It is true that the bunion undoubtedly was cured, but they had a painful static disturbance of the foot and a severe type of flatfoot in all of these cases. Now what should be done? In many cases it is a fact that there is no bursa whatever, and in many other cases it is true that the bursa is small. There can be a much irritated skin without a bursa, and with the presence of a rather large—not always enlarged—metatarsal head, the divergence of the big toe outward, of course, allows the pressure of the shoe to come against the end of the metatarsal. The thing to do —and I have done it a great many times with a great deal of satisfaction—is to make exactly the same kind of an incision that Dr. Henderson and Dr. Mayo use; to push the toe down where it will be out of the way; to take a very sharp chisel and start it at the front of the inner side of the metatarsal bone which is just where the edge of the phalanx comes, and cut backward, chiseling off the projecting portion of the bone. We can remove a piece an inch long, or even more, if necessary, down along the shaft of the bone, the portion of which is making the trouble,

Digitized by Google

and it is extremely important to shave down the shaft of the bone just as carefully as one possibly can, so as to leave no little spicules of bone sticking out and no little shreds of periosteum, and make the whole of the bone smooth and practically cylindrical. Do not disturb the rest of the articular surfaces unless you have to. We all know that in extreme cases the big toe is pushed way out of line, and it cannot be brought anywhere near straight without removing some of the articular surface, and in such cases Dr. Mayo's operation is excellent and has proved its use, as emphasized by the speaker; but the inner side of the bone should be trimmed off very carefully. That is the main thing. It is the inner side of the bone that makes the trouble. It is also wise in many cases to excise the thickened skin as well, but this is not always necessary. One must always suture the skin very accurately and it is well to twist bleeding vessels instead of ligating them. It is my personal opinion that you should avoid the Mayo operation in every case you possibly can.

Dr. John Ridlon, Chicago: To emphasize the difference of opinion among men working side by side in the same town, I wish to say that I agree with Dr. Ryerson only in one statement; that is, that the Mayo operation should always be avoided. Further than that, I would want to say that I think the Mayo operation a much better operation than the one described to you by Dr. Ryerson. I believe that the success of an operation on a big toe with a bunion or hallux valgus, in order to secure a useful, strong, mobile and painless joint, lies in the taking away of a lot of bone. I remove all of the head, and then some, and all of the knobs, and I am particularly careful to remove any knobs on the plantar surface of the foot.

Dr. J. P. Lord, Omaha: I have performed the Mayo operation since it was first described by Dr. Charles Mayo, and I have undertaken to follow the technic as originally outlined by him, and that technic does not recommend the removal of the whole of the head of the bone—but about three fifths, as I remember it, of the articular enlargement—then the thorough removal of the projecting bone on the inner side, and the following of all of the details. It has never brought me anything but the most complete satisfaction. I think that if too much bone is not removed, the objection raised by Dr. Ryerson, that it is conducive to flatfoot, is not borne out, at least by my experience, and I simply wish to put myself on the side favoring the Mayo operation as being the best procedure for the condition described.

Dr. Leonard W. Ely, San Francisco: There is one point in Dr. Henderson's paper to which I should like to take

Digitized by Google

exception, namely, the causation of a bunion. The simplest things, when we come to examine them, we find are not simple at all. I always assumed that a bunion was caused by short shoes, but people who wear short shoes are not always those who have bunions, and many people who have worn broad shoes and long shoes all their lives have bunions. Young of Philadelphia discovered one cause in a bone which pried the first and second metatarsals apart. Some German observer maintains that a bunion is really not a hallux valgus but a hallux varus, caused by a varus position of the metatarsal bone. He ascribes the ultimate cause of it to an obliquity of the articulation of the metatarsal with the tarsus. That looked extremely probable, and I assembled a great many roentgenograms with the idea of finding out if it was so. It is not, as far as I can make out. It seems to me that our knowledge of this subject will be quickened if we will not assume a cause, but will try to find out the real cause of the deformity, and possibly improve our treatment on that basis. The insertion of a bursa I have never found necessary. I agree with Dr. Ryerson that if one takes off as much bone as is necessary at the end of the metatarsal, one will get a fairly movable joint.

Dr. J. T. Rugh, Philadelphia: I just want to call attention to one little point which I usually have followed in this operation, though the conditions that are present in the individual case should determine the type of the operation. It does not appeal to me to be the best surgery to make the base of the flap anteriorly. The vitality of the flap, I feel, would be endangered. I always make my flap with the base of it posteriorly along the side of the metatarsal to guard against sloughing.

Dr. B. M. J. Conlin, Long Beach, Calif.: Bunions are not caused by either short or tight shoes. After a careful study of bunions for over forty years I have come to the conclusion that they are hereditary. The natives of the Sandwich Islands and the Indians of Mexico, who never wear shoes, have bunions; and the people wearing short, tight, ill-fitting shoes do not have bunions, unless they inherit them. The bunion in the human species is analogous to the ringbone in the horse, and the breeders of thoroughbred horses have demonstrated beyond a doubt that ringbone is transmitted from parent to offspring.

Dr. E. A. Rich, Tacoma, Wash.: In general considerations with regard to feet afflicted with bunions, two facts seem to stand out most prominently; first, a varying degree of flatfoot is constantly present, and second, this flatfoot usually is not of the painful variety. I have in mind cases that present with so marked a degree of flatfoot that the

Digitized by Google

bunion deformity would seem insignificant, yet the bunion is the only part of the foot that causes pain. This fact further illustrates some points recently brought out in the controversy in the columns of THE JOURNAL over flat feet, namely, that the degree of flatfoot cannot be gaged by the symptoms. It is my conviction that the flatfoot condition in operative bunion cases does not need treatment and end results will be better if no attempt is made to correct the arch deformity.

We have been doing our own operation on bunions, which is a little more extensive than that of the Mayos. We have taken out more bone. Often the head of the metatarsal has to come out, but usually part of the articulating surface of the joint can be saved. Instead of using the bone clippers we prefer a sharp chisel that will directly cleave the bone and not crush it. We believe that there is less cause for regret when too much bone is removed than when too little is taken away.

DR. JOHN F. GOLDEN, Chicago: Most of the bunions that have come to me for the last eight years have been operated on according to the method of Dr. Henderson. It occurred to me during the discussion that probably the bunions came earlier to the man in orthopedics and later to the man in general surgery. The bunions that we get are large ones, and usually the foot is markedly flat. In those cases I have acted according to Dr. Henderson's procedure, waiting as long as possible and removing as little as possible, and the results have been very good. I might ask Dr. Henderson in closing this discussion to mention the formation of hematomas, which frequently ensues. We aspirate them about the third day, and we don't touch them with our fingers or with the sutures. Everything is handled with metal; not even touched with gloves. We use ligatures practically not at all, and if hematoma results we simply aspirate that hematoma at the end of the second or third day. I saw Dr. Smith do an operation on a number of stiff fingers, and I noted the analogy between the technic he used and that which is followed by Dr. Henderson in the case of flat feet.

DR. M. S. HENDERSON, Rochester, Minn.: I can say that I am just as positive that this method is the best as Dr. Ryerson is that it is not, because I believe the whole thing to hinge on the fact, which I probably did not emphasize in the paper, that the bunion foot is a particular type of foot. The great toe is usually the longest, and it should not be the longest, or at least should not be any longer than the second toe. Now that is not an invariable rule, but in a large majority of cases it is true, and I do not think we can put aside the fact that short shoes produce bunions. They do not always produce them, but they help, and I do not believe a bunion can be cured by the operation Dr.

Digitized by Google

Ryerson describes. Some of the head of the bone—the articular surface—must be taken off to shorten the great toe. Of course, these people come to us in all conditions and the severe type cannot be absolutely cured. They will always have some trouble and we always tell them so, but we can relieve them greatly. Many cases can be cured by proper shoes and care of the feet, and on these we do not operate. Dr. Golden mentions hematoma. I think he is quite right. Unless one is very careful, hematoma forms; this should be aspirated about the second day. Dr. Rugh mentions the type of flap. I have tried all kinds of flaps—from the phalanx with the base backwards, with the base below, and I am of the opinion that the flap in front with the base toward the phalanx is the best. I do not believe that it becomes necrotic; at least, I have had no evidence to point that way.

Digitized by Google

ANTEVERSION OF THE NECK OF THE FEMUR

IN CONNECTION WITH CONGENITAL DISLOCATION OF THE HIP *

RUSSELL A. HIBBS, M.D.
NEW YORK

A careful study of my failures in the treatment of congenital dislocation of the hip has convinced me that some of those failures were due to anteversion deformity of the head and neck of the femur which was not recognized before operation.

A certain number of those cases have since been treated with complete success by the method to be described.

Anteversion of the head and neck of the femur has of course been recognized, but the frequency of its occurrence has not been appreciated, at least by me, nor its influence on the final result in the treatment of congenital dislocation of the hip. Much more consideration has been given to defects in the acetabulum, and without doubt the acetabulum is more or less defective perhaps in all cases, and in some, to such a degree as to prevent cure. I believe, however, that this deformity of the femur is more often the cause of failure to secure ideal results. No case of congenital dislocation can be considered absolutely cured until the head is wholly in the acetabulum and the gait of the patient and function of the joint normal. It does not seem possible to me to obtain such a result when this deformity exists to any considerable degree.

There is a certain amount of anteversion in the normal femur, but probably not more than from 10 to

* From the Service of the New York Orthopaedic Hospital.

Digitized by Google

Fig. 1.—An osteotomy of the femur at its lower third for the correction of anteversion of neck. Bone at left shows anteverted head; in center, lower fragment twisted out correcting deformity; at right, deformity corrected, normal bone.

Digitized by Google

Fig. 2.—Congenital dislocation of hip with anteverted head and neck of femur.

Digitized by Google

Fig. 3.—After osteotomy; deformity corrected.

Digitized by Google

Fig. 4.—After reduction of dislocation; normal hip.

Digitized by Google

Fig. 5.—In plaster after osteotomy.

Digitized by Google

Digitized by Google

15 degrees. Dr. Durham, one of my staff at the Orthopaedic Hospital, recently made a study of 200 normal femora, and found that the average amount of anteversion was 11 degrees. More than this amount is abnormal, and certainly when it is as much as from 75 to 90 degrees, grossly so. With the leg straight and the toe and patella pointing forward in the normal direction, the head of the femur cannot be completely in the acetabulum. With the head thus partially engaged in the socket, weight bearing is uncertain and there is always a limp.

The question as to where the deformity takes place is an important one. It seems probable that it is due to a twist in the shaft of the femur, because by Roentgen-ray study there is found no appreciable change in the relation of the head and neck to the two trochanters, as would be the case if the deformity were due to any change there.

Two roentgenograms in a given case will demonstrate this conclusively, the first taken in the usual position with the patella and toe pointing forward, the second with the femur in internal rotation, the patella and toe pointing inward. A comparison of the two plates will show that a perfectly normal head and neck exist in a normal relation to the two trochanters and indicate that the deformity is in the shaft of the bone.

It would seem logical, therefore, to treat the matter as a twist of the shaft of the femur, and correct it by osteotomy before any attempt is made to reduce the dislocation. That is what has been done in a series of twenty-nine hips in twenty-six children at the Orthopaedic Hospital, all the earlier patients having been previously operated on for dislocation once and in some instances twice, with failure. The first three cases were shown before the orthopedic section of the New York Academy of Medicine, April 18, 1913.

No attempt has been made recently to reduce the dislocation until this deformity is corrected. It is

Digitized by Google

done by an osteotomy at the lower third of the femur. After the bone is divided, the lower fragment is twisted outward to the degree that the head is abnormally anteverted. After the bone unites, the patient is allowed to walk from eight to ten weeks until the external rotation of the leg is corrected by exercises and it takes the normal position in walking, the patella and toe pointing forward. At this point in the treatment the dislocation should be reduced.

The lower third of the bone is selected for operation for two reasons; first, because at this point there is the least interference with muscle attachments, and second, because both fragments are long enough to give perfect control of them. Both of these are important considerations in the accurate correction of the deformity and the preservation of the function of the muscles.

Figure 1 is a photograph of a femur on which the operation has been done.

A. E., girl, aged 5 years, had congenital dislocation of the left hip with 1½ inches shortening and an anteversion of head and neck of femur of 85 degrees. Two unsuccessful operations had been done for the dislocation, the deformity not having been recognized.

February 14, 1913, osteotomy of the femur was done and the deformity corrected by external rotation of the lower fragment; a plaster spica was applied. At the end of six weeks the plaster was removed, walking permitted and exercises begun.

May 17, 1913, external rotation was entirely corrected. The dislocation was reduced. Plaster was applied, changed at intervals of three weeks, and removed at the end of two months. Result, May, 1915: head of the femur in the acetabulum, limbs equal, joint function perfect, patient walks without limp.

The roentgenograms taken in this case are shown in Figures 2, 3 and 4. Fig. 2, in the ordinary position, toe and patella pointing forward; Fig. 3, after osteotomy and taken in the usual position, toe and patella pointing forward showing deformity corrected, and Fig. 4 showing head in the socket, a normal hip.

Digitized by Google

It does not seem necessary to report in detail more than this one case, as in every essential the procedure was the same in all of them, except the younger cases wore plaster after the hip was reduced for a longer period, three to four months.

It is important, however, to emphasize the need of great care in correcting the deformity after osteotomy. In two of my earlier cases the lower fragment of the bone was not rotated enough to entirely correct it. Figure 5 is a photograph of such a patient in plaster after operation. When this deformity exists in both hips, it is corrected in the two at the same time.

The operation for the dislocation in all of these cases has been done by the method previously described by me[1] and with the aid of the table designed for that purpose.

1. Hibbs, R. A.: An Original Method of Operating for Congenital Dislocation of the Hip, New York Med. Jour., April 25, 1908.

Digitized by Google

CONGENITAL DISLOCATION OF THE HIP

REDUCED BY MANIPULATION FOLLOWED BY ARTHROTOMY

JAMES T. WATKINS, M.D.
SAN FRANCISCO

There has been considerable speculation as to what actually occurred when a congenital dislocation of the hip was reduced by the mechanical method. So far as my reading goes, no one has reported any attempt to determine by operative procedure whether the femoral head became directly applied to the acetabulum or remained separated from it by a fold of capsule. This paper records an attempt to solve this question.

My clinical experience with congenital dislocations of the hip has been sufficiently extensive. On the other hand, my opportunities to observe in detail pathologic anatomy have been meager.

Two specimens were seen at the clinic of the late Professor Hoffa; one was shown me by M. Redard; Dr. Bradford demonstrated for me, if I remember aright, three specimens from the Warren museum, and I made a necropsy on one several years ago for Dr. Sherman (a baby that had died of the measles).

Observing these, I had been able to verify what is common knowledge today of this condition, but found myself in much perplexity as to the changes brought about in the mutual relations of femoral head, capsule and acetabulum by the manipulative or mechanical reduction.

In the Hoffa specimens I noted a demifacet in the anterior rim of the acetabular roof. I regarded this as evidence in support of Lange's contention that the

Digitized by Google

femoral head originally left the acetabulum by the anterior route. I noted also that the specimens from older children presented a ligamentum teres drawn out to the thinness of a thread, when it was not actually absent. It will be recalled that M. Redard, in discussing personal statistics of one thousand cases, calls attention to late-appearing deformations of the femoral head and neck in cases in which operation had been successfully performed by the mechanical method.

I felt that it would not be unreasonable to attribute this late-appearing distortion to defects of nutrition consequent on the occlusion of the artery in the ligamentum teres. I was unable to explain, however, the roughness which he and we here have noted in the floor of the acetabulum in certain of these cases. Possibly it is due to modified statics consequent on the changed shape of the femoral head.

The hour glass constriction of the capsule was apparent in all cases in which the patient had walked, as was the forward twist of head and neck on the shaft.

One noted, too, that frequently there was a slight bowing of the neck with the concavity looking forward.

The changes in the muscles, the shortening of adductors and hamstrings, I had demonstrated clinically, but the lengthening of pelvitrochanterics, to which Lorenz had called attention, was not apparent, and until just recently did not seem particularly significant.

So much for a hasty review of the anatomy.

In 1903 I had assisted Dr. Sherman in operating on a patient on whom Professor Lorenz had previously performed a manipulative reduction. In this case it was found that the femoral head had ruptured the capsule and come to lie among the adductors of the thigh.

I pause to observe that I really believe Lorenz deliberately tried for an antero-internal transposition,

Digitized by Google

because I can recall his first assistant Scholl telling us once in particular, after a mishap in which the patient went into sudden shock and there was reason to believe that one of the great vessels had been ruptured, that these accidents would not happen if the professor would content himself with a simple reduction and not try to displace the head internal to the acetabulum.

I believe that, at that time at least, Lorenz attributed the permanent stability of his reduction to the tension of his pelvitrochanterics, and that he attempted, therefore, by the maneuver described, to bring their origins and insertions nearest together during the period of immobilization. He also laid great stress on the stretching of the anterior capsule, though it is probable that he did not contemplate the rupture and escape of the head which actually occurred.

Again, Lange demonstrated by means of a series of roentgenograms, of which I had tracings, but which were lost in the great fire of 1906, that except where an exceptionally long neck was present, the so-called "frog position" was apt to put, not the femoral head, but the greater trochanter into or on the acetabulum. Both he and Hoffa, who at that time was doing the open operation exclusively, immobilized in moderate abduction, full extension and internal rotation.

When I discussed this with Lorenz, he assured me that he had nothing to say against internal rotation provided one employed external rotation first.

The late Professor Panzeri of Milan employed abduction and an exaggerated internal rotation with knee flexed.

These were the observations, for the most part undigested, which I brought back from Europe with me. In view of them, first, and in view of the fact, secondly, that when I made the necropsy on Dr. Sherman's measles patient I did not think it mechanically possible to put the head by manipulation into the socket, and thirdly, because I found the capsular constriction exceedingly resistant even to a very sharp

Digitized by Google

knife. I became convinced that it was not possible by manipulation to place the head in the acetabulum, cartilage to cartilage; and in this idea I remained for several years.

Last year I came across Dr. Ridlon's description of his technic. It sounded so easy that I thought I would try it as a preliminary to arthotomy.

My opportunity came October 31 of last year, when I performed a manipulative reduction on a muscular little boy of 6 years and 3 months.

Without any great difficulty the head appeared to me to enter on rather than into the socket. My associate, however, was very sure that it was only on the posterior rim of the acetabulum.

Therefore, pending the test of the Roentgen ray, we immobilized the limb in abduction extension and internal rotation.

Then the little boy got sick and stayed sick, so that it was not until Jan. 30, 1915, that he came to the second operation.

Permit me here to interpolate from the clinical records my notes of Dec. 30, 1914, as well as those made at time of operation.

Stereoscopic views were taken in two positions yesterday: (1) with thigh in the position in which it had been held in plaster of paris, that is, in very marked abduction and inward rotation; (2) with thigh in diminished abduction and patella looking forward. It was agreed by all who studied the plates, Dr. Birtsch, Dr. McChesney and myself, that the head of the affected thigh was at the level of the acetabulum, and that the circle represented by the outline of the head and the circle of which the acetabulum formed an arc were concentric, but that the femoral head lay in a plane anterior to the acetabulum.

Physical examination gave a resistance beneath the femoral artery, but no undue fulness beneath Poupart's ligament, such as we see in frank anterior transpositions. There was no shortening; a false acetabulum was apparent above the site of the true one. The latter appeared to have a fair "roof."

January 30, 1915, under the strictest aseptic precautions the usual longitudinal incision between the tensor fasciae and sartorius was made, and the capsule opened. The capsule

Digitized by Google

appeared to be adherent to the anterior aspect of the neck up to the junction of bone and cartilage. The head was in the acetabulum, from which it was easily luxated. Sinovialis about head and capsule not adherent. No fold of capsule in front of head as latter had entered acetabulum. Ligamentum teres gone. Considerable fat in floor of acetabulum. Anteversion of head and neck not marked. Stability after reduction of dislocation excellent. Wound closed in usual way and immobilized in abduction and internal rotation.

June 14, 1915, cast off, stability good, walks with a sway but without a limp. To come back in December for inspection.

Subsequently a little girl, aged 4, appeared in my wards who had presented a bilateral congenital dislocation of the hip. These, however, had been the subject of attempts at mechanical reduction at another institution.

Here the stereoscopic pictures as well as the clinical findings seemed to show the right side in anterior transposition and on the left a frank reluxation.

An arthrotomy was therefore done on each side, using the anterior incision. On the left side reposition was easy, nor could one draw any conclusions as to the success or failure of the previous manipulation. On the right side the head was not out. In fact, because of the shrinkage which the pelvitrochanterics had undergone, it was only with difficulty dislocated. On the other hand, the dilatation of the anterior capsule had been so complete that the joint would appear to have lost the feature which kept the head pressed back into the socket when the limb went into hyperextension.

You will recall that the center of gravity of the body falls in a plane behind that in which lie the femoral heads. Therefore, in such a case during the maintenance of the erect posture, the head must be tilted forward, and sooner or later acquire a subspinous position.

Though not germane to this subject, I interpolate here that this child suffered a secondary hemorrhage on the left side two days after the operation. In

Digitized by Google

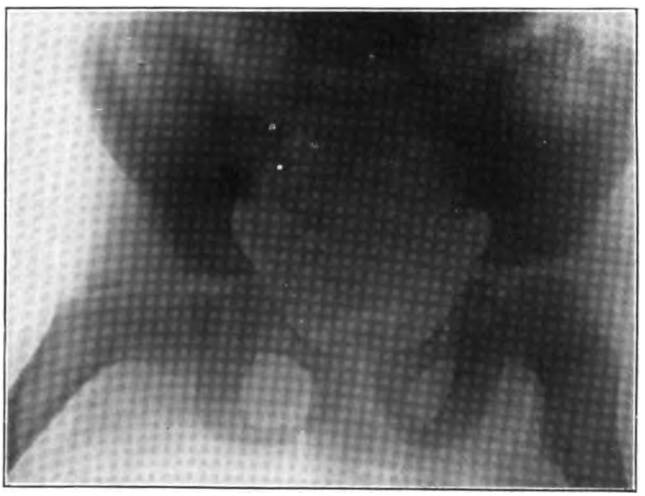

Fig. 1.—Right-sided congenital dislocation of the hip. Reduced by manipulation and subsequently verified by arthrotomy.

Fig. 2.—Bilateral congenital dislocation of the hip after attempted reduction by manipulation. The right had reluxated. The left was shown at operation to be within the capsule, but anterior to the bony part of the joint.

Digitized by Google

Digitized by Google

stopping the hemorrhage there ensued a superficial infection, and in treating this a reluxation of the head on that side took place.

Finally, I would say I am not satisfied with this demonstration. It remains for one of us to approach the joint from the inner side, that is, behind the pectineus, then to incise the capsule longitudinally and actually see the femoral head peeping at us through the hour glass construction. Next close the wound and do a mechanical reduction, and finally reopen the wound and see in what way the relation of head, capsule and acetabulum had become modified. Then we will cease from speculation and actually know what we are talking about.

Digitized by Google

STRUCTURAL CHANGES IN CONGENITAL HIP DISLOCATION

WALLACE BLANCHARD, M.D.

Assistant Clinical Professor in Surgery (Orthopedic), Rush Medical College; Orthopedic Surgeon, Home for Destitute Crippled Children and University Hospital

CHICAGO

A diversity of forms of dismantlement and reconstruction are always shown in the roentgenographic presentation of a number of congenital hip dislocations taken before and several years after reduction. In every case the roentgenogram offers a suggestion as to the best position in which to place and hold the leg, in the plaster-of-Paris spica in order to secure stability of the head of the femur and ultimately a good functionating joint.

In congenital hip dislocation, the obliteration of the acetabulum, the flattening of the head of the femur and the changing shape and direction of the neck are always shown in varying forms. When the mushroomed or cone-shaped head of the femur is placed and held approximately where the acetabulum once existed, the head usually again develops and cartilage grows up around it and deepens till, by a rebuilding process, a more or less functionally perfect joint is formed. The technic of bloodless reduction has steadily improved since the first visit of Professor Lorenz to this country in 1902. The forceful stretching method then employed, which frequently resulted in fracture of the femur without replacement, was superseded in 1904 by Prof. Albert Hoffa's milder manipulative reduction.

Digitized by Google

Some operators stretch every possible set of muscles and reduce over the superior or posterior rim of the acetabulum. Other operators, without preliminary muscle stretching, flex the hip and press strongly and continuously down on the knee till the head is pushed below the acetabulum, and then lift the head over the lower rim into position. The dangers of fracture or of other injury are largely decreased when the head is reduced over the more shallow lower rim. A reduction should not be accepted as satisfactory unless the head of the femur can be felt in the groin.

After the reduction, it is the position of the limb in the plaster-of-Paris spica that gives it stability or lets it go out. The roentgenogram usually gives a good indication of the position in which the leg should be held to secure stability.

If a small portion of the roof of the acetabulum is left so that it is shown in the roentgenogram even as large as a pea, a posterior dislocation may be reduced with a reasonable certainty that it will remain secure if the hip is firmly held in the Lorenz position of 90 degrees both in flexion and abduction.

The short unilateral plaster-of-Paris spica secures sufficient fixation for practical purposes of stability. The following case is presented to cover several points, including the opposing views of many European surgeons who agree with Bankart[1] that "a unilateral plaster is unsatisfactory as it does not fix the hip properly."

CASE 1.—B. J., girl, aged 6 years, with a congenital dislocation backward of the right hip, and the leg 3.5 cm. short. The roentgenogram showed the acetabulum obliterated except for a small flat button that was left of the roof. The head was atrophied and mushroomed to half its normal size and thickness. The neck was shortened and elevated. The dislocation was reduced and the hip was placed in the position of 90 degrees flexion and abduction and put in the short unilateral spica, as shown in Figure 1 *A*. One month later the

1. Bankart, A. S. B.: Treatment of Congenital Dislocation of the Hip, Brit. Med. Jour., 1913, i, 1044.

Digitized by Google

patient contracted diphtheria and, following the use of antitoxin, developed a dermatitis under the plaster spica necessitating its removal. Pneumonia followed the diphtheria, and after eight weeks without the plaster I found the head of the femur still in place. The rebuilding of the articulation had gone on without interruption. The plaster spica was renewed, and eight months after the reduction it was discontinued and the patient left to her own devices.

A roentgenogram (Fig. 2) taken soon after the removal of the spica showed a tilted pelvis of abduction with the head in place. A light strip between the head of the femur and the acetabulum indicates the space that is filled by the new acetabulum that is not yet sufficiently advanced in calcification to show in the picture, but is serving well for retention.

Walking for several months after the plaster spica has been removed with the leg in abduction has a double advantage of deepening the acetabulum and of keeping the head more securely in place.

A roentgenogram (Fig. 3) taken three years after reduction shows a new femoral head built up over the atrophied and mushroomed head to the full size of the normal head, and above that a new acetabular roof shows dark and strong, and the hip is functionally good.

Case 2.—R. G., girl, aged 3½ years, with double congenital hip dislocation. A roentgenogram (Fig. 4) showed a double congenital hip dislocation with small buttons as the only remnants of the overhanging roofs. Reduction was made over the lower rim, and the hips put in plaster in the right angle flexion and abduction position.

A photograph (Fig. 1 *B*) was taken soon after the reduction. One month after the reduction the patient was reported dangerously ill with diphtheria, and following antitoxin a dermatitis developed under the plaster, which was removed. After four weeks without the plaster spica a roentgenogram was taken that showed both femoral heads to be in place. The legs remained in the "frog position," and a new plaster spica was applied.

The roentgenogram of this case showed small round buttons of bones as all that remained of the roofs. The visible remnants of the roofs were, of course, supported by considerable decalcified bone, and these formed buttresses against redislocations.

Case 3.—H. F., girl, aged 6 years, with left hip dislocated posteriorly and leg 3.5 cm. short. The reduction was too easy and no security was imparted to the head with the leg either in the primary position of Lorenz, or in the Lange position; but elevating the hip to 30 degrees above the Lorenz position toward Werndorff's axillary position imparted stability. A plaster spica was applied with the hip in this exaggerated position and left for eight months in the belief that the

Digitized by Google

Fig. 1.—*A* (at left), B. J. (Case 1) in plaster-of-Paris spica after reduction of congenital hip dislocation. *B* (in center), R. G. (Case 2) in plaster soon after reduction. *C* (at right), H. F. (Case 3) in plaster soon after reduction.

Digitized by Google

Fig. 2 (Case 1).—Roentgenogram taken soon after the removal of the plaster spica.

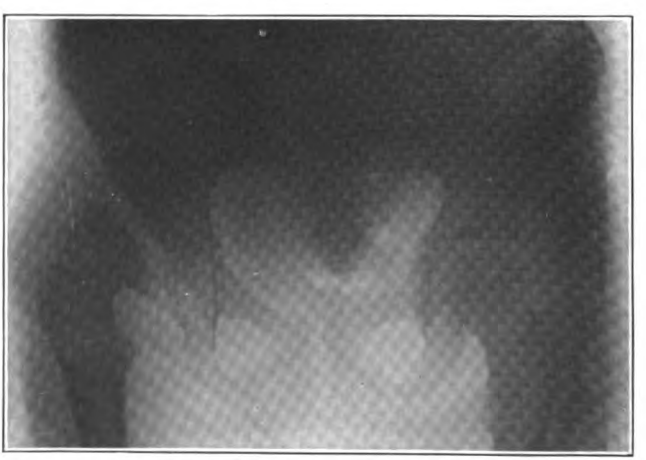

Fig. 3 (Case 1).—Three years after reduction.

Digitized by Google

Fig. 4 (Case 2).—Double congenital hip dislocation with small buttons as the only remnants of the roofs.

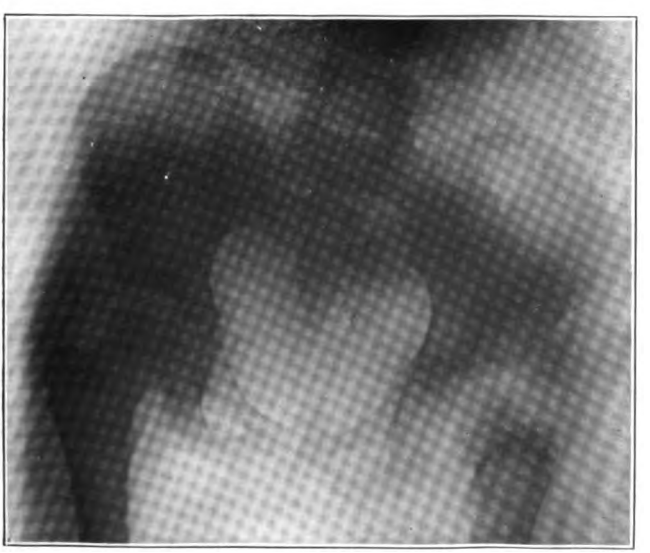

Fig. 5 (Case 3).—Soon after removal of the plaster.

Digitized by Google

Fig. 6 (Case 3).—Two years after removal of the plaster.

Fig. 7 (Case 4).—Before reduction.

Digitized by Google

Fig. 8 (Case 4).--Two and a half years after reduction.

Digitized by Google

Digitized by Google

objections to so doing had not been sustained. The normal leg was included in the plaster as a counter lever to secure fixation, as shown in Figure 1 *C*. The plaster spica was removed after eight months and the patient left to her own devices. The leg was over a year coming down from abduction to normal position.

The roentgenogram (Fig. 5) taken soon after the removal of the plaster shows a tilted pelvis, decalcification of the upper end of the femur and the adjoining pelvic bone as well as a roughened outline at the original seat of the acetabulum. An irregular cavity marks the original site of the acetabular roof, which explains why the leg had to be elevated toward the axillary position to secure stability.

The second roentgenogram (Fig. 6), taken two years later, shows a recalcification of the lightened bones. Also a new roof shows the dark shadow of strength, and the head of the femur is in place. Even after three years there remained a slight suggestion of abduction, though the leg was functionally perfect.

From three to five years may be taken as the age for reduction to get the best ultimate results. The increasing dismantlement of the unreduced hip joint as the child grows older and the insufficient ossification in younger children that allows soft bone to give way during and after reduction must be considered. The following case presents the two sides of the question:

CASE 4.—M. H., girl, aged 2 years and 3 months, with congenital dislocation backward of the right hip, and the leg 3.3 cm. short. A roentgenogram (Fig. 7) taken before reduction showed that the right upper femoral shaft and neck had about one half the diameter of the left. The head of the femur had almost disappeared, and the overhanging shelf was nearly obliterated. A roentgenogram (Fig. 8), taken two and one-half years after reduction, showed a redevelopment of the upper femoral shaft, neck and head. Also the roof had reappeared dark and strong. But note the wide strip of light between the head of the femur and the nearest bone of the pelvis that indicates the situation of the soft reforming acetabulum and femoral head. Experience shows that weight bearing will cause this pliable acetabulum and head to give somewhat so as to produce some shortening before recalcification and ossification are sufficiently advanced to afford a stable joint. The ultimate result is likely to show that the reduction was made too early, though at present the legs are the same length and function is perfect.

Digitized by Google

Changing the position of the leg after two and a half months in plaster, as is advised by Calot and others, interrupts the rebuilding of the articulation which is necessary to secure a stable joint.

The prognosis may be said to be favorable in posterior dislocation, unfavorable in forward dislocation and unfavorable in upward dislocation, if on rotation of the leg the head can be felt both anteriorly and posteriorly.

Bankart's[1] conclusion that "no operative method reaches the excellent results obtained by manipulative reduction" has been quite generally accepted. The elimination of unnecessary violence has marked every step forward in the reduction of congenital hip dislocation.

CONCLUSIONS

Experience seems to warrant the following conclusions:

A shortened or twisted neck in a coxa valga position may look unpromising in the roentgenogram, and yet present no bar to a good reduction and ultimately to a good functionating joint.

Eight months is the shortest time in which a dependable acetabulum reforms, and any radical change in the position of the leg interrupts the rebuilding process. The unchanging pressure of the femoral head accelerates the absorption of the extraneous structures that obstruct the acetabulum. After the plaster spica has been removed, the child should be left to its own devices, and the longer the abduction remains, the more stable the joint will become.

The best functional results may be obtained in children from 3 to 5 years of age and with from 2.5 to 4 cm. of shortening. There is no age limit, upward. The older the child and the greater the shortening, the more secure the replacement, if it can be made. The difficulty of reduction increases with the shortening after 4 cm. have been passed. A reduction by

Digitized by Google

steps can be gained in older children with 5 cm. or more of shortening by following the practice of the Vienna school. The head should be brought as near as possible to the acetabulum and put into a plaster spica just the same as if reduced, and a second attempt, made three weeks later, may result in a satisfactory replacement.

Reduction should be delayed in all cases of 3 years or younger and that show 2 cm. or less of shortening.

The child needs all the freedom that can be safely accorded, and a great majority of unilateral cases will do best in unilateral plaster spica.

The reduction must be made at an age of susceptibility to diphtheria and other children's diseases, and the two cases here given show that if the plaster spica has been on a month or more and the roentgenogram reveals even a small remnant of the roof, the plaster may be left off one to two months with the patient on the bed without much danger of a redislocation.

If the roentgenogram shows delayed ossification from rickets or other causes, the reduction must be postponed. Roentgenographic observations of the hips should be taken before and after reduction and at frequent intervals so that a careful watch may be kept of the bone regeneration that produces a good joint.

Perfect or satisfactory function may be obtained in a large majority of the unilateral and a fair proportion of the bilateral cases.

The case that looks the best may turn out the worst, and the reduced hip that feels the most stable may be the first to go out; but a careful roentgenographic study of each case will go far toward placing the reduction of congenital hip dislocation on a more assured basis.

15 East Washington Street.

Digitized by Google

ABSTRACT OF DISCUSSION

ON PAPERS OF DRS. HIBBS, WATKINS AND BLANCHARD

Dr. John Ridlon, Chicago: I believe that Dr. Hibbs' operation is wholly unnecessary. He was good enough to let me replace one hip after he had turned the thigh bone, as he showed you today. I was very anxious over the case and found it very difficult because things did not feel natural. I believe that the operation recommended by Dr. Watkins and done by Dr. Sherman yesterday is wholly unnecessary. I believe that there is a great deal less deformity about the head and neck of the femur than we have been accustomed to believe. Some hips are dislocated backwards and upwards, some are dislocated forwards and upwards, and some are dislocated directly upwards. We have talked about the twisting of the neck for years and years, and believed that existed. I do not know whether it does or not. Now we are told that it is not there, that it is in the shaft, but I do not know whether the shaft is twisted or not. We have believed that all these dislocated hips had "hourglass" contraction, so that the head could not be tucked back through the narrow passage. I do not think they all have it; some of them may, and very likely some of them do have it. We have been taught that the sockets were all malformed and filled with fat, fibrous tissue, and the cotyloid ring had so narrowed that the head could only go to the opening of the socket and not into the socket. Now I am sure that is not so in some cases. I am sure that the main fault in most of these congenital hips is because of a defective and a shallow socket, and here is my evidence, in two pictures that I will pass; first, of a man, 52 years old, a policeman, 6 feet 4 inches tall, and tremendously broad and heavy, and he had never had a particle of trouble with his hips in his life. These pictures show that in one hip only two-thirds of the head is included in the socket, and in the other hip one-half of the head is included in the socket. Here is another picture with a socket no deeper than the palm of my hand. I replaced this hip several years before Lorenz came here. When the plaster was taken off, the hip appeared to be normally in place. I didn't see the child again until several years afterwards when the existing condition was found. She walked with scarcely a perceptible limp. I believe no man, whether he manipulates by my method or Lorenz' method or Davis' method or any other method, or cuts down on it by Hibbs' method or Sherman's method, will get a better socket than Hoffa used to get, and many of his slipped out.

However you operate, whatever your methods are, you will get, according to your skill, a certain percentage of

Digitized by Google

good cases, and you will have a certain percentage of cases in which the hip slips out.

Dr. Leonard W. Ely, San Francisco: During the reading of these papers a thought has occurred to me which I think would be well to mention. In visiting one of the hospitals in the city here a few days ago I saw a patient who was to be operated on for congenital dislocation of the hip. The Roentgen picture showed the dislocation. There was no wound on the leg, no history of any disturbance at all. The mother had simply brought the child in and left it on account of its failure to walk. I recognized the child as a patient I had treated several months before for arthritis. I had withdrawn a syringe full of pus from the hip. The arthritis slowly subsided without further treatment, leaving behind a typical dislocation of the hip, with no sign whatever of any operation, and I wondered how many of these cases that come to us in this walk of life are of the same kind.

Dr. Russell A. Hibbs, New York: There is one other point which I did not make in my paper. There must be some relation existing between the direction of the head and neck of the femur and the direction of the center of the acetabulum. It is quite possible in some cases that the amount of anteversion in normal femurs and in normal heads varies, and to meet that condition there must be a variation in the direction of the center of the acetabulum. It is obviously very difficult to determine that question.

Dr. James T. Watkins, San Francisco: Among the procedures which we of the Children's Hospital staff have been employing of late years in the treatment of our congenital hip dislocations has been the subtrochanteric osteotomy which was first advocated by the late Professor Schede of Bonn as a means of correcting the forward twist of the upper end of the femur on the shaft. We differ from Dr. Hibbs in that we make the correction after reduction instead of before it, and attack the upper instead of the lower end of the shaft. Regarding the results of arthrotomy followed by osteotomy, our most careful estimate has given rather better than 70 per cent. of cures, which were both anatomically and functionally complete. Dr. Ridlon has lifted a great weight from my mind. If I understood him aright, one may reduce a congenital dislocation of the hip, and if God so wills it will stay reduced; otherwise it will not. Often in the still watches of the night I have worried lest imperfect results in my cases of congenital dislocation might be due to my own defects, and, humbly confessing my sins before God, I have sought diligently wherein I might do better. But now since I learn that not I but God did it, I feel better and shall sleep better.

Digitized by Google

Dr. Wallace Blanchard, Chicago: Wolf's law governs in dislocation of the hip and in the replacement of the head of the femur, the same as it governs and controls the breaking down and reconstruction of other parts of the body. The acetabulum distorts and flares out and the direction of the head and neck changes during the whole period of dislocation, but after replacement, the head builds up in the direction where the stress of weight bearing occurs and the overhanging shelf builds up where the stress of weight bearing must fall, and so Wolf's law governs and helps to replace the hip joint and make it something toward the normal.

Digitized by Google

PAINFUL FEET

CAUSES AND TREATMENT

HENRY W. FRAUENTHAL, A.C., M.D.

Fellow of the American College of Surgeons; Physician and Surgeon-in-Chief, Hospital for Deformities and Joint Diseases

NEW YORK

In discussing the causes of painful feet, I have selected those forms which numerically are most common. As, in the majority of joint conditions, the advice of the orthopedist is sought after the condition becomes chronic, so, too, in painful conditions of the foot, we are not applied to for advice until the condition has gone on for some time and becomes so painful that locomotion is too difficult to be tolerated.

I wish to call attention to the great frequency of foot infections secondary to focal infections in other parts of the body, as in the teeth, gums, mouth, throat and nose; also after grip, pneumonia, typhoid fever, etc., as I have found these to be the cause of the largest percentage of painful feet in adults and children, in the cases examined at the Hospital for Deformities and Joint Diseases during the past two years.

This idea can best be presented by quoting from the recent article by Dr. Lovett[1] of Boston. In his report of 800 nurses with painful and flat feet in the Massachusetts General Hospital, Dr. Lovett states that "the onset was frequently after grippe, tonsillitis, or acute illness of one sort or another." Now, when infection of the feet which involves all the soft tissues, muscles, tendons, bursa, ligaments, etc., results the ligaments sustaining the arch become relaxed, and

1. Lovett, R. W.: The Superstition of Flat Foot, The Journal A. M. A., April 10, 1915, p. 1208.

Digitized by Google

unless some fixation support is used, there will be a stretching of the ligaments and breaking down of the arch of the foot, which may or may not continue to be painful.

A similar process is overlooked in children after tonsillitis, measles, scarlet fever, etc. I hope that in the future, when secondary results are looked for in the heart, physicians will investigate the muscles supporting the foot, and when children complain of later rheumatic pains in the foot and legs, proper preventive measures can be used to avoid the later chronic foot trouble.

Our present efforts must be to seek the primary focus of infection and aim at its eradication, after measures for the fixation of the foot and temporary support of the arch have relieved the symptoms and been productive of partial cure.

To treat this condition properly, a plaster cast supporting the arch and retaining the foot in a fixed position is the most perfect splint.

The strapping after the method of Ochsner[2] is also an efficient means of fixing the foot and sustaining the arch.

The Whitman[3] plate, as a support and fixation, has its value. This is also true of other arch supporters. But the too long continued fixation by metal arch supporters results in atrophy of the interosseous muscles, fat, etc., owing to their nonuse. The hardness of the metal is objectionable, as it develops callus of the skin and periostitis of the bones.

When the inflamed foot is neglected or not properly treated, the inflamed agglutinated surfaces fuse together, and we have the fixed or static foot, in which there is no motion between the small bones. This type of foot is most unsatisfactory to treat. I have obtained the best results by heating them in dry air from 250 to 400 F. by means of a Tyrnauer electric baker, and

2. Ochsner, E. H.: Potential and Acquired Static Flat Foot, The Journal A. M. A., Nov. 23, 1907, p. 1742.

3. Whitman: Med. Rec., New York, Aug. 13, 1907.

Digitized by Google

then manipulating and massaging them. I will cite a few cases showing types of focal injections:

CASE 1.—*Infectious arthritis from infection of gums.*—Mr. F. H., a detective, referred by Dr. Austin Holles, New York, applied at the Hospital for Deformities and Joint Diseases complaining of flat and painful feet. For two years previous, he had been treated for his painful feet by various types of foot plates given him at the advice of different physicians. In the past three months, his pain had become so acute that it was impossible for him to get about with the aid of a cane, and he was incapacitated from attending to his work. The appearance of his feet made one suspicious of an infectious arthritis. The Wassermann test for syphilis was negative; the agglutination test for gonorrhea was also negative. An attempt to determine the focus of infection revealed infectious pyorrhea of a number of the roots of the teeth. As this resembled the type of case in which symptoms have been benefited and relieved by sterilization of the gums and cleaning up of the deposits in the roots of the teeth, this method of treatment was pursued in this case.

Although the arch of the foot had decidedly broken down, and the Roentgen ray showed evidence of the infectious process, after two weeks' treatment the patient's symptoms of pain had all disappeared, and for the past four months he has been able to attend to his business, and is free from pain; he has also discarded his arch supporters and cane.

This is an illustrative case of many which have been relieved of all the painful symptoms after the sterilization of pyorrhea infection. I hope that infections of the teeth will be given consideration in future examinations of painful feet.

CASE 2.—*Infectious arthritis of the feet from infection of tonsils.*—Mr. M. S., aged 28, bookkeeper, with no venereal history, does not drink spirituous liquors; smokes one dozen cigarettes daily. About six weeks previously, patient had an attack of acute tonsillitis; about two weeks following, the feet were painful and swollen; a few days later, the swelling subsided but the pain continued and grew worse. Owing to the pain and difficulty in walking, he was referred to the Hospital for Deformities and Joint Diseases by his family physician. Examination revealed the tonsils inflamed and enlarged, and the patient was referred to Dr. Julius Auerbach, the throat specialist of the institution, who coincided in the opinion that the throat was undoubtedly one of the sources of infection. The patient was then referred back to his family physician with our opinion and the advice

Digitized by Google

that the tonsils be removed. This was done at the hospital by Dr. Auerbach, March 4, 1915. For the next two days, there was increased pain and tenderness in the feet which gradually subsided, and for the past three months the patient has remained well and is free from all pain. The microscopic examination of the tonsil shows streptococci.

INFECTIOUS ARTHRITIS OF THE FEET FROM NONGONORRHEAL LEUKORRHEA

There is a special class of infectious feet found in married women between the ages of 20 and 40 that are of great interest. Patients are negative to Wassermann and Noguchi tests and also negative for the agglutination fixation test. There is a vaginal discharge and often laceration of the cervix for lymphatic absorbtion. We fail to find gonococci in repeated smears.

The feet are slightly swollen, tender and painful to walk on. I have been able to cure a number of these cases by antiseptic douches of mercuric chlorid and iodin solutions.

The following case is illustrative:

CASE 3.—Mrs. B., aged 32, married at the age of 22, had three children and no miscarriages. She had some vaginal discharge following birth of second child five years ago, continued after birth of last child two and a half years ago; no increased temperature or illness after any of her confinements. For the past two years she has worn arch supporters for painful feet, with little relief of symptoms. When patient was first examined by me, Nov. 18, 1914, her feet were somewhat swollen and very tender when walking. There was a suspicion of neisserian infection from their appearance; several examinations were made of the discharge, but no gonococci found. Her husband denied venereal history; an examination of his urine and prostatic secretion was also negative. Patient received vaginal irrigation with 1:5,000 mercuric chlorid solution three times a day. In five days the symptoms in the feet began to improve and in two weeks had all disappeared. The patient has gone about with ordinary shoes without arch supporters and has remained well ever since.

This is one of a class of cases of nongonorrheal vaginal infection.

Digitized by Google

OVERTAXATION AND NONUSE OF MUSCLES

In addition to the class of feet that are weakened by infectious process, we have a second class that occurs in policemen, motormen, salesmen, pedlers, etc., who, owing to their standing for long hours, overtax the muscles that support their arches.

A similar condition is often brought about by the sedentary occupation of men and women, and by the nonuse of the muscles, an atrophy taking place in the anterior and posterior tibial muscles, resulting in a letting down of the arch of the foot, together with pain in the arch of the foot about the external malleolus, the pain often extending to the insertion of the internal lateral ligaments of the knee; we also have pain in the hip joint, occasionally in the small of the back and often between the shoulder blades.

In the latter class of cases, much benefit can be obtained by having the patient go through muscle exercises and the use of the Zander apparatus, which develop the muscles that hold up the arch of the foot, and by having the patient bear the weight of the body on the outer side of the foot; this can be aided by building up the inner border of the shoe from one-eighth to one-fourth inch and attaching a Thomas projecting heel, and the patient walking so that the inner borders of the feet are parallel.

In this class of cases, if arch supports are needed, I use felt pads shaped to conform to the arch of the foot, with sufficient thickening to give proper support and elevation until the muscles are developed to support the arch of the foot properly.

GONORRHEAL INFECTIONS OF THE FEET

In considering the various causes of painful feet, I do not think that a proper amount of consideration has been given to the neisserian infection, when we consider that about 60 per cent. of the male population acquire the infection. The trouble in the feet may

Digitized by Google

occur in the first week of the infection. It may appear years after the original attack from a focus in the prostate and seminal vesicles of the male, or from the tube and ovaries in the female, producing periostitis, bursitis and spurs. I have experienced some unlooked for surprise from making a uniform agglutination fixation test in acutely inflamed feet. Roentgenoscopy reveals the rarefaction of the bones and spurs.

Cases 4 and 5 are striking illustrations:

CASE 4.—Mr. M., the proprietor of a drug store, had feet which were painful on walking and on pressure, tender and swollen. He had been treated by various consultants in the past two years with all forms of antirheumatic treatment, without any benefit. In my judgment, his feet had the appearance of neisserian infection. When I made this suggestion to the doctor, both the doctor and patient became very indignant, as the patient had been married eight years with two healthy children. At first, the patient objected to examination, but later consented. A large inflamed right lobe of the prostate was found, and from the secretion expressed and sent to the laboratory, active virulent gonococci were found. Under appropriate treatment, massaging of the prostate and protargol irrigation, the pain in the feet entirely disappeared and the patient made a perfect recovery and is able to go about in ordinary shoes.

CASE 5.—Man, aged 23, chauffeur, had gonorrhea at the age of 14. Owing to a painful heel at the age of 18, a roentgenogram was taken which showed spurs; he was operated on and the spurs removed; pain was not completely arrested and a second operation was performed, when the pain disappeared for four years, but reappeared. He applied at the Hospital for Deformities and Joint Diseases. History of last atack of pain in the heel dates back to two months, when he began to suffer pain in both heels extending over the malleoli; arches weakened, movements limited, especially dorsal flexion and adduction. He still had a morning drop; urine shows presence of gonococci. Roentgenoscopy reveals a new outgrowth of bone over the area previously operated on; also spurs. Patient is now under treatment by massage of the prostate, irrigation with protargol and autogenous vaccines; later an operation will be performed.

TUBERCULOUS INFECTIONS OF THE FOOT

This is found most often in children, appearing gradually with some swelling and pain, local tenderness on pressure, and the child shows a slight limp. Later the swelling increases and there is a breaking

Digitized by Google

down of the infected area. The Roentgen ray shows rarefaction and breaking down of the small bones; the von Pirquet is generally positive, and an excess of acid-fast bacillus is found in the feces.

I have been successful in curing a number of such cases by the building up of the general health of the patient, and soaking the affected foot in hot water for one hour three times a day; we thus obtain a primary hyperemia from the hot water, and a secondary one when we replace the water pressure of 62½ pounds to the square inch by the atmospheric pressure of 16 pounds, thus keeping up the hyperemia for some hours.

SYPHILITIC CONDITIONS OF THE FOOT

The periostitis and osteitis of the bones of the foot and gumma of the soft parts are found in congenital and later acquired syphilis, in which we have pain and great local tenderness, which, if promptly treated by our syphilitic remedies, does not break down; but on delay, we may have to resort to surgical procedure.

As aids to diagnosis, we have (1) patient's history; (2) finding the *Spirochaeta pallida;* (3) Wassermann test; (4) Noguchi test; (5) the Roentgen ray, showing (*a*) periosteal thickening, and (*b*) a uniform bone shadow of compact and cancellous tissue (first report by the author, 1906), on which a diagnosis should be made without a blood test.

For the treatment of syphilitic bone conditions, an intravenous injection of salvarsan is given and repeated every seventh day, from three to six injections being given, after which inunctions of unguentum hydrargyri, 50 per cent., are applied daily. If evidence of salivation appear, the mercury is discontinued for a time.

CASE 6.—Mr. N. H., aged 36, was referred to me by Dr. Fishberg, examining physician for all medical cases applying at the United Hebrew Charities, City of New York. Patient had complained of pain in both feet and had been advised to wear foot plates. Not having the means to pur-

Digitized by Google

chase these, he was referred by the doctor to the Hospital for Deformities and Joint Diseases, without his making a personal examination. The following history was obtained, Sept. 22, 1913: Six months previous to onset the patient suffered with headaches, which were so severe at night that he was compelled to discontinue his occupation, which was that of a waiter. Oct. 23, 1913, he had fever and chills during the night; the following morning, he was unable to get up; the left knee was swollen and powerless; he complained of pain when attempting to bend it. He sent for Dr. A, who diagnosed the condition as rheumatism and applied black salve (ichthyol); the patient was under his care for four weeks, but the condition remained unchanged; Dr. A therefore referred the patient to Hospital 1 under care of Dr. B; here he received twenty-one treatments of baking apparatus at the rate of three treatments per week; but as he felt no better, Dr. B referred him to Hospital 2, where he came under the care of Dr. C in the orthopedic department; this doctor diagnosed the condition as loose cartilage and applied a plaster cast for two months, but no relief was obtained. Then the patient sent for his lodge physician, Dr. D, who diagnosed the trouble as synovitis and tried to tap the knee twice in two places, but did not succeed. Next the patient was referred to Dr. E at Hospital 3; but as Dr. E was not there at the time, he came under the care of Dr. F, who immediately removed the cast, believing that this would cause ankylosis. He cauterized the knee three times a week for several months, tapped it, and had a knee cap made which the patient was still wearing when he applied at this institution. As he still obtained no relief, Dr. D referred him to Hospital 4 under the care of Dr. G; a roentgenogram was taken which, the physician said showed tuberculous spots of the bone, and Nov. 19, 1912, an operation was performed in which a portion of the tibia was removed; the patient remained in the hospital four days, was discharged and instructed to return three days later, which he did; at this time he was examined by a dispensary physician and then advised to return three days later; meanwhile the patient became feverish and chilled and complained of sticking pain; he sent for Dr. D, who said he was too ill to be removed to Hospital 4, and was therefore transferred to Hospital 5, where he remained for eleven weeks; his knee was opened and cleansed thoroughly, then cast was applied for eight weeks; in January, 1913, he was discharged; then Dr. F, in charge of the orthopedic department at Hospital 5, was sent for, and having recognized him, instructed him to return to the dispensary at Hospital 5; his knee was cauterized, baked and massaged for several months; following this treatment, he was able to bend the knee; the swelling decreased considerably and the pain was somewhat relieved.

Digitized by Google

In February he complained of severe pain and cramps in the left ankle during the night; the following morning, he noticed swelling present; he went to Dr. F and a roentgenogram was taken which showed some injury to the bone. June 14 the patient was sent to Hospital 5 and an operation was performed in which the bone was scraped. Dr. H diagnosed it as synovitis and applied a cast for four weeks, but the condition remained the same. Finally the patient applied at this institution for treatment, Sept. 22, 1913. He was referred by Dr. Fishberg for foot plates.

Objective evidence of the knee joint: 1½ inches larger than the opposite knee; has a synovitis in which motion produces scarcely any pain and the limitation of the motion is only by the restriction fluid in the joint. Ankle 2 inches larger than the opposite ankle; no pain or tenderness on pressure with limitation of motion.

The swollen appearance of the patient's feet and ankles led me to suspect syphilis. The roentgenongram of his foot showed syphilitic periostitis. The Wassermann determination was 4+ positive. The point of interest in this case is that after passing through five different institutions and medical examinations by eight physicians, in no case had the Roentgen ray excited suspicion as to the patient's trouble being syphilitic, and in no institution was a Wassermann or Noguchi test made. The patient, under salvarsan, mercury and iodid, made a perfect recovery, wearing a Frauenthal knee splint for a short time, owing to the relaxed condition of his knee joint. The swelling and discomfort in his feet were completely relieved after two weeks of antisyphilitic treatment. He has remained well for the past two years.

GOUT

The causes of gout have not yet been positively ascertained, for there is still a doubt as to whether it is due to the defective elimination of the urates themselves, or, on the other hand, whether it is a disturbance of the purin bodies, which will later result in the formation of combinations of urates. The clinical entity called gout is brought about by the sodium biurate and other imperfect combinations of uric acid deposited in the tissues.

There is no doubt that all the large joints are affected with gout, but the most frequent affection is in the big toe. Pain, swelling, redness of the toe and an inclination to keep the foot elevated are the characteristic symptoms.

Digitized by Google

The internal administration of colchicum does not change the quantity of urea eliminated, and there is a decrease in the excretion of uric acid.

This in no way explains the relief of pain and the subsidence of symptoms when colchicum is administered; neither can I add any light on the rapid relief of the symptoms, when we carry in our mind the joint pathology.

For a period of twenty years I have given to patients in an acute attack of gout, involving the smaller joints or the knee, treatment which consists of applying sponge electrode saturated with the fluidextract colchicum attached to a galvanic current, reversing the current every two minutes, using the current of a strength up to the patient's point of tolerance of pain. Three treatments in thirty-six hours relieved all the acute symptoms of pain, swelling, etc.

CASE 7.—Mr. F. V. W., manager of a hotel, whom I first saw in consultation, April 16, 1909, was confined to bed after an acute attack of gout involving the right big toe. In all previous attacks he had been in bed from two to three weeks, and reconciled himself to remain that time. When I saw him I informed him that if he would come down on crutches to my office in a cab, I would give him relief in less than three days. He regarded this prognosis as ridiculous, but said that sooner than remain in bed and suffer the agonies of the disease, he would take a chance. After the second treatment, he was able to put his foot on the ground, and on the third day, discarded his crutches and walked about, since which time (1909) he has been treated for seven attacks by the same method.

OBLITERATING ENDARTERITIS

This is a common disease among Russians, Poles and Galicians, characterized by the following symptoms:

The subjective symptoms differ only in the intensity. The patient complains of intense pain in the toes and feet extending up the leg, increasing at night.

The objective symptoms are:

1. The patient walks with a distressed gait, resembling painful flatfoot, for which he is often treated.

Digitized by Google

2. The feet appear blue, congested and cyanotic, but the pressure of the hand and manipulation of the foot elicit little pain.

3. The sensitiveness to heat and cold is diminished.

4. The skin has the clammy feeling of death. Nothing that I have felt has this cold uncanny feeling, except a cadaver.

5. The pulsation of the plantar arteries is either unrecognized or decidedly enfeebled.

The pain is so intense at night as to cause the patient to lose his sleep. In severe cases the patient remains in a chair to sleep for a short period, and then has to walk about. The pressure of the shoes adds to the pain, so some form of felt shoe, or similar material, is adopted, or in some cases a flannel cloth is wrapped around the foot and a large rubber or slipper is worn.

The pain is not so great in warm weather, but the symptoms, although growing more severe, gradually extend over many months and in some cases over years of time.

In some cases there is a type of atrophy of the toe, a darkening of the skin with a dry gangrene appearance, in which the progress of destruction differs materially in its rate of progress to that found in other forms of gangrene; in some cases the destruction of the toe occupies a period of years and only then are the toes partly destroyed.

Several of the patients applying for treatment were wearing arch supports, put on at institutions, regarding the affection as a type of flatfoot. In some the gangrene process began after an injury in cutting the nail of the great toe; in other cases after paring the corn on the small toe too closely. (There is a case for $25,000 now pending in court [Hamburger *vs.* Levy] in which the gangrene extends from the cutting of a corn and amputation at the middle third of the tibia was performed.)

This sounds a warning to physicians as to the danger in this class of cases of any interference for ingrown

Digitized by Google

toe nail, corns, etc., as the starting of a gangrene process.

The investigation of a number of similar cases shows that all local application and inward medication has afforded but little relief, and that a large number of amputations have been done to relieve the painful symptoms, in the hospitals of New York City.

In my own experiments, I found that the high frequency electric current, though it gave some relief, whitened the purple skin and seemed to cut off the circulation to such an extent and for so long a time that I feared an ulcer would develop at the spot.

Dry heat from 200 to 400 F. gave a relief of pain for a time, but no improvement to the gangrene; this was also true of hot water and normal salt solution carried to the patient's tolerance to this form of heat. Morphin or other anodynes fail to give relief of the pain.

CASE 8.—S. L., man, aged 39, Russian, a cutter, with no history of syphilis or tuberculosis, uses alcohol and tobacco moderately. He has one brother who was similarly affected, who at the age of 19 had the right leg below the knee amputated, and two years later, had his left leg amputated above the knee, since which time the brother has remained in good health with no extension of the process. The patient consulted me at the hospital in November, 1907, for a pain in the left foot which extended up the posterior part of the leg to the knee, which had begun two years before. He had not been able to work for six month, nor had he worn a tight shoe on the left foot for six months. For five months he had not slept in a bed but in a chair, and only for a short period at a time. When he was compelled to walk about to relieve the pain, the foot had constant pain which was accompanied by lightning-like radiating pains up the leg from time to time, being more frequent at night.

The foot was cold blue, with a beginning gangrene of the little toe; the arteries could scarcely be felt. The patient had already been given local heat to the feet by hot sand, salt and water, also with various local applications of salves and ointments together with internal medication, without permanent benefit or the arrest of symptoms. I determined to try the effect of the heat and light as obtained from a 500 candle power incandescent light. The heat was interrupted every few seconds, but only when he could no

Digitized by Google

longer tolerate it; this was kept up for a period of fifteen minutes on his first visit. On his return the next day he declared he had slept during the night for a longer time than in months and without pain. I thought this was merely mental suggestion; I repeated the treatment daily for five days regularly, after which patient again wore shoes and continues to do so. The pain gradually disappeared, the gangrene in the little toe resolved and a new nail appeared, and the patient has been well without symptoms for the past six years. He has continued his treatment at home by means of a small lamp.

We have treated over 300 of these cases at the Hospital for Deformities and Joint Diseases, our present method of treatment consisting of the administering of one-fifth grain extract of thyroid three times a day, giving from 300 to 500 c.c. salt solution subcutaneously, and exposing the patient's foot for twenty minutes to white light to the point of tolerance of heat; I also advise exposure to sunlight when possible. This treatment arrests the process and stops the pain in a large number of these cases.

I have seen but two cases of obliterating endarteritis in American-born citizens.

CASE 9.—One foot of the patient had been removed at the Presbyterian Hospital for a similar condition. When they advised the removal of his other foot two years ago, he came under my observation. The process has been arrested, the pain has all disappeared under only white light treatment, and he is now able to attend to his work.

CONCLUSIONS

We can regard feet as normal only when the foot in action moves through the normal plan of action in relation to the leg. To have feet perform their normal function, nothing is more important than proper shoes. In adapting treatment for painful feet, we must determine whether we are dealing with an infection of the foot or a relaxed condition of the supporting structures.

If the pain comes on acutely, we have infection (except with trauma); if the pain is developed gradually, we have relaxation of the supporting structures.

Digitized by Google

The promiscuous application of foot plates has been condemned by many of the leading orthopedic surgeons. There is no doubt that there are many cases of painful feet due to strain that require some support under the arch. This can best be done by some yielding, springy substance, such as felt, much better than metal arch supports, and the sooner they can be removed, the better for the patient. The foot should have freedom of action in locomotion, not fixation.

BIBLIOGRAPHY

Austin, Cecil Kent: The Paroxystic Attack of Metatarsal Pain (Morton's Metatarsalgia), Med. Rec., New York, Oct. 11, 1913.

Berry, John M.: Some Practical Lessons from a Study of 200 Cases of Weakened Feet, New York Med. Jour., June 19, 1909.

Boehme, Gustav F.: Pedal Tic, Med. Rec., New York, July 25, 1914.

Ely, Leonard W.: Rheumatism of the Feet, Med. Rec., New York, Aug. 5, 1905.

Fiske, J. P.: Concerning the More Common Disabilities of the Foot, New York Med. Jour., Feb. 23, 1907.

Frauenthal, H. W.: Obliterating Endarteritis of the Digitalis Dorsalis and Plantares, Tr. XVI Internat. Cong., Budapest, 1910, 906; Gonorrheal Arthritis, Med. News, May 13, 1905; Syphilitic Arthritis, Med. Rec., New York, May 26, 1906; Gout, Jour. Advanced Therap., June, 1913.

Geist, E. S.: The Rôle of the Tendo Achillis in the Etiology of Weak-Foot.

Grandon, L. R. G.: Orthopedic Heresies on Feet and Their Treatment, Boston Med. and Surg. Jour.

Hibbs, R. A.: Muscle Bound Feet, New York Med. Jour., Oct. 24, 1914.

Lovett, R. W.: Flat-Foot in Infants and Children.

Morton, T. S. K.: Metatarsalgia (Morton's Painful Affection of the Foot with an Account of Six Cases Cured by Operation), Tr. Phila. Acad. Surg., March 6, 1893.

Ochsner, E. H.: Potential and Acquired Static Flat Foot, Its Etiology, Symptomatology and Non-Operative Treatment, The Journal A. M. A., Nov. 23, 1907.

Osgood, R. B.: Pathologic and Symptomatic Weight-Bearing, a Consideration of the Prevention and Cure of Foot-Strain, Am. Jour. Orthop. Surg., February, 1912.

Peckham, F. E.: Flat Feet, New York Med. Jour., April 10, 1909.

Stevens, W. W.: Cause, Prevention and Care of Weak and Flat Feet, New York Med. Jour., Nov. 9, 1912.

Tracy, E. A.: Important Flat-Foot Facts for Assimilation and Dissemination, Med. Rec., New York, Nov. 7, 1908.

Whitman, Royal: A Consideration of the Causes and Characteristics of Weak-Foot, Med. Rec., New York, Aug. 31, 1907.

Wilson, H. A.: Misapplied Mechanics in the Treatment of Flat Foot, read in the Section on Surgery, Medical Society of State of Pennsylvania, Reading, Sept. 23-26, 1907.

ABSTRACT OF DISCUSSION

Dr. Robert W. Lovett, Boston: I wish to mention some work that I did and recently reported in The Journal, that some of you may have seen, in which I tried to make the

Digitized by Google

point that the word "flat" foot was used too extensively, and that in many cases such feet were not flat. I called attention also to the fact that I personally believe more people have trouble from high arches than from low arches, and that the element of pronation did not come in. Dr. Whitman complimented me by taking issue with me, and held that pronation was a necessary element in painful feet. In the eight hundred cases examined, the ones that were pronated were not any more prone to pain than the ones that were nonpronated, and I personally do not believe that any man living can go through a hundred feet and pick out with any degree of precision the feet that are likely to be enduring under strain and the feet that are likely to give out under strain. Since I have been specially interested in this subject, I have been taking note of the people who come to my office for treatment for static difficulties in the feet. Of course, the causes that Dr. Frauenthal speaks of we have got to recognize definitely, but in regard to static pronation, I personally believe more people have trouble with high arches than with low arches.

Dr. John Ridlon, Chicago: I should like to ask that Dr. Frauenthal in closing explain a little more fully just what this white light is.

Dr. Emil S. Geist, Minneapolis: I feel that a great many cases of so-called weak foot are erroneously diagnosed, and am of the opinion that these cases need as much care in examination and diagnosis as other human ailments receive in our offices. We are prone to dismiss these patients suffering from foot complaints without giving them sufficient thought and attention, prescribing merely an arch support, some exercises, and trusting to luck that they may get better. I believe if we look more at the matter of etiology, we will find that foot complaints can be divided into many classes, and that instead of the ordinary static problems, we will often have to consider many other etiologic factors in arriving at the best method of treatment in these cases of so-called weak foot. Of course, not all infectious arthritides are due to some focus situated in the mouth or its environs. However, we must frequently remove the possible focus, hoping that it may be the one which is giving the trouble. If we do not cause general improvement, we will always cause local improvement at any rate. Another important point to remember is that many of us expect too much from the removal of a possibly diseased focus. We cannot expect a joint which has been riddled by disease for years to recuperate and resume normal function, merely because we have removed an infected tooth, for instance. The fire is over and the damage has been done. We must get on the ground with our fire extinguisher at any early hour and not wait until the fire is over.

Digitized by Google

Dr. Roland Meisenbach, Buffalo: In considering painful feet, we must remember that there are many causes, whether they be due to anatomic variations, static errors, infections, a lack of tone of the tissues, or following fractures in or near the feet, or a combination of the above. Dr. Frauenthal has enumerated many of these in his paper. He has, indeed, covered a vast field, and I am sure he will agree with me that he has only briefly touched on many of them. The successful treatment of painful feet surely depends on our being able to attack the cause as well as the effect. I especially think of the cases in which there may be infection far remote from the feet, that develop painful feet after the severe infection has subsided. I am inclined to believe that some of the local infections of the feet occur through the skin, by absorption. I do not believe it is possible for one to say dogmatically that plates are of no value. I know that there are types of feet that require the proper plates, and that there are other types of painful feet that should not have plates. In considering the question of plates, one should remember that plates are applied to feet for two reasons: First, to support the feet properly and make them functionate correctly, and secondly, to strengthen the foot structures. In order to make the feet functionate properly, the plates must be cut according to the symptoms, as well as to the anatomy of the foot, which are only understood by the surgeon who has studied the case. The plate should be of such flexibility that it will bring into play the very muscles or tissues of the foot and leg which the surgeon believes will strengthen the foot. I find that so many are wearing plates of a rigid type, so as to splint all the joints of the foot as well as actually to prevent muscular action. This is the wrong type of plate, and is found frequently in the shoe stores. Although at first they may give temporary relief, the ultimate result is to weaken rather than strengthen the foot. It should be remembered that plates should be applied only as an adjunct to any other treatment which may be necessary, either general or local. Even in cases in which we have exostoses or faulty function after fracture, plates may be of great value in obtaining the results.

Dr. E. A. Rich, Tacoma, Wash.: I should like to ask Dr. Frauenthal to state in his conclusion the rôle that the ordinary plate plays in his work.

Dr. E. W. Ryerson, Chicago: I am anxious to be convinced of the value of these light treatments. It seems to me, considering the matter from the standpoint of an ordinary, plain thinker, that electric light treatment for these painful osteo-arthritis cases, of which we all see so many instances, is the purest kind of bunk; but if it is true, I want to be convinced, and the recital of a few cases which have been benefited has not particularly convinced me. I

Digitized by Google

should be very glad if Dr. Frauenthal would at some future date—say next year—present to us some really convincing scientific evidence of the value of the light treatment. There are lights and lights, and a whole lot of people are using this light and that light—and a white light is better than a blue light and a blue light is better than a white light, and personally, I don't know where we get off. If there is anything in it, I want to use it, but I have got to be shown.

Dr. John Ridlon, Chicago: What is that lamp called?

Dr. Henry W. Frauenthal, New York: Answering Dr. Ridlon, the light I use in my office is what is known as a lucodescent lamp. What I have my patients use is a small lamp they buy from the Edison Electric Company, costing $8.00. I try to get the patients in some house wired for electric light. The size of the lamp is of no importance, because you heat the feet up to the highest point of tolerance. I think we have a record of over three hundred cases. As a question of diagnosis, a number of these cases I have from time to time shown to Dr. Willy Meyer, who was interested in this particular class of cases. One of the gentlemen asked me what plate we use at the hospital. We don't use any plates. We use firm felt cut out to conform to the foot and elevated to support the arch, because it holds up firmly and is springy. That don't do for static feet. You must manipulate them, and then if you bake them and keep up your massage, some of them get to be fairly good feet. The type of foot that I want to call the attention of the section to are particularly those that are due to secondary infection. In the last year we have observed a great many of them, and our class of women with painful feet is almost as large as our class of men. They get some relief at first by wearing a plate obtained at a drug store or at a shoe store, and then as they don't get any better, they apply to an institution.

Digitized by Google

LYMPHOID MARROW AND TUBERCULOSIS

AN EXPERIMENTAL STUDY *

LEONARD W. ELY, M.D.
SAN FRANCISCO

In a paper read before this section at its meeting in 1914, Mr. John Fraser made the statement that red marrow was immune or practically immune to tuberculosis. This statement was based on the results of attempted inoculation of the long bones of laboratory animals, whose marrow is of the red or lymphoid variety. The question is of great importance, and we have been conducting a series of experiments in the laboratories of the Stanford School of Medicine to test the accuracy of Mr. Fraser's conclusions.

Dr. John F. Cowan and I conducted one series, on which we shall report later. Dr. Jean Oliver and I conducted another series which I shall report here.[1]

The animals used were rabbits and guinea-pigs. With the former, bovine tubercle bacilli were employed (Cutter Laboratory bovine strain, K 9), with the latter, human bacilli from a virulent strain supplied by Dr. Hirschfelder. The animals were anesthetized with ether, and the limb to be operated was shaved. Strict asepsis was observed, a small incision was made in the leg, a trephine opening was made into the tibia, and with a hypodermic needle a few drops of a suspension of bacilli in normal salt solution were injected directly into the marrow. The wound was then sewed up with catgut and was painted with collodion.

* From the Leland Stanford Jr. University Laboratory of Surgical Pathology.

1. After the main question of the vulnerability of the marrow had been determined, the work was divided. Dr. Oliver continued his investigation on the histologic features of the tubercle.

Digitized by Google

At varying intervals before the operation and sometimes after it, a 1 per cent. solution of trypan blue was injected into the animals, 20 c.c. into the ear vein of the rabbits, 2 c.c. subcutaneously into the guinea-pigs. The animals were killed at varying intervals after the operation.

Our intention was usually to inject into the metaphysis of one tibia and into the central canal of the other, but in point of fact the canal extends so high in the tibia that practically all injections were into it.

The specimens were hardened in 10 per cent. formaldehyd solution or in alcohol, dehydrated in alcohol, mounted in paraffin, and stained with hematoxylin and eosin, with the Van Gieson stain, and for tubercle bacilli with the Ziehl stain.

A complete description of the findings is appended. The results will be summed up here.

EXPERIMENTS ON RABBITS

Rabbit 41 0: Killed fifty-one days after injection. Right tibia, tuberculosis present macroscopically and microscopically. No tubercle bacilli found. Left tibia kept for gross demonstration. Tuberculosis demonstrated macroscopically in it.

Rabbit 42 0: Killed forty days after injection. Both right and left tibias showed tuberculosis and tubercle bacilli present.

Rabbit 43 0: Killed fifty-four days after injection; blocks lost.

Rabbit 44: Killed on day of operation. Right and left tibias showed neither tuberculosis nor tubercle bacilli.

Rabbit 45: Killed thirty-three days after operation. Both right and left tibias showed tuberculosis macroscopically and microscopically, but no tubercle bacilli in either.

Rabbit 46: Killed thirty-two days after operation. Both right and left tibias showed tuberculosis macroscopically and microscopically; tubercle bacilli in neither.

Rabbit 47: Killed thirty days after operation. Both right and left tibias showed tuberculosis macroscopically and microscopically; tubercle bacilli were found in the right, none in the left.

Rabbit 49: Killed one day after operation. Right and left tibias showed neither tuberculosis nor tubercle bacilli.

Rabbit 75: Killed two days after operation. Right and left tibias showed no sign of tuberculosis or tubercle bacilli.

Digitized by Google

Rabbit 76: Killed seven days after operation. Both tibias showed neither tuberculosis nor tubercle bacilli.

Rabbit 77: Died fifteen days after operation. Both tibias showed neither tuberculosis nor tubercle bacilli.

Rabbit 78: Killed twelve days after operation. Right tibia showed tuberculosis microscopically and a few tubercle bacilli.

Omitting Rabbit 43 0 whose marrow specimens were lost, we have here 11 rabbits. In 6 tuberculosis was demonstrated, in 5 it was not. The 5 in which it was absent were killed respectively the day of operation, and one, two, seven, and fifteen days after operation. All animals killed after a greater interval than fifteen days, and one after an interval of twelve days showed distinct marrow tuberculosis. In other words, in every animal allowed to live over one week, save one, tuberculosis was demonstrated.

Tubercle bacilli were recovered from both tibias of Rabbit 42 0 (forty days), from the right tibia of Rabbit 47 (thirty days), and from the only operated tibia in Rabbit 78 (twelve days).

Others have noted the difficulty of recovering bovine tubercle bacilli from the marrow. In two tibias of our series they could be found only by diligent search. Typical giant cells are rare. Friedrich[2] made this observation.

The "fibromyxomatous" marrow described by Fraser is a practically constant phenomenon in the neighborhood of the tuberculous marrow, but is not peculiar to tuberculosis. It is probably present in most slow marrow inflammations, and we regard it as Nature's protective reaction against the spread of infection, not as a mysterious change which the marrow undergoes before it can be invaded, and when tuberculosis is in the neighborhood.

Another very suggestive fact that we (Dr. Cowan and I) have observed in another series of experiments (not tuberculosis experiments) on rabbits' cartilages, is the presence of a thin strip of fatty marrow

2. Friedrich: Deutsch. Ztschr. f. Chir., 1899, liii, 532.

Digitized by Google

which frequently is present near the circumference of the end of the femur (that is, close to the attachment of the capsule). We believe this band of yellow marrow is responsible for Fraser's contention that the lymphoid marrow of the bone end must change to fatty marrow before it can be invaded by tuberculosis from the synovial membrane.

Conclusion: The lymphoid marrow of rabbits' bones is a good field for the growth of bovine tubercle bacilli.

EXPERIMENTS ON GUINEA-PIGS

Six guinea-pigs were employed, and were killed or died, respectively, four, six, six, nine, ten and fifteen days after operation. All showed tuberculosis of the marrow, and in all tubercle bacilli were demonstrated.

Conclusion: The lymphoid marrow of guinea-pigs' bones is a good field for the growth of human tubercle bacilli.

It is now five years since the theory was first published that the location of tuberculosis in bone was determined by the presence of red or lymphoid marrow. I should like at this time to sum up the evidence to date:

1. Tuberculosis is found only in those bones or regions of bone where lymphoid marrow is present.

2. Marrow tuberculosis is more common in children, whose bones contain more red marrow. As age advances, marrow tuberculosis becomes rarer and less destructive.

3. After resections in adults, if secondary infection be avoided, the disease disappears. The best authority available says that after resections the lymphoid marrow disappears.

4. Experiments show that lymphoid marrow is an excellent field for the growth of tuberculosis.

Two links are missing in the chain of evidence; that is, the demonstration of the particular cells in the lymphoid marrow which are responsible for the

Digitized by Google

disease there, and the proof that tubercle bacilli will not grow in yellow or fatty marrow. It will be instructive also to learn the exact morphologic changes which take place in the marrow after a resection.

Lane Hospital.

PROTOCOLS OF ANIMAL EXPERIMENTS

Rabbit 41 0, July 29, 1914: Twenty c.c. of trypan blue were injected by Dr. Oliver into the ear vein of the rabbit (a rather young one). Today the usual preparation and operation. Operator, Cowan; assistant, Ely.

A small trephine opening was made into the upper end of the right tibial shaft, and another into the shaft of the left tibia. Through these openings a suspension of tubercle bacilli (Cutter bovine K 9) was injected. The wound was sewed up with catgut and collodion applied.

Aug. 19, 1914: Fifteen c.c. of trypan blue were injected by Dr. Oliver into the ear vein.

Sept. 16, 1914: Twenty c.c. of trypan blue were injected by Dr. Oliver into the ear vein.

Sept. 18, 1914: The rabbit was killed by a blow on the back of the neck.

Necropsy: Right leg, wound healed completely. Skin was removed. A small gelatinous mass was found at the site of operation in the bone. The joint was normal. Bone sawed longitudinally showed marked marrow changes. Left leg, wound healed completely. A small gelatinous mass found over site of operation in bone. Bone sawed longitudinally. Practically the entire marrow of the central canal is involved.

Microscopic Examination: Right tibia, the section includes about one fourth of the upper end of the tibia. On the shaft side of the epiphyseal line a large tubercle fills the space between the layers of the cortical bone. This tubercle is largely necrotic. In the periphery of this necrotic area is an area characterized by the presence of endothelial leukocytes and lymphocytes. Outside of this again, above and below the infected area, the marrow is "fibromyxomatous." In other words, the tubercle is surrounded by fibromyxomatous marrow. No giant cells can be seen. The old morbid process ends shortly before reaching the epiphyseal line. Small tubercles can be seen in the stage of formation. No tubercle bacilli found.

Left tibia, well-marked marrow involvement. Specimen kept for gross demonstration.

Rabbit 42 0, July 29, 1914: About 20 c.c. of trypan blue were injected into the ear vein yesterday by Dr. Oliver. Operation as on rabbit 41 0 (Cowan).

Digitized by Google

August 19: Twenty c.c. of trypan blue were injected by Dr. Oliver into the ear vein.

September 7: Rabbit apparently in health, was killed by blow on the back of the neck. Wound was healed completely. In the right leg is a semifluctuating mass, gelatinous in consistency, about 2 c.c. in diameter, lying over the trephine opening in the bone. No sinus formation. Skin removed over it. Mass apparently has emerged from the trephine opening in the tibia. Left leg, operation wound healed. No sinus. Semifluctuating mass over upper part of medial aspect of tibia not communicating with the skin. Blood vessels above the mass are congested. Mass proceeds from trephine opening in the tibia. Joint normal. Bone removed. Upper part of medullary canal is filled with a gelatinous material which is stained a light diffuse blue. The rabbit has tuberculosis of the liver, lungs, kidneys and spleen.

Microscopic Examination: Left tibia shows diffuse tuberculosis, and discrete tubercles with areas of necrosis and occasionally a typical giant cell. "Fibromyxomatous" marrow in a general way surrounds the tuberculous areas, and divides them from the normal marrow. Tubercle bacilli are present, but in very small numbers, and are only to be discovered by careful search. Right tibia section includes an area of lymphoid marrow, and one or more of "fibromyxomatous" marrow, containing several small young tubercles, one of them with a small area of necrosis at its center. No giant cells. Tubercle bacilli are present in moderate numbers, especially in and about the areas of necrosis. Apparently some of them are in the endothelial leukocytes.

Rabbit 43 0, July 29, 1914: Into an ear vein of this rabbit, a young one, Dr. Oliver injected yesterday about 20 c.c. of trypan blue. Today the usual preparation and operation. A few drops of a suspension of tubercle bacilli were injected also into the peritoneal cavity. After the operation a smear of the suspension was made, and tubercle bacilli were found in it.

Aug. 19, 1914: About 20 c.c. of trypan blue were injected into the ear vein by Dr. Oliver.

Sept. 21, 1914: Ten c.c. of trypan blue were injected into the ear vein and the animal killed a few hours afterward. Right leg, wound healed; small amount of jelly-like infiltration over site of operation in bone. Very little gross evidence of tuberculosis. Left leg, old fracture of tibia, fairly firmly united. Line of fracture runs from site of trephine opening downward and outward. Considerable gelatinous infiltration over trephine opening. Gross tuberculosis at and below fracture. Tuberculosis of lungs, liver and kidneys.

No microscopical examination was made; the blocks were lost.

Digitized by Google

Rabbit 44, Aug. 3, 1914: Into the ear vein of a young rabbit, 20 c.c. of trypan blue were injected at 11 a. m. by Dr. Oliver. Operation several hours later. Usual preparation and operation (Ely). Animal killed at 9 p. m. that day. The marrow of both tibias is engorged with blood, but presents no evidence of tuberculosis. No tubercle bacilli could be demonstrated in it.

Rabbit 45, Aug. 3, 1914: This was a young animal. Into its ear vein twenty c.c. of trypan blue were injected by Dr. Oliver this morning at 11. Usual preparation and operation (Cowan).

Aug. 19, 1914: Twenty c.c. of trypan blue were injected by Dr. Oliver into the ear vein.

Sept. 5, 1914: Animal killed. Right leg, wound completely healed. Skin removed. A dirty, gelatinous mass under skin about 3 by 2 cm. and about 4 mm. in thickness running under skin, apparently proceeding from the wound in the bone. The veins about this area are injected. The mass on dissection is found to proceed from the wound in the bone. Section of bone longitudinally, through the trephine openings, reveals a large tubercle (juxta-epiphyseal) about 3 mm. in diameter, stained deep blue in contrast to the red marrow. Left leg shows a small, sluggish ulceration on the front of the tibia, and under it is a small gelatinous semifluctuating mass over the site of operation on the bone. The mass on dissection appears to proceed from operation wound in tibia. Longitudinal section of bone shows a gelatinous mass about 2 cm. long, filling the marrow canal at seat of operation.

Necropsy shows apparent tuberculosis of lungs and kidneys.

Microscopic Examination: Right tibia, a juxta-epiphyseal macroscopic tubercle almost fills the space between the two layers of cortical bone, and about this the marrow is fibrous —"fibromyxomatous." The tubercle is about at the site of the injection, and shows well-marked areas of necrosis. Endothelial leukocytes and lymphocytes are seen in it in abundance. No giant cells. No tubercle bacilli.

Marrow section near metaphysis: The marrow in places is the seat of intense cellular infiltration, chiefly by endothelial leukocytes and lymphocytes. This infiltration takes the form, in places, of microscopic tubercles. Cellular necrosis is beginning. One or two fairly typical giant cells may be recognized. In the neighborhood of the cellular infiltration the marrow has become fibrous—"myxomatous marrow." No tubercle bacilli found. Left tibia, the marrow shows new tubercle formation. In places it is packed with marrow cells, in other places it shows the development of new connective tissue. The blood vessels have thickened walls. A small collection of fibrin is seen. No giant cells; no tubercle bacilli.

Digitized by Google

Rabbit 46, Aug. 3, 1914: Into the ear vein of a young rabbit, 20 c.c. of trypan blue were injected this morning at 11 by Dr. Oliver. Today usual preparation and operation (Cowan).

Aug. 19, 1914: Twenty c.c. trypan blue injected into ear vein by Dr. Oliver.

Sept. 4, 1914: Rabbit killed by blow on back of neck. Right leg, a soft, semifluctuating mass about 1 cm. in diameter can be felt beneath the skin on the medial aspect of the head of the tibia, and a dirty sinus is present about 1 cm. laterally and below this. The knee joint is freely movable and apparently normal. Skin slit up over mass. The mass was dissected out very carefully, 1 cm. long, 1 cm. wide at end, 2 cm. at base. It is of a gelatinous character. Terminal portion put in 10 per cent. formaldehyd solution. The joint was opened and found normal. The mass is very intimately connected with the periosteum. Bone sawed longitudinally through trephine opening. The upper part of the shaft is filled with a deep blue gelatinous mass about 1.5 by 0.5 cm. The bone marrow below this mass is red and apparently normal. Left leg, a large, semifluctuating swelling about 3 cm. in diameter is present on medial and posterior aspect of the tibia, and over its lower portion is a dirty, sluggish ulceration 1 cm. in diameter. Skin slit up over swelling, and careful dissection of gelatinous mass made; it appears to be intimately connected with the tendon sheaths and some of the muscle, and appears to spring from the trephine opening of the bone. Mass was removed and placed in 10 per cent. formaldehyd solution. Bone sawed longitudinally through trephine opening. The entire medulla below the trephine opening and 1 cm. above is filled with a blue, gelatinous material. Above, the bone marrow is dark red and apparently normal. Tuberculosis of lungs, liver and kidney.

Microscopic Examination: Left tibia, under low power tubercles can be seen. About some of them the marrow is undergoing a fibrous change ("fibromyxomatous" marrow). In some of the tubercles necrosis has begun. The inflammatory process appears not only in more or less discrete tubercles, but also in a more diffuse infiltration. No typical giant cells, but numbers of what appear to be giant cells in the process of formation. No tubercle bacilli. Right tibia, the marrow is that of the central canal. A few isolated young tubercles are seen, and about them the marrow is fibrous. No necrosis. A couple of young giant cells. No tubercle bacilli.

Rabbit 47, Aug. 3, 1914: Into the ear vein of this young rabbit, 20 c.c. of trypan blue were injected this morning at 11 by Dr. Oliver. Today usual preparation and operation (Cowan).

Digitized by Google

Sept. 2, 1914: Rabbit killed by blow on neck. Over anterior and medial aspect of right tibia is a small fluctuating swelling 1 cm. in diameter, and laterally to this swelling is a small sinus discharging a little purulent fluid. The joint is not involved and is freely movable. The swelling was opened, and contains a firm jelly-like material, which does not break up. Swelling removed and placed in 10 per cent. formaldehyd solution. Many just visible greyish nodules in the mass. The operative opening in bone lies immediately below the mass. Bone was sawed longitudinally. Just below the spongy bone of the head of the bone is a jelly-like, yellowish-blue mass which completely fills the upper medullary cavity. This extends through the opening of the bone. Fixed in 10 per cent. formaldehyd solution. In the shaft of the left tibia (medial aspect) there is a dirty looking sinus about 5 mm. in diameter with elevated borders, which communicates with a semifluctuating mass over the operative opening in the bone, and this mass apparently communicates with the opening in the bone. Bone sawed longitudinally. The entire medullary cavity for a distance of 1 cm. on each side of the opening is filled with a bluish-yellow jelly-like substance. Above and below this fairly well-defined mass, the red bone marrow is apparently normal. Fixed in 10 per cent. formaldehyd solution.

Liver, kidney and spleen are filled with bluish tubercles. Lungs apparently normal.

Microscopic Examination: The section of the right tibia includes an area of apparently normal marrow, and one of well-marked tuberculosis. The zone of their junction is very instructive: A few, small tuberculous areas can be seen in the marrow, at a distance from the main tuberculous mass. No effort at encapsulation is manifest. Endothelial leukocytes are present in great numbers. Degeneration of the tuberculous areas is well advanced; and in one or two small areas, necrosis is present. No giant cells. Tubercle bacilli are present in very small numbers. Here and there an occasional bacillus can be discovered by diligent search. They are slightly curved. The slide from the left tibia includes an area of "fibromyxomatous" marrow, and one of lymphoid, in both of which are well-marked tubercles. One enormous giant cell is seen in the immediate neighborhood of a tubercle in the former. In one slide a tubercle is seen close to a small arteriole. No tubercle bacilli found.

Rabbit 49, Aug. 7, 1914: Into the ear vein of this young rabbit, 20 c.c. of trypan blue were injected this morning at 9:30 by Dr. Oliver. Usual preparation and operation.

Aug. 8, 1914: Rabbit killed this morning by Dr. Oliver. No tubercle bacilli found.

Microscopic Examination: The marrow from Leg 1 on the slide looks normal; it presents no sign of injury. No

Digitized by Google

tuberculosis. No tubercle bacilli. Other marrow slides show hemorrhage in the marrow. No tuberculosis. No tubercle bacilli. Lymphoid marrow from Leg 2 is hemorrhagic. No tuberculosis; no tubercle bacilli. Other slides show lymphoid marrow hemorrhagic in places. No tuberculosis; no tubercle bacilli.

Rabbit 75, Sept. 8, 1914: Into the ear vein of this young rabbit, 20 c.c. of trypan blue were injected by Dr. Oliver.

September 9: Usual preparation and operation.

September 11: Rabbit killed. No visible reaction in soft parts over operation wound in either leg.

Microscopic Examination: Set 1, lymphoid marrow shows no sign of tuberculosis or of tubercle bacilli. Set 2 shows no sign of tuberculosis but hemorrhage into the marrow. Possibly a greater number of endothelial leukocytes than normal. No tubercle bacilli.

Rabbit 76, Sept. 8, 1914: Into the ear vein of this young rabbit, 20 c.c. of trypan blue were injected by Dr. Oliver.

Sept. 9, 1914: Usual preparation and operation.

Sept. 16, 1914: Rabbit killed by blow on back of neck. Right leg shows wound scabbed over. Skin removed. Slight swelling over trephine opening. Left leg shows wound scabbed over and also a slight thickening.

Microscopic Examination: The marrow is hemorrhagic. At one place is a small wedge of fibrous tissue in the marrow, and in this the marrow cells and blood cells can be distinguished. No necrosis. No sign of tuberculosis. No tubercle bacilli seen. In another series of slides appears a small area of fibrin in the marrow. No tuberculosis in these.

Rabbit 77, Sept. 8, 1914: In the ear vein of this young rabbit, 20 c.c. of trypan blue were injected by Dr. Oliver.

Sept. 9, 1914: Usual preparation and operation.

Sept. 23, 1914: Twenty c.c. of trypan blue into ear vein.

Sept. 24, 1914: Rabbit died last night.

Necropsy: Cause of death not determined. No gross lesion of tuberculosis found in viscera. Both wounds on leg healed completely. Over the trephine openings were the usual small collections of gelatinous material. These collections have no connection with the surface. They do not arise, in other words, from a superficial infection. Bone slit up showed no gross evidences of tuberculosis in the bone marrow.

Microscopic Examination: Set 1: The marrow is lymphoid, and appears normal. No tuberculosis; no tubercle bacilli. Set 2: Lymphoid marrow, engorged. No tuberculosis. Set 3: Lymphoid marrow, engorged. No tuberculosis; no tubercle bacilli.

Rabbit 78, Sept. 8, 1914: Into the ear vein of this young rabbit, 20 c.c. of trypan blue were injected by Dr. Oliver.

Digitized by Google

Sept. 9, 1914: Usual preparation, and operation on right tibia only.

Sept. 21: Effort to inject ear veins unsuccessful. Five c.c. of trypan blue injected in peritoneal cavity. Killed about one-half hour later. Some subcutaneous evidences of hemorrhage are present. Tibia removed; sawed longitudinally. The upper portion of the marrow is of the usual red variety; the lower third is pale. Necropsy reveals a few scattered nodules in the liver. The trypan blue had been injected into the abdominal wall, not the peritoneal cavity.

Microscopic Examination: Very small tubercles are seen in the early stages of formation. The marrow is lymphoid with some "fibromyxomatous" marrow, especially about the tubercles. In the tubercles a few tubercle bacilli can be made out.

Guinea-Pig 8, November 17: Injection of 2 c.c. of trypan blue subcutaneously.

November 18: Operation. Trephine opening on medial aspect of right tibia. Through this a few drops of a suspension of human tubercle bacilli in salt solution were injected into the marrow canal, and the wound sewed up with catgut. Collodion applied.

November 19: Reinjected with trypan blue.

November 21: Reinjected. The knee is drawn up, and is greatly swollen. Guinea-pig killed one-half hour after injection by blow on back of neck. Wound evidently healing well, no discharge. Tissues succulent, lymph nodes in groin enlarged. The deformity in the leg is due to the separation of the upper epiphysis of the tibia. The small trephine opening can be identified. Tibia split. Marrow pale and yellowish in lower one third of tibia. In the center there is a small blue area under opening, and above it is a zone of red marrow in which is a larger blue area. The injection through the trephine opening had been made upward and downward into the marrow canal. The other tibia when opened was found to contain red marrow.

Microscopic Examination: The slide contains an area of lymphoid marrow, and one of clot-fibrin with blood cells and a few masses of detritus. In the former are several small aggregations of lymphoid and endothelial leukocytes, very young tubercles, and a fairly large number of very small collections of endothelial leukocytes, looking like the very earliest stages of typical giant cells. (Occasionally one sees also the regular megaloblasts of marrow.) In the lymphoid marrow, near its junction with the clot, are tubercle bacilli, in so great numbers that they can be located by the low power. Many are intracellular. In some instances cells can be seen packed with them.

Guinea-Pig 9, November 17: Injection of 2 c.c. of trypan blue subcutaneously.

Digitized by Google

November 18: Usual operation, as in Guinea-Pig 8.

November 19: Reinjected.

November 21: Reinjected.

November 23: Reinjected.

November 24: Found dead. Wound healing. Tibia in dissection broke loose in upper epiphyseal line. Marrow deeply stained, more in some places than in others. Lymph nodes in groin enlarged. No tuberculosis of internal organs.

Microscopic Examination: Endothelial leukocytes are seen in very great numbers, some of them enclosing granules of blood pigment. No discrete tubercles; but in places a diffuse tuberculous infiltration. No typical giant cells. A few tubercle bacilli can be made out by careful search. Other sections show diffuse tuberculosis. Endothelial leukocytes in great numbers. No discrete tubercles but evidences of degeneration. Many cells stain poorly, and their nuclei have lost their sharp outline. No typical giant cells, but often a number of endothelial leukocytes have collected, as if in the process of forming giant cells. By Ziehl stain red granules are seen in some of the endothelial leukocytes. A few bacilli found after a long search, intracellular. Other slides show vascular spaces engorged and many endothelial leukocytes. Tubercle bacilli in enormous numbers can be located with the low-power objective. Apparently they are intracellular, and in many instances are in endothelial leukocytes.

Guinea-Pig 10, November 17: Injection of 2 c.c. of trypan blue subcutaneously.

November 18: Usual preparation and operation.

November 19: Reinjected.

November 21: Reinjected.

November 23: Reinjected.

November 27: Found dead. Normal healing, no sign of infection. Tibia in dissection broke at lower epiphysis. Marrow deep red, with blue area below trephine opening. Lymph nodes in groin enlarged. No tuberculosis of internal organs.

Microscopic Examination: No distinct tubercle formation, but here and there the assembling of endothelial leukocytes has begun in patches. By Ziehl stain here and there is seen a large pale cell with one nucleus or two nuclei, which contain pigment granules. After a long search two or three similar cells, identified as endothelial leukocytes, were seen enclosing tubercle bacilli, one of them enclosing a great number in a clump. No typical giant cells. Other slides show countless endothelial leukocytes in the marrow, and tubercle formation has begun. Most of the marrow on the slide is tuberculous. Tubercle bacilli can be located by the low (Zeiss A). They are in great numbers, and some of them seem to be intracellular. No typical giant cells.

Digitized by Google

Guinea-Pig 11, November 17: Injection of 2 c.c. trypan blue subcutaneously.

November 18: Usual preparation, and operation.

November 19: Reinjected.

November 21: Reinjected.

November 23: Reinjected.

November 27: Reinjected.

December 2: Healing with little reaction. Deep blue staining area beneath trephine opening, and deep red marrow, slightly bluish, on both sides. No tuberculosis of internal organs. Pneumonia?

Microscopic Examination: Well-marked marrow tuberculosis. Endothelial leukocytes dominate the picture. No discrete tubercles, but a diffuse tuberculous infiltration. No giant cells. Ziehl stain shows pigment granules as observed in Pig 10. In some of the tuberculous areas tubercle bacilli, apparently intracellular, are seen in moderate numbers. Other slides show engorgement of marrow. Small areas of beginning necrosis. Possibly not so great a number of endothelial leukocytes as in the first set, but very many. No giant cells. Well-marked tuberculosis. Tubercle bacilli in great numbers, intracellular, some of them in endothelial leukocytes. Still other slides show beginning tubercle formation by endothelial leukocytes, and lymphocytes (fewer in number), easily discernible by low power. No typical giant cells. Ziehl stain shows pigment granules as above in endothelial leukocytes. In a number of cells a bacillus and granules were seen.

Guinea-Pig 12, November 17: Injection of 2 c.c. of trypan blue subcutaneously.

November 18: Usual preparation and operation.

November 19: Reinjected.

November 23: Reinjected.

November 27: Reinjected.

November 28: Found dead. Wound healing well; little local reaction. In dissection the lower epiphysis separated and the upper also. Blue area in marrow at seat of injection, otherwise marrow apparently normal.

Microscopic Examination: This is the first guinea-pig examined. An immediate difference from those of rabbits is noticed in these slides. The marrow on superficial examination under the low power appears normal except that it is engorged and densely packed with cells. Under the high power the excess of cells is seen to consist of endothelial leukocytes. There is no suggestion of tubercle formation. Frequently a number of the endothelial leukocytes are grouped, apparently to form a giant cell. The formation of giant cells is well seen in the slide. Engorged blood vessels are everywhere. No megakaryocytes are seen.

Digitized by Google

Guinea-Pig 13, November 17: Injection of 2 c.c. carmine subcutaneously.

November 18: Usual preparation and operation.

November 19: Reinjected.

November 23: Reinjected.

November 24: Found dead, stiff. Evidently an old animal. Wound appears normal. Lymph nodes in groin enlarged. Bones seem unusually dense, part of marrow seems to be yellow. No tuberculosis of internal organs. Two lymph nodes and marrow put into formaldehyd solution. Lymph nodes show no definite tuberculosis, but a moderate infiltration by endothelial leukocytes. No tubercle bacilli, but many of the cells contain pigment granules.

More slides, Set 1, show patches of endothelial cells, many of them necrotic, as the chief noteworthy characteristic. The nuclei stain poorly or not at all. Frequently a necrotic myeloplax can be seen. Early tuberculosis. Here and there a few intracellular tubercle bacilli are seen, but the cells containing them are necrotic, and cannot be identified. Set 2 shows a patch of engorged lymphoid marrow, and one of early tuberculous marrow with well-marked cellular necrosis. Intracellular tubercle bacilli in moderate numbers are present in the latter area, sometimes a group in a cell. Set 3 show engorged lymphoid marrow. No tuberculosis. No bacilli.

ABSTRACT OF DISCUSSION

Dr. John F. Cowan, San Francisco: What Dr. Ely has said on the question of marrow tuberculosis is exceedingly interesting, in view of the paper which was presented to this section at its meeting in Atlantic City last year by Mr. John Frazer of Edinburgh. It is said that it is very difficult, and in many cases, impossible to infect healthy marrow with tubercle bacilli; that in order for the marrow to become a fertile field for the growth and development of tubercle bacilli, it is necessary for it to undergo certain changes, which he describes as a colloid degeneration, or a fibromyxomatous change; that these changes in the marrow are due to an obliterating endarteritis, resulting from a tuberculous toxemia arising from a tuberculous process in some other portion of the body. Now we do not find in uncomplicated cases of tuberculosis much toxemia. Tuberculous toxins cause lesions locally; that is, in their immediate presence; not at a distance by diffusion of the toxins. At least, the kidneys never show any effect which could be ascribed to the elimination of a tuberculous toxin through them. In these experimental animals we do not find evidence of tuberculosis in other parts of the body. Postmortem examination shows tuberculosis of the marrow, but no tuberculous lesions in the lungs, lymph nodes, etc., so that it is difficult to ascribe the local vascular changes to a gen-

Digitized by Google

eral toxemia. Arterial degeneration is not found as a frequent condition in tuberculosis. In fact, in advanced cases of tuberculosis, instead of finding arteriosclerosis, there is an atrophy of the vessels, as there is an atrophy of the other tissues of the body. However, there are changes in the vessels in the immediate vicinity of the tuberculous process, but these are not due to a general toxemia, but rather to the local chronic inflammation. In tuberculosis we do not find necrosis as an early factor. One may see endothelial leukocytes filled with tubercle bacilli and yet one may not find any degenerative changes in these cells. I have had the privilege of examining Dr. Ely's specimens. In some of them characteristic tubercles are seen, but with slight or no evidence of changes in the blood vessels; and this absence of an obliterating endarteritis is probably due to the fact that these animals were killed at short periods after inoculation. It seems highly probable that the bone marrow of the experimental animals may be primarily infected by tubercle bacilli.

Digitized by Google

THE ROENTGENOGRAPHIC APPEARANCES IN RICKETS

WITH A COMMENT ON DIFFERENTIAL DIAGNOSIS *

ROBERT W. LOVETT, M.D.
BOSTON

During the past winter between 6,000 and 7,000 roentgenograms from the records of the Children's Hospital were examined for the purpose of selecting from among them the plates of rickets, of which there were found between 500 and 600. These were set apart for a study, which forms the basis of this paper. This ratio of 10 per cent. of rickets in the cases requiring roentgenographic study in the varied clinics of a children's hospital is of interest. The plates of the general group covered cases of all types of trauma, congenital bone malformations, tuberculosis, scoliosis, osteomyelitis, empyema, scorbutus, osteomalacia, chondrodystrophia and syphilis.

The plates of rickets were then carefully gone over several times from two points of view, (1) to establish and classify the roentgen appearances of the acute, subacute and convalescent phases of the affection, and to define the finer bone changes associated with the disease, and (2) to determine definitely those points in differential diagnosis by which rickets might be distinguished from such diseases as osteomalacia, scurvy, congenital syphilis and similar affections.

The research was originally undertaken to see if it was possible to determine from roentgenograms when the rachitic process had subsided sufficiently to make operative interference advisable in cases of knock knee

* From the Orthopedic Clinic of the Children's Hospital.

Digitized by Google

and bow leg. Experience had shown that such a determination by age limit was unsatisfactory, because even when children are 4 and 5 years old, one sometimes encounters soft bone offering little resistance to the osteotome, and in these cases profuse bleeding often results, suggesting that the rachitic process is still active.

The study of the plates, however, proved so interesting with regard to the broader aspects of the disease that the inquiry enlarged itself into a comprehensive investigation of the Roentgen-ray phenomena of the disease in general. A review of the literature proved that apparently such a survey was covering practically new territory.

Fränkel and Lory[1] have contributed interesting material from which a Roentgen diagnosis of typical deformities can be made, but the finer aspects as to differential diagnosis are not given, nor is there any attempt to trace the stages of the disease through a definite Roentgen sequence.

Von Recklinhausen's[2] study of pathology adds certain substantiating data to the roentgenologic evidences of the disease. Koch's[3] work from the experimental biologic aspect of etiology is familiar in the recent current literature on the subject.

There have been numerous French articles[4] dealing with the relation of rickets and syphilis, but as the literature in general does not bear directly on the aspect of the question under consideration, this paper will consist almost wholly of my own observations and conclusions.

On a comparative study of the plates, the disease divided itself naturally into three stages, stages in which the separation must of course be to some

1. Fränkel, Eugen, and Lorey, Alexander: Die Rachitis im Roentgenbild, 1910.

2. Von Recklinhausen: Rachitis and Osteomalacia, 1910.

3. Koch, J.: Ueber Experimentelle Rachitis, Berl. klin. Wchnschr., 1914.

4. Dufour, H., and Huber, J.: Syphilis et rachitism, Ann. de méd. et chir. inf., xiv, 702. Kassowitz, M.: Ueber Rachitis, II, Osteochondritis rachitica, Jahrb. f. Kinderh., 1912, lxxv, 194, 334, 489, 581.

Digitized by Google

Fig. 1.—Acute rickets. First stage: indistinct epiphyses, periosteal thickening, fractures.

Fig. 2.—Knee in acute rickets, showing indistinct epiphyses and ragged diaphyseal ends with blocking off of lower end of shaft.

Digitized by Google

Fig. 3.—Second stage: epiphyses more ossified, ends of bones broadening, more marked on the side on which the strain is greater.

Digitized by Google

Fig. 4.—Second stage of rickets, showing returning ossification. Note "white line" at ends of diaphyses described as characteristic of scurvy; chambering of lower part of femur.

Digitized by Google

Fig. 5.—Third stage of rickets: clear and ossified epiphyses, curved bones with compensatory thickening on concave side of curve, broadened ends of shaft at epiphyseal line, increased density of bone.

Digitized by Google

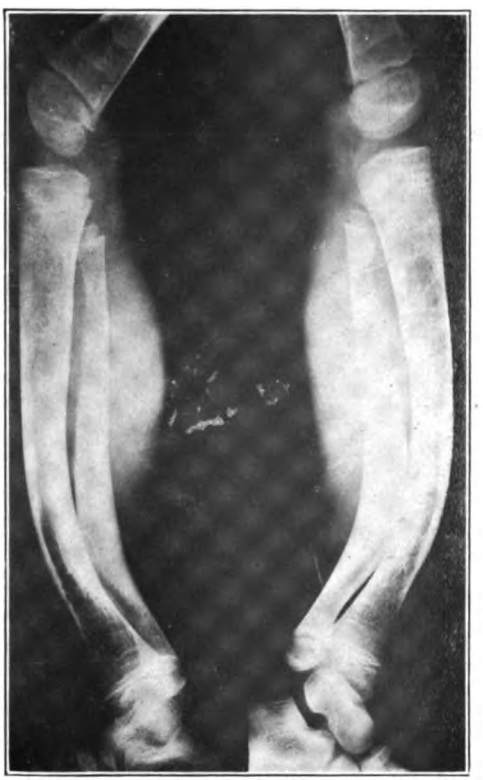

Fig. 6.—Side view of anterior tibial curve due to rickets; thickening is on concave side of curve.

Digitized by Google

Fig. 7.—Side view of anterior tibial curve due to syphilis; thickening is on convex side of curve.

Digitized by Google

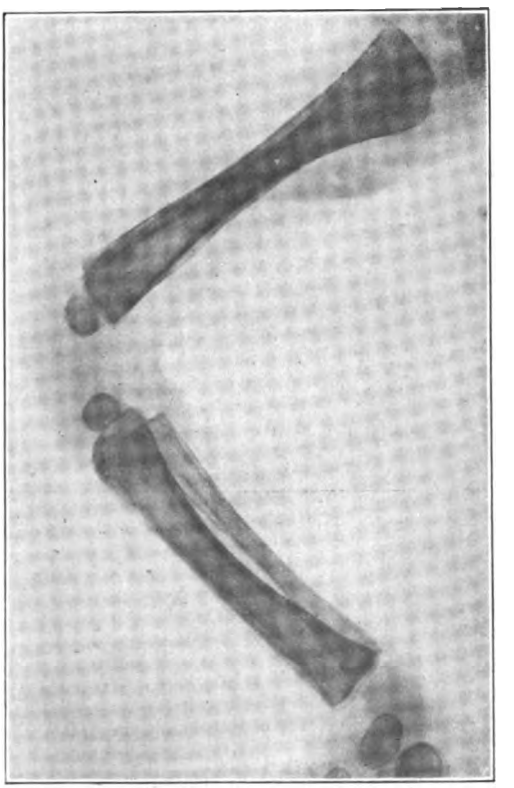

Fig. 8.—Side view of leg bones in congenital syphilis, showing periosteal thickening, but distinct epiphyses. (After Fraenkel.)

Fig. 9.—Osteogenesis imperfecta. Hereditary case under observation nine years.

Digitized by Google

Fig. 10.- Chondrodystrophia foetalis. Broadening of ends of shaft, but distinct epiphyses.

Fig. 11.--Osteomalacia, showing absence of disturbance in epiphyses or epiphyseal region.

Digitized by Google

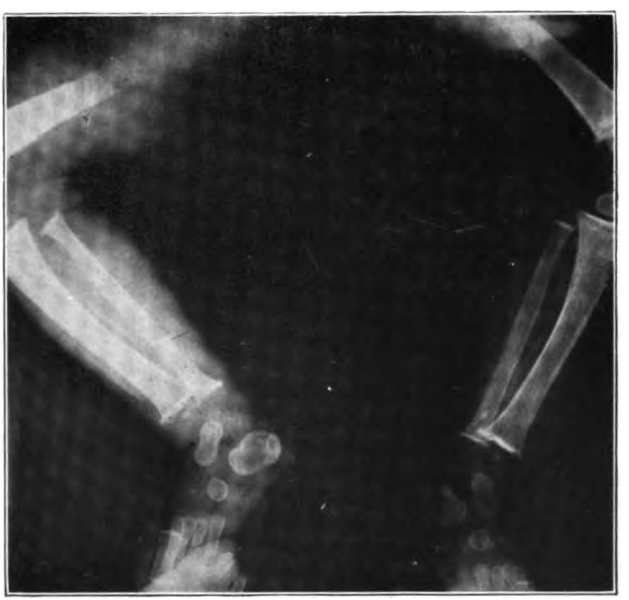

Fig. 12.—Scurvy, showing bone atrophy, "white line" and periosteal disturbances in shaft, but no trouble in epiphyseal regions.

Digitized by Google

Digitized by Google

extent arbitrary, but which, on the whole, are distinct. These apparently correspond to three stages based on anatomic pathologic data advocated by Guérin and Monti[5] as the stages of swelling and rarefaction, deformity and organization, healing and reparative eburnation.

For this investigation, the knee was chosen as the most favorable joint for study. The manifestations, however, are similar in other joints.

FIRST STAGE

In the first stage there are two types, which differ in severity. This stage is the early period of the disease, the period of onset and acute metabolic disturbance. In the *milder* type, the ends of the diaphysis become frayed out instead of clear cut, and the epiphysis casts little or no shadow, while the center of ossification is small or absent, and at times appears multiple. The whole joint is surrounded by a hazy cloud, and the diaphysis on the whole contains less lime than normal. This is very marked in the juxta-epiphyseal region. Up to this point deformities have not begun.

In the *severer* type of the first stage, the epiphyseal appearances are similar, but more marked. In the diaphysis, severe general bone atrophy exists, and there is pronounced periosteal thickening, associated as a rule with fracture of the bones, most often in the arms. These cases of multiple fracture are very common, and are frequently classed as osteogenesis imperfecta, an affection wholly different in character. Fränkel and Lory use the terms "florida" and "gravissima" in connection with these severer manifestations.

SECOND STAGE

In the second stage, the shadow of the epiphysis becomes more marked. The area is ragged and irregular about the margin, and calcification is more marked at some points than others, which results in a charac-

5. Monti: Rachitis, Kinderheilkunde in Einzeldarstellungen, 1900, ii.

Digitized by Google

teristic mottled appearance. The ends of the diaphysis begin to broaden, especially on the side on which the strain is greatest, which produces a ledge or lip next to the epiphyseal line. In bow legs this is found on the inner side of both the tibia and femur, and in knock knee on the outer side of the same bones. This is the beginning of compensatory changes in the bone structure, which from all appearances are related to weight bearing.

The diaphysis in the second stage begins to give a more definite shadow. The region next to the epiphysis is streaked longitudinally, and is the area of maximum disturbance. At the epiphyseal end of the shaft there is generally a transverse area of increased density reaching about a quarter or a half an inch from the epiphyseal line, bounded at the end furthest from the joint by a fairly sharp line. This continues into the third stage, in which it may become more defined, and resembles in many respects similar changes observed in syphilitic bones in infants, described as osteochondritis, a point discussed under differential diagnosis.

At the end of the diaphysis next to the epiphyseal line there often appears in the late second or early third stage a clear transverse white line, showing increased deposit of lime in the lower end of the shaft. This is apparently not to be distinguished from the "white line"[6] described as characteristic of scurvy, but which is equally characteristic of rickets.

Along the shaft of the long bones a longitudinal change occurs, which is compensatory in nature. This consists in a cortical thickening on the concave side of the bones, chiefly noticeable in bones which have curved. This change is of endosteal origin, and persists into the cured stage of the affection. It is constant in curved bones, and is one of the most important characteristics in differential diagnosis.

6. Talbot, Dodd and Peterson: Experimental Scorbutus and the Roentgen-Ray Diagnosis of Scorbutus, Boston Med. and Surg. Jour., Aug. 14, 1913.

Digitized by Google

Further changes in the second stage consist in chambering of the interior of the bone, where light areas in the shaft indicate the absence of marked bone deposit, and heavier lines of ossification show the irregular development of trabeculae. The smooth homogeneous shadow of normal bone is replaced by an irregularly streaked shadow structure.

The second stage in general is a period of systemic reaction to the disease, in which signs of returning ossification occur and when deformity begins.

THIRD STAGE

In the third stage, the epiphysis begins to resume its normal contour and homogeneous shadow density. Irregularities persist in the marginal outline, and there is still a little mottling in the ossification. The lipping of the diaphysis has enlarged the bone ends, and there is in consequence a discrepancy in breadth between the diameters of the diaphysis near the epiphyseal line and the epiphysis. This relative difference in size is characteristic of this disease. The clouded condition surrounding the joint in the earlier stages has gradually cleared away, and the bone shadows are more definite in consequence. The white line mentioned in the second stage becomes more pronounced in the third.

The other general changes are greater definiteness in the bone shadow throughout the shaft as well as in the joint, and the accentuation of the compensatory thickening of the shaft on the concave side of the curvature. Though irregularities in the bone shadow continue, they are much less marked than in previous stages. In the plates so far observed, the lower epiphysis of the femur seems to be the last to recover its normal outline; but a more extended general study would be required to establish this.

The third stage is what may be termed the period of convalescence. From this point on, the deposit of bone continues, the outline of the epiphysis becomes

Digitized by Google

clean cut, and the epiphyseal shadows homogeneous and rather more than normally dense, and irregularities in deposition in the interior of the shaft become less marked.

The characteristics of recently cured rickets are the enlargement of the diaphyseal end, which is not gradual but is a sudden lipping or ledging next to the epiphysis, the relative disproportion between the diaphyseal end and the epiphysis, and the cortical thickening on the concave side of the bone.

For diagnostic purposes, therefore, the changes may be summarized as follows: The epiphyses show scanty and irregular osseous deposit, and never have a clear normal outline during the acute process. The end of the shaft is streaked, and presents an irregular line at the joint end and above it a curious transverse zone of different structure from the rest of the bone. The interior of the shaft becomes chambered and irregular, and the whole shaft casts less shadow than normal. The ends of the shaft broaden at the junction with the epiphysis, and throw out ledges on the side when strain is to be met. A compensatory cortical thickening occurs on the concave side of curved long bones.

DIFFERENTIAL DIAGNOSIS

In cases of scurvy, the roentgenograms show the clear outline of the epiphysis. Even in cases in which extensive subperiosteal hemorrhage exists, with the attendant bone atrophy of the shaft and occasional dislocation of the epiphysis, the outline of the latter is quite distinct. Atrophy in scorbutic cases, though at times extreme, is uniform. The one point which is common to the two diseases in some cases is the white line occurring at the ends of the diaphyses. On the condition of the epiphysis alone, however, it appears possible to differentiate the two diseases.

In chondrodystrophia foetalis, the epiphysis is perfectly constant in maintaining its clearness and regularity of outline throughout the affection, and though

Digitized by Google

the ends of the diaphyses are broadened, the changes occurring in this region in rickets, which have already been outlined, distinguish this part of the skeleton from chondrodystrophic deformities, which present comparatively uniform shadow densities.

In hereditary osteogenesis imperfecta, one typical hereditary case has been studied very carefully through a period of eight years. During that time there has never been any epiphyseal abnormality or disturbance in ossification at the ends of the diaphysis or elsewhere in the bones, although the Roentgen shadow of the bones is less dense than normal.

The differential diagnosis between congenital syphilis and rickets from Roentgen-ray appearances is at once the most uncertain and interesting part of this comparative Roentgen study. In this connection an extended study of plates of congenital syphilis was made, a study in which I had the invaluable help of my colleague, Prof. Abner Post.

In children old enough to have acquired rickets, that is, in cases in which the question of differential diagnosis between these two conditions might arise, the epiphyses are far enough advanced in their development to be the focal point in the diagnosis. The outline of the epiphysis in syphilitic cases is clear and not seriously disturbed as in rickets. The appearance at the epiphyseal ends of the diaphysis of the zone of bone modification known as osteochondritis in syphilis, as has been said, is similar in appearance to the characteristic diaphyseal change in rickets. In the latter, however, there is in addition to the absence or cloudiness of the epiphysis a marked enveloping cloudiness of the joint. The time of the occurrence of this modification of the end of the shaft is also widely different. In syphilis it is recorded chiefly in the fetus and the new-born, and of its later history we know practically nothing. In rickets it occurs in the first dentition. Extensive periosteal disturbance is common to the two

Digitized by Google

diseases. In the severe type of acute rickets in children with no syphilitic history or signs of syphilis, with a negative Wassermann reaction, severe periosteal thickening, very frequently associated with fracture, is found. Such periosteal disturbance diminishes with the progress of the disease, and shows no tendency to bone formation such as is the case in the periostitis ossificans of syphilis. Moreover, fractures are rare in syphilitic infants. In the metacarpal bones this periosteal thickening is sometimes present in rickets presenting Roentgen-ray appearances of dactylitis, a subject now under investigation for future report.

The irregularities in the medullary shadow of the shaft in syphilis are due to irregular increases in density. The irregularities in rickets are related primarily to diminished density. In the later stages of both diseases the occurrence of cortical thickening is highly differential. In rickets the thickening is endosteal in origin, and is always on the concave side of the curve, while in syphilis the thickening is periosteal or osteoperiosteal, and is very uniformly on the convex side of the curve, resulting in the lower leg in the characteristic "saber tibia." This thickening in syphilis may occur on both sides, however. Further differential study of the two diseases is demanded, because they not infrequently exist in the same patient.

SUMMARY

In rickets, constant changes are to be found while the disease is active, and are located most markedly in the epiphysis and the epiphyseal end of the shaft; but they also involve the shaft. The most important of these changes are (1) delayed ossification and indistinctness of the epiphysis, (2) fraying out of the end of the shaft next to the epiphyseal line, (3) broadening of the end of the shaft next to the epiphyses, (4) cortical thickening on the concave side of curved

Digitized by Google

bones, and (5) areas of diminished density in the bone shadow of the shaft. Periosteal thickening and multiple fractures often occur in the acute stage of the disease.

234 Marlborough Street.

ABSTRACT OF DISCUSSION

Dr. Henry W. Frauenthal, New York: I know I am expressing the opinion of the gentlemen present that Dr. Lovett has given us a most scientific differential diagnosis of the various stages of rickets. But it is most difficult to differentiate between the late rickets and syphilis in our roentgenograms. I expect on my return home to review the plates taken at the Hospital for Deformities and Joint Diseases with added light from this valuable demonstration.

Dr. Roland Meisenbach, Buffalo: I should like to ask Dr. Lovett whether he has laid emphasis on the relation between the width of the epiphyseal line and the hardness or softness of the bone. For instance, in using the osteotome in bow legs or knock knees, we frequently find that in the wide and jagged epiphyseal line the deformity usually occurs near the epiphysis and the bone is spongy, whereas, in the deformities which occur farther away from the epiphyseal line the bone is relatively harder. The decision on a point of osteotomy often depends on the roentgenogram, as does also the feeding of the patient. It is interesting to see the changes in the rachitic bones, the effect of feeding, by means of the roentgenogram.

Dr. J. T. Rugh, Philadelphia: One thing which Dr. Lovett brought out is highly instructive to me. I don't know whether others have had the same understanding in regard to the deposits of bone in these rachitic cases that Dr. Lovett mentioned. I have always understood and taught that bone was deposited where strain took place, just as Dr. Lovett said, and my understanding of the mechanics of these curved bones was that in a bone of this kind—a weight bearing one—the strain did not come on the concave but on the convex side. It is found that in practically all Nature, where there is weight bearing, the strain is on the convexity of the part. This is the part that is stretched. My understanding was that in these bones this was the part which was thickened, and in osteotomy or osteoclasis of these bones, this has been the part that always gave me the greatest amount of resistance with the osteotome. I must say this is a total reversal of my idea, and the Roentgen-ray plates which Dr. Lovett has shown bear out unquestionably his idea. I have seen specimens of bones, however, which

Digitized by Google

have been classed as rachitic, in which a section showed the thickening to be on the convexity of the curve. Possibly, as Dr. Lovett has mentioned here, they may have been syphilitic bones instead of rachitic.

Dr. Robert W. Lovett, Boston: I do not agree with Dr. Rugh's mechanics in this matter. We are considering the question of weight bearing strains and I should suppose that the line of weight would be on the concave side and not on the convex side of the curved tibia.

Dr. H. R. Allen, Indianapolis: You refer to an operation, in which you have the strap arrangement on the outside.

Dr. Lovett: In regard to Dr. Meisenbach's question, I believe we are operating too early in a good many cases of rickets. I personally do not think any patient should be operated on until the lower epiphysis of the tibia, taking that as a standard, has become rounded with a clear outline. As long as it looks indistinct I think it ought to be left alone. At least, that is my experience. When we do operate too early the bone is likely to bleed profusely and cuts like cheese. As a by-product of this investigation I have come definitely to the conclusion that those cases which Dr. Meisenbach mentions are the ones that make the trouble, and that we ought to study our cases with the Roentgen ray and not operate until the subacute stage of rickets is over and the deposit of bone has begun again, because when they are in the subacute stage bones are very poorly provided with lime and are very soft. I thought that we should have a perfectly clear epiphysis before doing an osteotomy or osteoclasis. The difficult point in the whole investigation is in the confusion with syphilis, and it is going to take hard work and exhaustive study to clear that up. I believe the changes of rickets are definite in character and can be diagnosticated in the presence of syphilis, but even the best syphilographers do not know what becomes of the so-called osteochondritis seen in early life.

Digitized by Google

SUBPERIOSTEAL RESECTION IN OSTEOMYELITIS

A CLINICAL AND EXPERIMENTAL STUDY *

D. B. PHEMISTER, M.D.
CHICAGO

It has been known since the time of Galen that the removal of a part or all of the shaft of a bone, which has undergone necrosis in osteomyelitis, may be followed by restoration of the missing portion. Scultetus recorded a classic example in 1634, and a little later Delamatte and Vigarous reported regeneration of missing portions of the tibia. No attempt was made to explain the method of regeneration until after the well-known experiments of Duhamel in 1741, showing the important part played by the periosteum in the formation of callus during the healing of fractures. Subsequently it was attributed to the periosteum which, as was noted, was always detached from the shaft and left behind. Isolated reports of cases continued to confirm this view, but no experimental evidence was offered in its support until the important work of Heine, who from 1830 to 1837 performed, in animals, a number of subperiosteal resections of the various bones of the body, with subsequent regeneration of the shaft in a certain percentage of the cases.[1] Stimulated by this work, Langenbeck, who saw Heine's specimens, Larghi and other surgeons performed a number of subperiosteal resections of portions of diseased shaft, and of the ends of the bones in arthritis with varying degrees of success, as regards restoration of the excised portion.

* From the Department of Surgery, Rush Medical College.
1. Loosen: Die Resection der Knochen und Gelenke, 1894.

Digitized by Google

The experiments of Ollier[2] from 1858 to 1867 were the most extensive and important that have ever been made in the field of bone regeneration. He asserted that only the cells of the inner or cambium layer possess osteogenetic properties, and obtained restoration after complete and partial subperiosteal resections of differently shaped and constructed bones, as the scapula, long bones and bones of the face. When the entire length of a long bone was excised, regeneration of the shaft was fairly complete. The epiphyses were incomplete, but sometimes possessed separate centers of ossification, and were separated from the shaft by broad fibrous epiphyseal lines. Where epiphyses alone were subperiosteally resected, regeneration was usually complete. The skull bones afforded a striking exception in that the pericranium and external surface of the dura mater were unable to restore anything beyond very small portions. Infection had different effects according to its extent. If severe, it usually prevented regeneration of the missing portion, but if mild, new bone formation occurred, which was frequently exuberant, owing to the stimulating effects of the infection. Age played considerable part, regeneration being much less constant and extensive in old animals.

Ollier, Syme and others performed many operations on the basis of this work. Nichols[3] of Boston was the first to make a careful study of its clinical application and bring it before the profession in America, where it has since been perhaps more extensively used than in any other country.

Since the appearance of Macewen's work on the growth of bone, in which he asserted that the cambium layer of the periosteum has no osteogenetic function, there has been a great deal of controversy as to the origin of the new bone, not only in the healing of fractures and in bone transplants, but also in inflam-

2. Ollier, L.: Traité expérimental et clinical de la regen des os, Paris, 1867.

3. Nichols, E. H.: Acute, Subacute and Chronic Infectious Osteomyelitis: Its Pathology and Treatment, The Journal A. M. A., Feb. 13, 1904, p. 439.

Digitized by Google

matory processes and the restoration of their secondary bony defects. There is a great confusion of ideas as to just what happens. Some believe with Macewen that when a portion of the shaft is missing and the periosteum preserved, the regeneration is from an outward growth of the cells of the ends of the bone into the tube or groove formed by the periosteum, and from any small particles of bone cells which are separated from the shaft and cling to its inner surface. In other words, all of the regeneration is from bone cells. But McWilliams obtained regeneration from the periosteum after subperiosteal resection of entire ribs. Davis and Hunnicut[4] conclude from their recent experiments that when bone is resected subperiosteally, restoration of the defect is by outgrowth from the ends of the shaft, the periosteum acting as a limiting membrane; but if particles of bone are left behind or transplanted into the defect, the periosteum is stimulated by them and takes an active part in the formation of new bone. I believe that bone cells are of importance as a starting point for ossification of the fibrous or fibrocartilaginous callus formed by the proliferating inner layer of periosteum, but the periosteum may also form callus without the presence of bone, being sufficiently stimulated by the demand of the weakened part for bony support.

There is no uniformity of results after subperiosteal resection either in the healthy bones of animals or in diseased and healthy bones in man. The full explanation for this has not as yet been determined, but there are a number of known factors of importance, chief among which are age, the presence or absence of infection, and the technic of freeing from the bone the periosteum or involucrum which is left behind.

EXPERIMENTAL RESULTS

Regeneration after subperiosteal resection was tested in animals in the following sets of experiments, in

4. Davis and Hunnicut: Am. Surg., 1915, lxi, 672.

Digitized by Google

which the regions excised correspond to those most often removed in osteomyelitis. The periosteum was removed with a blunt instrument. It comes away from the shaft with ease, but is much more adherent about the ends where the deeper portions are frequently not detached, or chips of bone are removed with it. Separation through the epiphyseal lines was easily performed in very young dogs, but in older ones fragments of metaphyses were usually left behind because of the difficulty of division through the narrow and irregularly curved epiphyseal lines.

1. Subperiosteal resection of the shaft was done in young animals before closure of the epiphyseal lines. Nine operations were done, four on the tibia and six on the humerus. There was a good attempt at regeneration of the tibia in all the animals when they were killed. The youngest was 1 month old at the time of operation. In twenty-six days a small shaft had been restored which was composed of fibrocartilaginous callus with a number of areas of ossification along its course. In a six-month-old dog thirty-one days after resection, a similar regeneration had occurred. The new shaft consisted of a fibrocartilaginous flexible cord, largest toward the epiphyses with numerous small areas of ossification along its course. These may have started from scattered remaining bone cells, but the columnar mass of callus which was ossifying was so large that it must have formed largely from the periosteum.

Figure 1 is of a specimen from a five-months-old dog sixty-five days after operation in which the entire shaft was removed, and no visible particles of bone were left between the two epiphyseal cartilages, although there may have been a few about the ends. The separate areas of ossification are much larger than in the preceding experiment, and many have already fused. Those remaining are separated from each other by narrow bands of fibrous or cartilaginous callus.

It seems incredible that one should doubt the participation of the periosteum in the formation of the largely ossified middle portion, which has no bony connection with either end, or to assume that this entire mass formed from bits of remaining bone cells too small to be detached at operation.

One tibial resection in which extensive suppuration occurred showed at the end of twenty-eight days only a small amount of partly ossified callus near the upper end. The fibula in each experiment underwent marked compensatory hypertrophy.

Digitized by Google

Of the six experiments on the humerus, two were in pups 3 weeks old and were followed by the formation of a small irregular and shortened, largely ossified shaft at the end of thirty-five days. All visible traces of bony shaft were excised. In a 6-months-old animal, all of the shaft was removed except portions of the metaphyses at either end. At the end of fifty-two days there was a newly formed irregular shaft about one-fourth shorter but much greater in diameter than the normal humerus on the other side. (Fig. 2.) Separate centers of ossification are seen which have so fused that the bone is quite firm, thus enabling the animal to regain considerable use of the limb. In three other animals, forty, sixty-eight and eighty days after the resection in which portions of the metaphyses were left, there was marked shortening and little attempt at regenera-ation. Only a few spicules of new bone were present, with free mobility at the seat of resection.

It is difficult to explain the differences in results, as infection was either absent or very slight in all of the cases, and the periosteum was always removed in much the same manner. More osteogenetic tissue must have been left in the cases in which regeneration occurred.

2. Subperiosteal resection of the humeral shaft in five old dogs was followed by a failure of restoration of the shaft in every case. The experiments were 21, 39, 54, 65 and 78 days old, and in none was there new bone formation to any extent. The remaining ends came close together, markedly shortening the limbs, and in the oldest experiment were united by partly ossified callus.

3. Subperiosteal resection of an entire bone was performed in two instances. In a 4-weeks-old pup the entire tibia was removed with portions of periosteum about the lower end which were not separated. In twenty-seven days there was a large irregular, partly ossified, newly formed bone filling in the defect, except at the lower end where periosteum was removed. It had no separate epiphysis at the upper end. In an almost full-grown dog in which the humerus was examined after forty-six days, there was a flail limb with marked shortening and only a few nodules along the course of the excised bone (Fig. 3). Mild infection occurred, and a small pocket of pus was present when the limb was dissected.

4. Subperiosteal resection of the shaft with reimplantation of a support into the defect was performed for the purpose of determining the influence of the insert on osteogenesis of the surrounding sheath. When a live transplant was used, as previously demonstrated, there was new bone formation both from the transplant and from the periosteum, which soon anchors the transplant into its new position. In fifteen

Digitized by Google

animals, the shaft of the bone (either tibia or humerus) was boiled and reimplanted, but in every instance there was more or less infection with fistula formation which either killed the animal or necessitated the removal of the too extensive implant in from one to three weeks. Boiled wooden pegs were substituted for the bone in seven cases, but always with resulting infection. Dissection always showed the insert free in a suppurating canal with a thickened wall which on microscopic examination consisted of necrotic inflammatory or granulation tissue without any traces of callus. Two animals in which the infection was less severe at the onset remained alive and were killed at the end of two months. The dead shaft was easily extracted in each case, and the surrounding infected periosteal layer had produced only a few small nodules of bone along its course. Evidently the infection destroys the remaining osteogenetic cells and consequently interferes with the regeneration. In one nearly full-grown animal, about one third of the boiled shaft of the humerus was split off and reimplanted. It healed in without infection in an oblique position with the upper end protruding beyond the epiphysis, and when the animal died at the end of a month there was a well-developed shaft formed about the implant and along the course of the periosteum. If it were not for the extent of the foreign body implanted, which so predisposes to infection, regeneration of the shaft might be hastened by the supporting action which is contributed.

A review of the gross and microscopic findings shows that after subperiosteal resection of the shaft in young animals, the tube of periosteum partly collapses, and is filled with a blood clot. The cambium layer of the periosteum, if removed, usually proliferates and forms an irregular column of callus along the course of the shaft. Proliferation also occurs from any particles of bone that were detached and from the fragments of metaphyses, if they are not entirely excised. Conversion of fibrous and cartilaginous callus into bone proceeds from the bony surface in the healing of fractures, and ossification of the callus, that is, transformation of its cells into bone cells, in these experiments, probably begins about small bits of attached bone; but this does not mean that all the mass of fibrous and cartilaginous cells originated from the bits of bone. Histologic study shows them to come from the periosteum, and the

Digitized by Google

great bulk of them to be transformed into bone cells. It also appears that centers of ossification develop in this cartilage independent of fragments of bone, just as they do in the embryonal cartilage which preforms bone. Sections through some of these areas fail to show the presence of old bone.

In the light of all the confronting evidence, it is difficult to understand the contention that periosteum is only a limiting and osteoconducting membrane, and that its inner layer of unossified cells does not possess osteogenetic properties. Growth of bone from the ends was impossible in some of the experiments in which all of the shaft was removed, and the ends were limited by epiphyseal cartilage through which growth normally occurs from the shaft in the other direction, increasing the length of the bone by enchondral ossification. Also it could hardly be expected that a tube of fascia lata containing a few bits of bone would give the same results if substituted for the remaining periosteum. Failure of regeneration occurred especially when infection was severe, as in cases in which the boiled shaft was implanted, owing to destruction of the remaining osteogenetic portions, and in old animals in which less osteogenetic tissue is present about the periphery of the bone.

CLINICAL OBSERVATIONS

Clinical observations conform to a certain degree with the experimental results, although there is considerable difference between the resection of a shaft in a healthy dog and in human osteomyelitis. Subperiosteal resection of the noninfected shaft in young persons is followed by regeneration from the remaining periosteum and not by outgrowth from the ends of the bone.

CASE 1.—A girl of 10 had a cartilaginous exostosis of the upper end of the humerus for which a subperiosteal resection of 4 inches of the shaft to the epiphyseal line was performed. A strip of periosteum was removed laterally in the region of

Digitized by Google

the tumor. Figure 4 shows the amount of regeneration at the end of three months. The irregular new shaft was formed from cells of the remaining periosteum, since its upper and lower ends differ little in size, and downward growth from bone at the upper end which was limited by cartilage was impossible.

Figure 5 shows the irregular new shaft with its cortex and medullary cavity at the end of two years.

Davison[5] reports a similar case in which 4 inches of the fibula which had been resected subperiosteally for use as a transplant was completely regenerated at the end of ten months.

In osteomyelitis, the inflammation, which usually starts in the end of the shaft, results in necrosis of trabeculae and pus formation in the medullary cavity, necrosis and penetration of a variable amount of the length and circumference of the cortex, and subperiosteal pus formation with more or less extensive separation of periosteum and perforation into the soft parts.

These destructive changes are soon accompanied by reparative processes. Proliferation occurs in the medullary cavity at the ends of the involved segment, and from any portions of marrow or cortex along its course which have not been killed by the infection. It also occurs along the surface from the periosteum and bone of the regions in which the cortex is not necrotic, and from some of the periosteum lifted up by the pus *after* it has perforated and escaped into the surrounding soft parts. More or less extensive areas of periosteum may be destroyed by the infection, in which case the underlying dead cortex is left without a covering. This encasing mass of osteogenetic tissue or involucrum is fibrous at first, but soon begins ossification in its deeper portion, in the region where it overlies living bone, and in two or three weeks its inner layer of spongy bone is demonstrable with the Roentgen ray.

5. Davison: Tr. Chicago Surg. Soc., 1915.

Digitized by Google

Fig. 1.—Subperiosteal resection 65 days old, and bone of opposite side.

Fig. 2.—Subperiosteal resection of shaft 52 days old, and normal humerus.

Digitized by Google

Fig. 3.—Humerus excised subperiosteally in old dog, and regeneration after forty-six days.

Fig. 4 (Case 1).—Regeneration at end of three months.

Digitized by Google

Fig. 5 (Case 1).—Irregular new shaft with its cortex and medullary cavity at the end of two years.

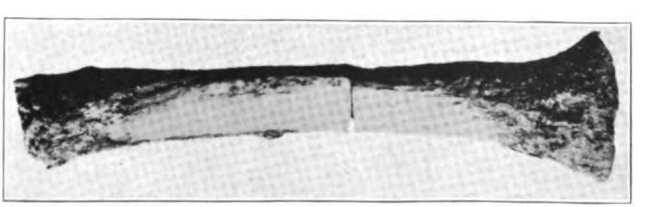

Fig. 6 (Case 2).—Excised tibial shaft, showing necrotic portion.

Digitized by Google

Fig. 7 (Case 2).—Twenty-one days after subperiosteal resection.

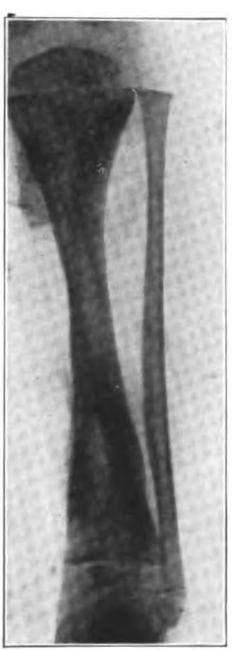

Fig. 8 (Case 2). One hundred and twenty-three days after operation.

Digitized by Google

Fig. 9 (Case 3).—Excised portion of shaft.

Fig. 10 (Case 3).—Two years after excision.

Digitized by Google

Fig. 11 (Case 4).—Small amount of irregular new bone along the course of the periosteum.

Digitized by Google

In case the entire circumference of cortex is destroyed for a distance of from 2 to 4 inches, the surviving portions of periosteum nearly always form an involucrum about it, subsequent total defects after removal of the dead portion being unusual. Ossification of the newly formed involucrum proceeds rapidly from within outward, and is completed in from six to fifteen weeks, depending on the size of the bone and the duration of the acute inflammation. A little less time is required for sequestration of the necrotic portions.

Every case of osteomyelitis should be treated at the beginning by incision of soft parts down to the bone, and excision of a strip of the diseased cortex to establish drainage of the medullary canal.

After subsidence of the acute inflammation and the appearance of the involucrum, the method of getting rid of the necrotic bone must be decided on. In many mild cases, it is absorbed and no further operating is necessary. In others, the necrotic portion is definitely circumscribed and accessible, so that sequestrectomy is clearly indicated. Only in severer cases, in which the necrosis is extensive, does subperiosteal resection come into consideration. Its advantage is that, if regeneration is successful, the entire necrotic portion is removed, the occurrence of fistula and chronic bone abscess is avoided, and the disease is permanently healed as soon as restoration of the shaft is complete.

Its disadvantages are that (1) there is frequently a failure of regeneration of the shaft, leaving a defect to be treated by subsequent bone transplantation; (2) convalescence is much longer than in favorable cases of sequestrectomy, owing to the greater amount of time required for regeneration of the shaft; (3) when there is only one bone in the extremity, considerable shortening and curvature may be the result; (4) it cannot be used in late cases.

Digitized by Google

Failure of regeneration, while sometimes difficult to explain, is due chiefly to the fact that an insufficient amount of osteogenetic tissue is left, or to its destruction by the infection. Early removal of the shaft before the formation of the periosteal thickening and during the height of the infection is particularly apt to be followed by failure of regeneration.

The most favorable time to perform the resection is between the third and eighth weeks according to the case, after the infection has subsided and the soft involucrum has formed. It should be after ossification has started, but while the involucrum is pliable. As much as possible of its spongy, ossified portion should be removed by means of a sharp chisel, as it hypertrophies and aids in the ossification of the fibrous involucrum, similar to the action of the bone cells and chips along the periosteum in the subperiosteal resections in dogs. However, failure of regeneration after resection during this period is not seldom, as shown by the reports of Clopton and Nicholls.[6]

The following case illustrates the successful use of this method:

Case 2.—A girl, aged 3 years, had been sick for twenty-three days with an osteomyelitis, involving the entire length of the tibia, resulting in pus formation at either end, which was drained at the end of one week. There was still considerable discharge and a temperature of 102 F. A small amount of ossification was present in the periosteal thickening, which extended along the entire length of the shaft. An incision was made from one epiphysis to the other, and the thickened periosteum easily reflected anteromesially where an irregular strip of cortex was necrotic along the entire length of the shaft. Laterally and posteriorly, the involucrum was ossified over the living cortex and was separated with more difficulty. The shaft was sawed in two in the middle and the halves extracted. Drainage tubes were inserted at the ends, and the wound closed.

The excised shaft (Fig. 6) shows the smooth, anterior necrotic portion which is separated from the living bone at its margins by a groove filled with granulation tissue.

6. Clopton, M. B.: The Diagnosis and Treatment of Osteomyelitis, Surg., Gynec. and Obst., 1915, xx, 6.

Digitized by Google

The living portion is covered by a thin layer of spongy involucrum, which was not all removed by the periosteotome. The medullary canal showed some pus along its course. There was considerable suppuration for a few days following the operation, after which improvement was rapid. Two small fistulas persisted at the upper and lower ends, which closed after curettage at the end of three months. Figures 7 and 8 show the amount of regeneration twenty-one and 123 days following the operation. The child has been walking on the limb since the fourth month, and recovery is complete without shortening at the end of two and three-fourths years.

If resection is attempted late after the involucrum is too thoroughly ossified, great difficulty will be encountered in removing the deeper portion of the periosteum from the roughened surface, and few unossified osteogenetic elements will be left. Consequently, there is very apt to be failure of regeneration, as illustrated by the following case.

Case 3.—A boy, aged 16 years, had osteomyelitis of the lower end of the fibula of nine weeks' standing, with abscess formation which had been opened and drained. At operation the large involucrum was found to be rough and ossified, so that it was difficult to remove much of the periosteal covering, which was gotten off as best possible by means of a periosteotome. About 6 inches of the shaft was removed down to the epiphyseal line (Fig. 9). The wound, which was drained, healed in four weeks with little discharge.

After one month the boy began using the limb, which has since remained well and strong. Figure 10 shows the condition at the end of two years, with a defect of the fibula about 4 inches in length. Fortunately, the malleolus is preserved, and it makes no difference to the patient.

The cause of the failure is easily determined when the excised specimen is examined. Its surface is very irregular and the involucrum is extensively ossified. Microscopic sections from the cortex show that while the periosteum in many places was left, in most places it was removed with the specimen. This was due, to some extent, to the irregularity of the surface; but by vigorous use of a sharp instrument, more osteogenetic tissue could have been left. However, it is a question if such a thin layer, which had already undergone extreme hypertrophy, could have formed a new shaft.

Digitized by Google

Verifying the results of animal experiments, osteomyelitis in adults is less suited for subperiosteal resection than in children.

CASE 4.—A man, aged 45, had pneumonia which was followed by osteomyelitis of the tibia. Four months after the onset a surgeon removed subperiosteally two-thirds of the lower end of the bone, including the epiphysis. The wound had healed except for a small fistula when first seen at the end of nine months. Figure 11 shows the small amount of irregular new bone which had formed along the course of the periosteum. The late date (four months) at which the resection was performed, as well as the age of the individual, was responsible for the failure of regeneration.

In view of the clinical and experimental data now at hand, showing the frequent failure of regeneration, subperiosteal resection should be reserved for selected cases of osteomyelitis in which there is extensive necrosis of bone, and particularly when it is located in areas inaccessible to operation, as the posterior part of the tibia. Its use should be limited to parts of the body in which there is some other bony support, and should almost never be used where there is only one bone in the extremity, as later sequestrectomy gives better results in such cases. The operation should not be performed too early while the infection is severe, and before a soft involucrum has formed, nor too late after the involucrum is so ossified that an insufficient amount of osteogenetic tissue is removed.

In case of failure of regeneration, the defect can best be repaired by free transplantation of bone, although a missing shaft of the tibia can be remedied by division of the fibula above and below and shifting it into the tibial defect, a method which was first used by Huntington.

122 South Michigan Avenue.

ABSTRACT OF DISCUSSION

DR. THOS. W. HUNTINGTON, San Francisco: With but a small personal experience. I do not seem to be in accord with prevailing opinions, as set forth by Dr. Phemister. In about

Digitized by Google

50 per cent. of the cases in which I have attempted subperiosteal resections in osteomyelitis my results have been unsatisfactory. The reason for this has been the presence of infection of more or less severity at the time of operation. In a single case I avoided this procedure by resorting to bone transference, substituting the fibula for the tibia. The case is in the literature, and the method has been followed by several other surgeons with uniform success. In my own case the result is ideal; the young man has grown to adult life and suffers no inconvenience whatever from his former trouble. One feature is of considerable interest, namely, that the transferred fibula, carrying with it its own nutrient artery and receiving an exaggerated nutrition from the remaining fragments of the tibia, hypertrophies rapidly and, ultimately, assumes the dimensions of the normal tibia. The absence of the shaft of the fibula seems not to lower the efficiency of the limb to any degree. At the time I made this effort I supposed that the idea was original, but on further search I find that an Italian surgeon, as early as 1860, resorted to an analogous procedure by transplanting the upper end of the fibula into the lower end of the femur. His result was altogether satisfactory.

Dr. J. P. Lord, Omaha: In the discussion of Dr. Phemister the statement is made that severe infection will destroy the periosteum. That we grant, but it is my experience and observation that a great deal of this injury to the periosteum has been done by too rigorous treatment, for which the surgeon is responsible, namely, in the too vigorous use of the curet and the too thorough application of strong antiseptics. I will not amplify, but I wish that all the younger men would bear this in mind. I have caused damage myself in this respect. I am now more respectful of the tissues, and my later results are better. The other point I wish to make is that in some of these cases we should simply open the bone. When the medulla is reached, guarded use of the curet should be made. There are some who seem to disregard the endosteum and its functions, and its great power for assisting in the regeneration of bone. Another feature of the treatment which I wish to emphasize is this: Many surgeons continue to pack these cavities with gauze, and also dress these cases with undue frequency. Their patient will have a rise of temperature every time a dressing of this kind is changed. Sometimes I use gauze to control the hemorrhage for the first dressing, but after that (because of considerable experience with children) I minimize the severity of the treatments. Of course, I use the methods which you all use of enfolding the parts and minimizing the cavity. I use iodized vaselin, 1:1,000, and I keep these troughs filled up with the vaselin, and regeneration takes place under it and fills the cavity.

Digitized by Google

You can actually do these dressings with a child smiling, and in a perfectly good humor. Now the parting shot I wish to make is a greater consideration for the regenerative power of the periosteum and endosteum, less surgery, and less vigorous treatment with antiseptics. I think that in simple drainage, and more regard for the tissues, we will better serve Nature in her efforts at repair.

Dr. Leonard W. Ely, San Francisco: The presence of a cambium layer of the periosteum I doubt, on the basis of a great many sections of normal and diseased bones. Instead of a cambium layer of periosteum, we find pockets of marrow here and there under the fibrous layer. These pockets of marrow are continuous by small channels in the bone with the marrow in the central canal. Here we get back to the bone-forming function of the marrow. We say that marrow forms bone, but marrow itself is not essential to the formation of bone any more than is an inner layer of periosteum. In studying embryonic bones, we find a cylinder of cartilage transformed into bone by blood vessels pushing into it, carrying their bone-forming cells, and transforming this cylinder of cartilage into bone. Embryonal bone contains no marrow, nor does cartilage that is being formed into bone. Again, in the epiphyses of bones we see bone forming, as it already has formed in the shaft. We see cartilage changing into the bone; but what changes it? There is no marrow there. If we make serial sections of the epiphyseal cartilage, we find from the periosteum, from the marrow, or from the synovial folds, that the vessels are pushing in to the center. When they reach the center, they begin to form bone. Bone is formed by osteoblasts. The osteoblasts are located, in adult life, in the marrow. We do not know an osteoblast by sight. We cannot identify any particular cell as an osteoblast. We say when we see a peculiar appearing cell in a certain locality, "That is an osteoblast"; but by itself we have no way of recognizing it, and we do not know whence it comes. Here is our problem to solve: What is an osteoblast and whence does it come? The osteoblast, whatever it is, manufactures bone out of one of two tissues, namely, cartilage or fibrous tissue. The osteoblast is the active agent. The cartilage or fibrous tissue is the plastic material out of which bone is made. In a fracture of a bone, these marrow cells, whatever they are, do not bridge the gap immediately and manufacture bone, but they manufacture it out of cartilage on the outside, and out of the fibrous tissue which is deposited by the periosteum between the two bone ends.

McEwen put on the outside of a bone under the periosteum a ring, and he finds that bone does not form over this ring. Periosteum, he says, has no bone-forming function; but it has a "bone-forming function." It cannot manufacture bone

Digitized by Google

itself, but it is so much plastic material out of which bone is formed. When he separates it from the osteoblasts, which are located in the marrow, by putting a ring inside it, there is no bone formed on the outside of the ring, because the active bone-forming agent cannot get at the periosteum to manufacture bone. Stones do not build a wall. The mason builds the wall, but he must have stones with which to build it. The osteoblast is the mason.

Dr. E. W. Ryerson, Chicago: It is impossible to say too much in commendation of the work Dr. Phemister has been doing to bring a little real knowledge out of the chaos in which all of our conceptions of osteomyelitis have heretofore been plunged. I do not know of any subject, except possibly the time-worn subject of the treatment of tuberculous abscesses, in which so many different things and practices have been current in the past. It is evident that to interfere with osteomyelitis successfully requires certain definite knowledge, which in the past we have not had. Dr. Phemister has been endeavoring to establish a time at which, for instance, a sequestrum should be removed, and a time at which a necrosed shaft should be removed. I have had three cases of successful regeneration of the entire tibia, after its complete removal in old osteomyelitis, and evidently I removed the shaft at exactly the right time. I have had a perfectly complete failure of regeneration in a tibia, where the entire shaft was removed, and it is evident that I removed it at the wrong time. We must study and we must learn a little more definitely the exact time at which to do this work.

About the treatment of acute and subacute osteomyelitis I want to endorse some of the things expressed by Dr. Lord. We must not be too radical with our treatment of osteomyelitis, of which we see so many examples. In the shaft of the tibia, for instance, it should not be too radically treated. An opening in the bone should be made practically the full width of the tibia, the entire length of the infected area, and not a bit of curetting should be done, nor any antiseptic treatment, even though the medullary cavity be full of pus. Many of us have treated these cavities just as a dentist treats a cavity in a tooth, but that is not the proper way to do. The cavity in a tooth is an entirely and distinctly different entity from that of an osteomyelitic cavity in a long bone. We should simply drain, and drain by a method which is not ordinarily used. We do not sew up any of these incisions. Let them stay open, and do not put a dressing on them—do not put the dressing on the wound, but put the dressing around the wound, and let the entire wound stay open to the air without any dressing on it at all. When the pus fills it up, roll the leg over and let the pus run off into the dressings, and irrigate it with a little normal salt solution. Do

Digitized by Google

not use any iodin or any other antiseptics. Let the patient stay with the leg stretched out on a chair all during the day, in the sun, with no protection whatever over the wound, except a coarse wire gauze protector. When treated in this way, these cases of osteomyelitis heal up almost magically, and I have been astounded to see the rapidity with which these large cavities fill up with bone in the relatively few cases on which I have used this method of treatment in the last six or eight months. It is easily the best thing I have seen yet, and I reiterate what Dr. Lord has said—don't do too much to your osteomyelitis cases. As to the proper time to remove sequestrums, we have not as yet been able to formulate any definite rule.

Dr. Roland Meisenbach, Buffalo: I have great respect for Dr. Phemister's work, as I have followed it for a number of years. However, I have also great respect for the endosteum when it comes to bone regeneration. I am not at all convinced that the periosteum proliferates enough to regenerate an entire bone. I believe that in many subperiosteal resections there remains some of the endosteum. I have been impressed with the rapidity of the regeneration of the endosteum on several occasions, and I believe that the endosteum proliferates three to one as against the periosteum. I base my opinion on my own observation in animal experimentation in which I have had occasion to section the cortex of the bone of a large number of animals and examine the sections microscopically. I have been impressed with the number of osteoblasts found in the region of the endosteum, and as the endosteum is so closely allied to the bone marrow, it is easy to see why there is a great regeneration at this point rather than at the periosteum. Since viewing the microscopic sections of cortical bone which Dr. Ely kindly demonstrated to us in the laboratory, I am more convinced than ever before that many of the theories of bone regeneration will require modification. I think the practical regeneration of bone is well shown in the cases of osteomyelitis in which most of the new bone comes from the endosteum and creeps along the sequestrum to meet some of the bone proliferated by the periosteum, thereby often forming an entirely new tibia. I think these cases were placed on record several years ago. In cases in which one has removed the gap in the long bone and in which one bridges over the periosteum, I believe that it is the endosteum that forms most of the new bone of the cortex rather than the periosteum. This brings out an important point, that in osteomyelitis one should not be too anxious to remove the sequestrum formed, because it often acts as a bridge for the newly developing bone. I think the stimulating effect of the staphylococcus on the endosteum accounts for the rapid regeneration in some of the cases, even

Digitized by Google

those that are infected with staphylococcus. What I have said can be shown in sections. I have a series of sections with me which demonstrate the proliferation of bone in relation to the periosteum and endosteum, and make a good study. They have a direct practical bearing on bone-graft work, and if one keeps these in mind, one will know why certain cases do better than others.

Dr. Ethan H. Smith, San Francisco: In this class of cases I consider the bone curet a necessary instrument at times, but frequently more abused than any other bone instrument in use. Along with the uterine curet, I think that the bone curet is going to be soon curtailed in its use. In operating on these cases we should do a clean-cut operation, with sharp instruments and see what we are doing, and in removing the damaged tissue do it neatly and carefully, with as little bruising, abrasion or rubbing in of pus or débris in the raw surface as possible. I think that rough methods account for a great many disastrous results. The time at which an operation should be begun in osteomyelitis is a big factor in these cases. The doctrine still obtains that we are warned against interfering too soon in infections of bone and we were cautioned not to meddle with these cases until a sequestrum has separated from the sound bone. This change, recognized by old observers, depends on the virulence of each case. The remarks of Dr. Ryerson about the proper method of opening and draining these cases are particularly timely and good, and I endorse that idea exactly.

Dr. J. T. Rugh, Philadelphia: One point in regard to these grafts which are placed for deficiencies of various types is that the graft itself presents a certain degree of resistance and immunity toward infection. Various forms of infection influence the graft differently, that is, a graft will have a certain degree of immunity toward one type of infection while with another type it will break down and absorb rapidly. Further investigation and work along this line will show us a wider field of usefulness for the bone graft in the presence of infection and that we shall be able to utilize the graft as a stimulant to the proliferation of new bone in many cases in which some of the periosteum has been preserved, as in subperiosteal resection.

Dr. D. B. Phemister, Chicago: My conception of the composition of the shaft of a bone is as follows: It consists of a cortex of more or less compact bone in which are canals containing blood vessels and some connective tissue cells. Its medullary cavity is lined and filled by a loose connective tissue reticulum in which are contained the bone marrow or hemopoietic cells and fat in varying amounts, depending on the age and particular bone. This connective tissue reticulum is known as the endosteum. The bone is sur-

Digitized by Google

rounded by a connective tissue covering which consists of an outer thicker portion of white fibrous tissue and of an inner layer along the bony surface, of loose richly cellular tissue. This covering is known as the periosteum and the inner layer, which is thickest during the period of growth, as the cambium layer of the periosteum. New bone growth and bone repair occur by the proliferation and ossification of the cells of these three portions, namely, the endosteum, the cells of the canals of the cortex and the cambium layer of the periosteum. They are known as osteogenetic tissues and their cells as osteoblasts. The bone cells, which are situated in lacunae and closely surrounded by an abundance of lime salts, do not multiply to any appreciable extent. To speak as Dr. Meisenbach does of that portion of the osteogenetic tissue lying outside of the medullary canal as endosteum, is a misnomer.

I have tried to show in these experiments that the loose cellular layer lying on the bony surface and known as the cambium layer of the periosteum, if left behind in subperiosteal resections proliferates and plays an active part in the regeneration of the shaft. In osteomyelitis the cells of this layer as well as those of the canals of the living portion of the cortex proliferate and form an involucrum about the shaft which at first is soft, but which soon ossifies. In those cases in which a subperiosteal resection seems advisable it is best done not too early, while the infection is severe, and before the soft involucrum has formed; nor too late, after the involucrum has sufficiently ossified that it cannot be stripped away from the shaft. In either case there is apt to be too little osteogenetic tissue left to regenerate the shaft.

Digitized by Google

KNEE JOINT DISABILITY CAUSED BY HYPERTROPHY OF THE ALAR LIGAMENTS

ROLAND O. MEISENBACH, M.D.
BUFFALO

Notwithstanding the well-defined surface anatomy of the knee joint, especially in its anterior portion, it is not always a simple matter to differentiate the actual condition within the joint in some of the disabled knees which come to us for relief. This statement is confirmed by many writers, and it appears several times in the literature. This is true especially in those cases which do not give classical symptoms of one or the other of the many conditions which are constantly being encountered in joint surgery.

Not alone in the acute knee, but also in the chronic, do we frequently notice that definite subjective symptoms are absent. This, I believe, is one of the reasons for the frequency with which an acute disability of the knee joint is tolerated by the patient and terminates in a chronic disabled knee. Either the patient expects spontaneous relief, or the condition is deemed not direct enough for active interference.

The knee joint is constantly exposed to injury; this injury may be from external or from internal sources. The external sources comprise weak feet, irregular shoes, faulty alignment of limb following fracture of the leg or thigh, or both, besides the leverage twists, wrenches and actual direct violence.

The internal injuries may be induced by the knee joint's mechanism or a concomitant pathologic condition, or both.

Digitized by Google

THE KNEE JOINT

Considering the fact that the knee joint is one of the most important, largest and quickest joints to become injured, one would expect that its internal arrangement, as far as the anatomy and mechanism are concerned, would be well understood by all who have to do with this joint. Its mechanism is not stable, and its anatomy differs in many instances.

Perhaps the extreme range of motion which the knee joint exerts is the cause of the variation; at any rate, I believe that many of its soft parts, especially in the anterior portion and those which have to do with the lubrication, are constantly subjected to change.

The function of the synovial membrane and its different parts, namely, (*a*) ligamentum mucosum and (*b*) alar ligaments, is to lubricate the cartilaginous articular surfaces of the gliding parts.

The anatomy of the knee joint is described by Tenney in a most thorough manner. I wish here only to emphasize some facts and to describe that which pertains to this paper, namely, the alar ligaments.

ALAR LIGAMENTS OF THE KNEE JOINT

Normally, the alar ligaments are wing-shaped folds of synovial membrane extending from the mucosa, and are in my opinion part of the lubricating tissue. They are the moving parts and find their place along the condyles of the femur in the anterior portion of the knee joint.

Considering the mechanism of the knee and the function of the vascular alar ligaments, together with their close proximity to the moving parts, it is not difficult to imagine that they might become hypertrophied, consequently interfering with motion in the knee joint, and thereby giving rise to symptoms. The condition has occurred in young and old in acute and chronic knees to a lesser or greater extent.

Digitized by Google

In those cases in which the diagnosis of hypertrophy of the alar ligaments had been made, there was either a history of a previous injury (as in Case 1) or a very active knee (traumatic functional) in an individual who had previously had an infection (Case 3).

Many other conditions (enumerated in the differential diagnosis below) were considered before making an absolute diagnosis. The roentgenogram was also used, and assisted materially. I mean that the hypertrophied alar ligaments and the mucosa can sometimes be seen and differentiated from other soft structures in the anterior part of the knee joint. The most important for diagnostic purposes is the infrapatellar fat pad in a well-prepared negative. The operative findings, together with the permanent relief given the patient, seem to confirm the diagnosis in some of the cases presented below.

Considerable has been written on derangements of the knee joint, which may cover many conditions causing disability. Hypertrophy of the alar ligaments may well nigh be included in it; however, I am not willing to accept derangements of the knee joint as a diagnosis for treatment, because in many instances by it relief cannot be given.

DIAGNOSIS

The histories of the cases which have been diagnosed as disability caused by the hypertrophy of the alar ligaments have been those of trauma or those of disease and trauma, as has been stated above. Therefore, it has been necessary to study cases carefully and attempt to separate those occurring from trauma only, that is, external trauma, and those which have had some infection in which the anterior portion of the knee joint was previously made pathologic, owing to a congestion or an actual infiltration. Also, the histories of many of the patients that come to us with

Digitized by Google

knee joint trouble are indefinite. They are irregular, indeed, and on examination the knee is not necessarily swollen, but at times one can palpate, as in extreme cases of villous arthritis, the villi; the thickened ligamentum mucosum, if not the alar ligament, on either side of the patella. These cases do not always show the capsule distended or the patella floating; the pain is chiefly noted on extreme flexion and extension of the knee joint, and in the anterior portion, the patient usually pointing to the patella, so that in some cases at first one is almost in doubt whether we are not dealing with a bursitis. In some of the cases, and especially those which show that infectious arthritis has been a predisposing cause, there may be a marked distention on both sides of the patella, and the patella may float.

The roentgenographic finding is of great importance. If the technic of making the roentgenogram is carried out with a view to exposing the soft parts, many of the soft structures of the knee joint can be seen on the negative, if not on the printed reproduction. The negatives illustrating this are of the softest variety. Some of the soft structures which are at times discernible are the patella tendon, the anterior fat pads, the ligamentum mucosum and the alar ligaments in suitable cases.

In one of the last cases with operation, in which a diagnosis of hypertrophy of the alar ligament was made, the internal alar ligament was elongated, very thick, deeply congested and actually adherent to the femur, so that every time the knee flexed, the synovial membrane was drawn inward. The joint had very little fluid within it.

Atrophy of the thigh and calf is frequently present, probably atrophy of disuse. Actual locking of the joint does not occur, but a sudden weakness of the knee may be complained of by the patient.

Digitized by Google

DIFFERENTIAL DIAGNOSIS

The conditions which are most apt to require differentiation from the hypertrophic alar ligaments are: villous arthritis, lipomas, loose semilunar cartilages, atrophic arthritis, knee joint strain, osteo-arthritis, infectious arthritis, loose bodies in the knee joint, and bursitis. As has been said before, any one of these conditions may also be associated with hypertrophy of the alar ligaments, and therefore they must necessarily be considered in dealing with the subject; but the cases herewith reported are chiefly those in which none of these conditions were marked, and in which apparently the hypertrophied alar ligaments were causing the actual disability, and after they had been removed the disability of the knee joint passed away, giving the patient a useful joint without symptoms.

1. *Villous Arthritis.*—In this we are more apt to have a history of infection. The knee joint swells more readily and the capsule is frequently distended and well defined, with the quadriceps pouches full. In palpating, one can frequently feel the fringes, or villi in the quadriceps pouch. On opening the knee joint, excessive straw-colored fluid may be seen, and everywhere elongated villi from the synovia are evident. The subjective symptoms are also irregular, but are more pronounced. Frequently, there is actual limitation of motion on flexion.

2. *Lipomas of the Knee Joint.*—These are usually found in lipomatous individuals. The same condition that is found in the knee is frequently found in the ankle. The patella, as a rule, does not float.

3. *Semilunar Cartilages.*—In loose semilunar cartilage we have many and varied symptoms, from the locking of the knee to a snapping on the internal or external aspect of the joint when motion is attempted or when weight is borne.

4. *Atrophic Arthritis.*—Here we have a glossy skin, the atrophied bone, with erosion of the cartilage,

Digitized by Google

which may be noted from the roentgenogram, and perhaps the joint interspace diminished. Frequently, other joints besides the knee joint are involved and limitation of motion is present.

5. *Knee Joint Strain.*—This may simulate hypertrophy of the alar ligaments, but in the former the slightest motion of the knee laterally will bring on a severe attack of pain. Therapeutic measures directed toward the foot may be of great assistance in differentiating.

6. *Hypertrophic Arthritis.*—This is the easiest to differentiate because the Roentgen ray assists materially in showing the osteophytes and the roughened articular joint surfaces. Limitation of motion is frequently found, and there is a grating or creaking of the knee joint when active or passive motion is attempted over the joint. The skin is rough and dry, and other joints are involved, which show similar pathologic conditions.

7. *Infectious Arthritis.*—In this we frequently have other joints involved besides the knee, as, for instance, hands and wrists or perhaps the ankles. The knees may become swollen and remain so for a longer or shorter period, and after this swelling subsides there is still a disabled knee, or one which gives intermittent symptoms of disability, chiefly on extreme flexion or extension. It is in this type of case that we should look for hypertrophy of the alar ligaments, and if the danger of stirring up an infection is remote, the removal of the alar ligaments will allow the knee to be used normally.

8. *Loose Bodies.*—These are well shown in the stereoscopic roentgenogram, and if they have created a pocket, the surface of the tibia or the articular surface of the femur will show marks of destruction. Locking of the joint in these cases is classical of the condition.

Digitized by Google

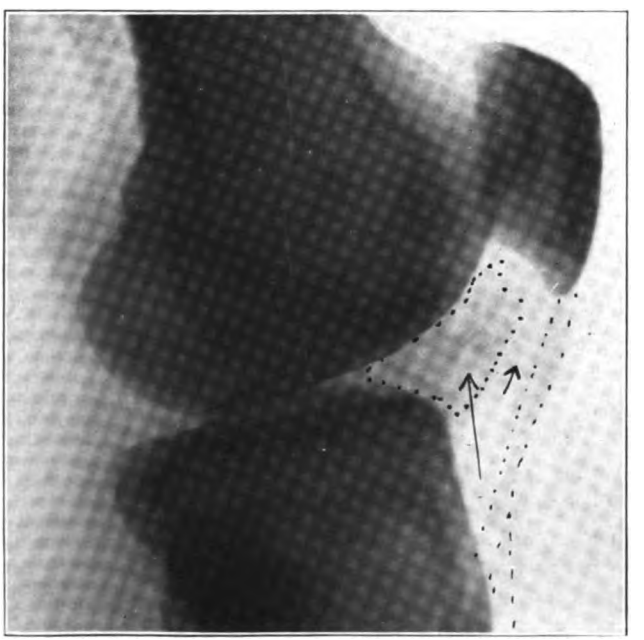

Fig. 1.—Patellar tendon, infrapatellar fat space and hypertrophied alar ligaments.

Digitized by Google

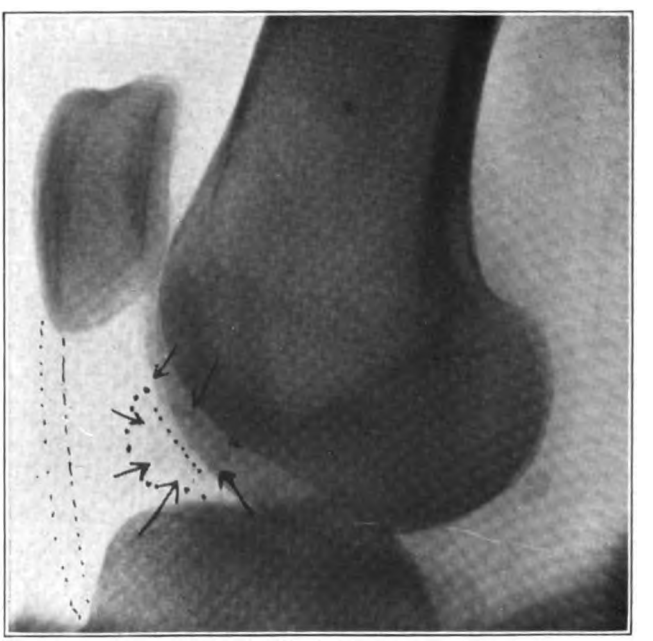

Fig. 2.—Dark mass, irregularly defined and mottled. Hypertrophied alar ligament. Note sessamoid bone in posterior part of joint.

Digitized by Google

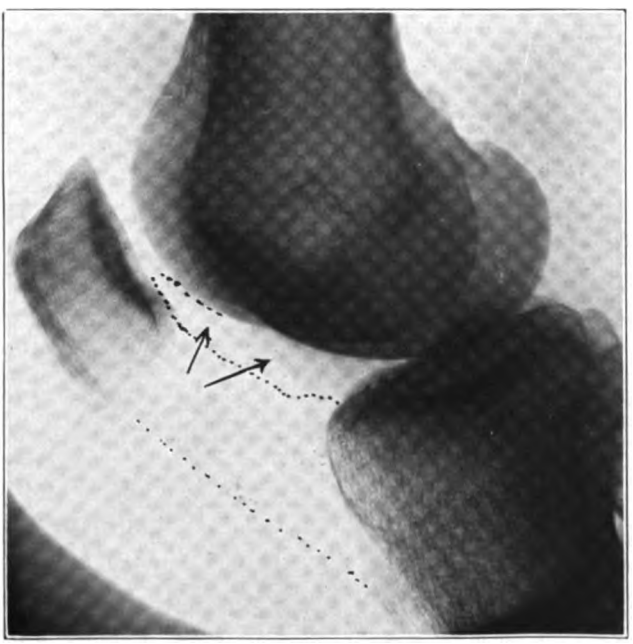

Fig. 3. — Note clear anterior portion of joint and the soft dark shadow which extends somewhat under the patella.

Digitized by Google

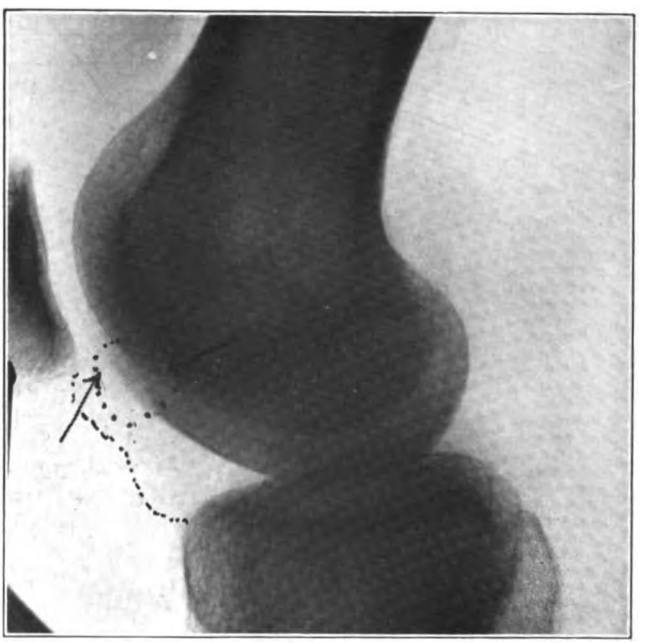

Fig. 4.—Note circumscribed dark area which proved to be thick alar ligament.

Digitized by Google

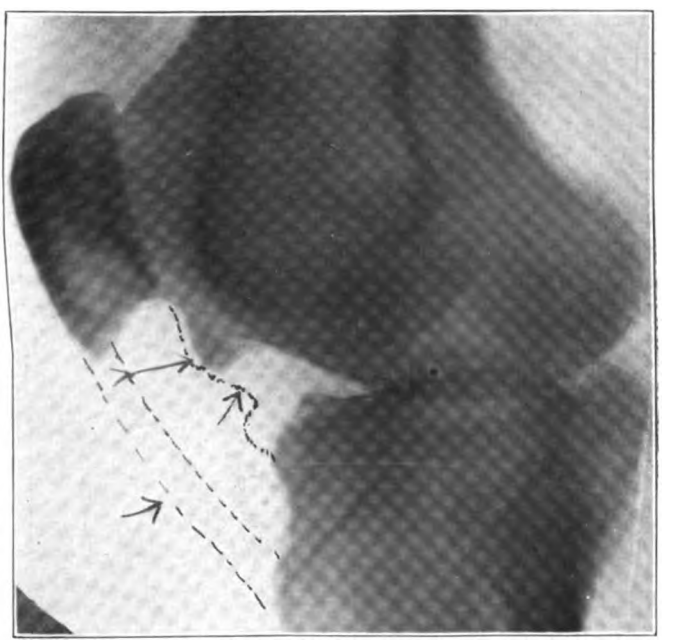

Fig. 5.—Note dark pronounced shadow. Operation proved it to be hypertrophied alar ligament.

Digitized by Google

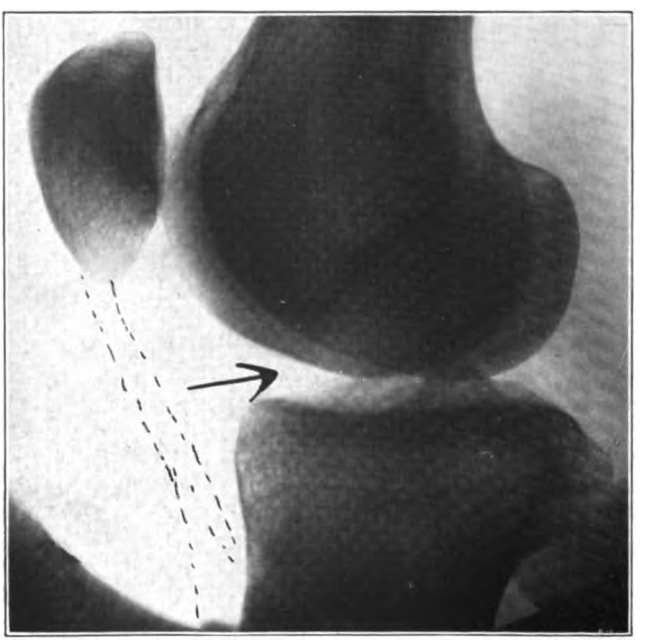

Fig. 6.—Normal knee. Note clear joint interspace.

Digitized by Google

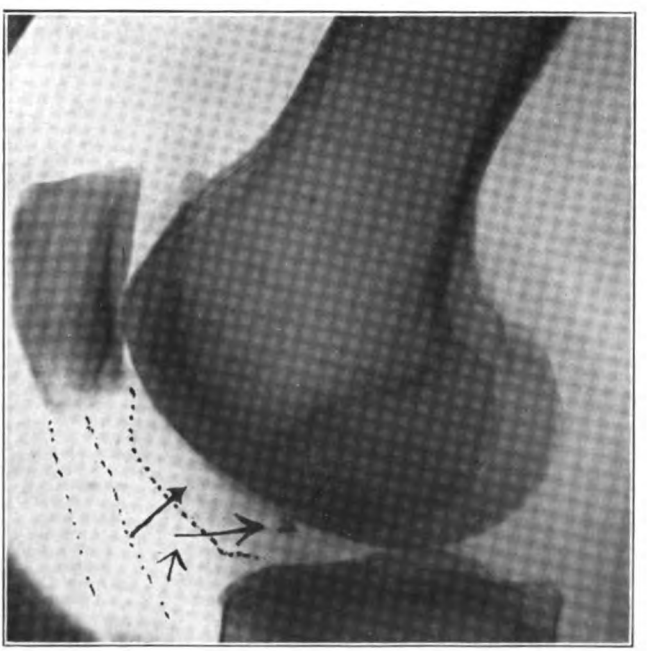

Fig. 7.—Note dark joint interspace.

Digitized by Google

Digitized by Google

9. *Bursitis.*—Palpation will often produce pain over the bursa, which is sometimes visible, although it may be at times confusing, especially when the patient gives a history of kneeling, or the bursitis is mild. The knee itself is not swollen, and on the lateral aspect of the patella in the joint line nothing abnormal is felt. However, if the bursitis is due to systemic infection, then again we may have it associated with hypertrophy of the alar ligaments.

TREATMENT

There is only one permanent treatment for knee joints with hypertrophied alar ligaments; that is, their removal. Temporary relief, or symptomatic relief, may be given in some cases without removal. Limiting the motion of the knee and strapping give relief to symptoms only, and should not be advised except in rare instances, as enumerated above. The operation of arthrotomy, advised by many, if done in conservative and skilful hands, offers very little danger, and the old idea that an operation on the knee joint means a stiff knee is, I am glad to say, past. Formerly, perhaps, this belief was well founded; but with improved operative technic in these cases the danger is at a minimum, both as to obtaining a stiff knee and as regards sepsis; it is, in fact, no greater than in some of the other surgical procedures of the day.

In the technic of arthrotomy for the purpose of removing alar ligaments, certain principles must necessarily be observed, the same as with any other arthrotomies of the knee joint. First, there should be perfect asepsis; second, the incision should be as small as possible; third, the knee joint should be in a position of semiflexion. All bleeding should be checked before the capsule is opened; the capsule should not be held with hemostats. The finger need not enter the knee joint.

In removing the alar ligaments, they should be clamped at their base with a very fine hemostat,

Digitized by Google

removed above the hemostat with scissors so as to insure no hemorrhage within the joint. Rarely tying within the joint is necessary. The capsule should be closed with silk or chromic gut and the knee joint bottled tightly and not drained. Passive motion should be done early, and the patient may walk as soon as the incision is firm. A few cases cited below will serve as an illustration:

Case 1.—Mr. B., gardener, aged 22, operated on Nov. 3, 1911, gave the following history: Two months previously, while lifting sod, using his right knee joint to assist the spade, he found his knee going weak. He gave up work and found that whenever he bent his knee or attempted to get out of a chair, he had pain. After resting the knee joint it grew better; but as soon as he attempted to walk much or ride a bicycle, the knee became painful. The knee was not swollen, and no crepitation was felt, but patient complained of pain after the knee was bent in extreme extension and flexion. A roentgenogram was taken.

A diagnosis of hypertrophy of the alar ligaments was made. The knee joint was opened by an incision on the inner border of the patella. The capsule was noted to be drawn into the joint, and when the capsule was opened, the knee joint was held in position of semiflexion. After retracting, it was noticed that two or three tabs extended from the mucous membrane in the anterior portion. The fibrous band could be seen tensely stretched, apparently from the ligamentum mucosum down to the surface of the tibia, suggesting that synovial tabs had become adherent. These tabs (alar ligaments) were removed, and the joint closed tightly. There was very little bleeding during the entire operation. Motion of the knee joint was begun on the seventh day and convalescence was uneventful. Patient returned to work.

Case 2.—Mr. G., aged 19, athlete, seen Dec. 21, 1911, gave a history of suddenly having his right knee become weakened, and at times painful. He said that he had had the habit while walking of throwing his knees in strong extension. The knee occasionally became swollen, but did not lock. A roentgenogram was taken.

The anterior portion of the joint showed a slightly dense shadow in the region of the ligamentum mucosum. Examination of the knee showed that the surface anatomy was apparently normal; no crepitation was felt on motion, and no swelling. The right foot was considerably pronated; otherwise the patient was in excellent health. Blood count negative.

Digitized by Google

A diagnosis of hypertrophied alar ligaments was made. Operation, Jan. 5, 1912. Incision on inner aspect of patella. Knee joint opened according to special technic; synovial membrane relaxed; no fluid in joint; alar ligaments removed; no other tabs protruding from synovial membrane. Patient had an uneventful recovery. Symptoms disappeared. Patient seen three years after the operation; no recurrence.

CASE 3.—Mr. J., chauffeur, aged 21, had neisserian infection one year ago. Previously had been treated for flatfoot. To all appearances perfectly well, but while driving his car noticed that his right knee was painful and slightly swollen. This swelling has persisted for several months. Slight thickening felt on the internal and external aspect of the patella. Roentgenoscopy revealed thickening in anterior portion of the joint, extending well into the joint.

A diagnosis of hypertrophy of alar ligaments was made. July 18, operation, arthrotomy of right knee joint. Incision of internal aspect of patella. On opening the capsule considerable fluid emitted from the joint. Synovial membrane injected and quite vascular. Ligamentum mucosum and alar ligaments thick and boggy. Alar ligaments removed, considerable hemorrhage, one squirter from each tied. Knee joint closed tightly, no drainage. Convalescence uneventful. Patient able to continue occupation as chauffeur up to the present writing.

CASE 4.—Miss P., aged 33, occupation institutional work. Has always been well, with the exception of her knees, which have been painful intermittently. Patient has been accustomed to kneel frequently, many times coming down firmly. Last several months has noticed when she attempts to get up there is sharp pain, which disappears after a while, but recurs. Examination of knee joint shows slight roughening of the skin over the patellar bursa of both knees. Knee joint not swollen and no crepitation. Extreme flexion elicits some pain. Roentgenogram taken and a rather diffused shadow of homogeneous consistency seen a short distance below patella.

Diagnosis after eliminating other conditions, hypertrophy of the alar ligaments. Operation, arthrotomy, May 14, 1915. After capsule incised, ligamentum mucosum and alar ligaments were seen to be congested and one internal alar ligament adherent to the femur. The alar ligaments were removed; knee joint closed. Recovery uneventful.

CONCLUSIONS

In presenting this paper, it was my object especially to call attention to the variety of conditions which may be found in disabled knees, all of which may present more or less some of the same symptoms, but if

Digitized by Google

carefully studied, will be found to be distinct entities; but more than that, to attempt to call attention to the type of knee joint which is so frequently seen, in which the symptoms are so irregular that only by a thorough search, and in some cases by means of eliminating the other conditions, the patient will obtain relief.

140 Allen Street.

ABSTRACT OF DISCUSSION

Dr. Fred. J. Fassett, Seattle: Dr. Meisenbach asked me to participate in this discussion, and I promised to look up my anatomy on alar ligaments and where they are to be found. In doing so I was quite impressed with the exact spot, because they lie just where I have found symptoms of a very definite nature that I have heretofore been unable to call by any name. I have been content with the general sweeping diagnosis of an internal derangement of the knee joint. The definite symptoms I speak of are these: Not the grating that accompanies damage to the bones, but a creepy feeling and soft crack which occur when you move the patella, as if it were rubbing over some pulpy substance. I should like to ask Dr. Meisenbach, in closing the discussion, to say a word about his method of approach to this region.

Dr. J. T. Rugh, Philadelphia: It has been my privilege to operate in about a dozen of these cases. To me the symptomatology is rather clearly defined, and it constitutes in my experience a distinct condition which in the vast majority of cases requires surgical interference for its correction. These cases, as I find them, usually present an intermittent hydrops; that is, there will be an injury to the joint from overuse of the part or from a blow or a fall, and this will be followed by an effusion into the joint, which subsides after a few days. After the subsidence of this joint swelling, examination of each side of the ligamentum patella will give a sensation as of a substance rolling away from the thumb. One can feel the mass slipping under the thumb. My plan has always been to make a lateral incision, either internal or external or both, according to the conditions present, and through that incision remove this ligament. It is very easily done with a pair of scissors. The result has been functionally perfect.

Dr. Roland Meisenbach, Buffalo: In answer to Dr. Fassett's question, I might say that the lateral incision has the advantage that in most knee joints by this route the alar ligaments are immediately exposed and are easily reached without exposing very much of the knee joint itself. It also

Digitized by Google

has the advantage that in many of the knee joints there is very little hemorrhage by this incision. It is essential to take further precaution to prevent hemorrhage within the joint, also to prevent hemorrhage before opening the capsule. I would like to emphasize the fact that the capsule should not be clamped with hemostats, but should be held apart with silk retractors. I have always felt that the alar ligaments have been very much neglected, and I was glad to hear Dr. Rugh confirm this belief. I think that in many of our knee joints we obtain a history of intermittent symptoms, but these intermittent symptoms do not necessarily extend over regular times, as in intermittent hydrops. In my earlier cases I believed that the hypertrophy of the alar ligaments explained intermittent hydrops, but later experience has taught me differently. I wish also to emphasize the fact that patients suffering with hypertrophy of the alar ligaments assume a peculiar gait with a view of protecting their joint on all occasions. I believe this is partly psychologic, and partly due to the fact that the pain comes on suddenly and they expect it, but are unable to know exactly what motion of the knee joint brings it on. In some of the cases one should be conservative enough also to have the different laboratory tests made, and one should be on the lookout for other conditions, in which the hypertrophy of the alar ligaments may be a residual hypertrophy due to a general diathesis.

Digitized by Google

MODERN TREATMENT OF FRACTURES OF THE LONG BONES FROM THE ORTHOPEDIC POINT OF VIEW

WITH CLINICAL OBSERVATIONS AND CONCLUSIONS

J. W. COKENOWER, M.D.
DES MOINES, IOWA

The treatment of fractures of the long bones has been given much attention during the past few years, by the general and orthopedic surgeon, relative to the closed and open methods and the use of nails, wire, plates and bone grafts. No matter how scientific and modern the work, and how successful the results obtained, it is absolutely necessary that the bones be immobilized and held in position by some kind of mechanical appliance whether the treatment be open or closed, or both. As orthopedic surgeons give more attention to the latter than surgeons do, it would be but natural to conclude they were as able, if not more so, to do such work with better clinical functional results.

The direct fixation of compound fractures, when the bones are exposed and cannot be held in position by splints, has become in general use by surgeons of large experience, but when the matter of simple fractures is presented for consideration, there is a lack of uniform opinion, whether the fixation shall be by open or closed method.

The difficulty of the open method in many cases, the unsatisfactory adjustment of fractured bones by manipulation and the uncertainty of fixing and maintaining the broken ends in perfect alignment, prompts one to decide in favor of the open method, augmented by such orthopedic mechanical devices as will positively hold in perfect position the fractured bones.

Digitized by Google

That this is the best treatment no one will doubt, when done by a good surgeon with operative and mechanical skill backed up by perfect asepsis, and any lack of the latter is more fatal to perfect union than a similar error in technic in abdominal surgery; for in this the lymphatics are less able to cope with ordinary infections, than in the peritoneal cavity, and in no other domain in surgery are aseptic errors so often punished by failure.

It is necessary to divide our simple fracture cases into two groups: those that can be treated in a hospital and those that can not. The greater number of cases have always been treated by the general practitioner, and his functional results are usually good and satisfactory to the patient, even though a roentgenogram may show an imperfect alignment and defective judgment, hence, the general or orthopedic surgeon can never hope to control the exclusive management of fractures and the open treatment can never become universal.

It would not be advisable to do an open operation in all simple fractures because many of them can be perfectly adjusted by manipulation, under anesthesia, and accurately held in position by proper retentive dressings. A Colles fracture of the wrist can nearly always be reduced if the fragments, which are often impacted, are unlocked by increasing the deformity before attempting reduction. A Pott's fracture of the ankle joint will often be set with a snap if traction is made in the line of the deformity, and many transverse fractures of the femur show little tendency to displacement when proper mechanical appliances are used.

Therefore the most enterprising surgeon would hardly be justified in stating that all simple fractures should be treated by the open method, even in the face of Sir Arbuthnot Lane's statements that they should, and he uses in all his open operations the

Digitized by Google

same external retentive and fixation appliances to reinforce the strength of his plates, screws and clips, that are used in the nonopen treatment.

The fixation appliances used in the open method can be depended on only for a few days, because of the pathologic softening of bony structure surrounding the peg, screw or wire, and the bones become loose unless augmented by a carefully applied external splint. This fact of softening has been found in cases in which the open method has been resorted to in from ten days to six weeks after the fracture and the ends of the bones were too soft to hold the pegs or screws. This softening, on investigation by the Roentgen ray, at different times proved to be a pathologic one, which accounts for the many cases of nonunion of bones that had been accurately adjusted and properly retained.

Hence, if it should be found that reduction cannot be accomplished in the usual way, or that coaptation cannot be maintained, the open or operative method should at once be resorted to before the bones have undergone reparative softening.

The fact that screws and wires do not maintain and hold until bony union is complete has been shown in all cases in which it became necessary, early or late, to remove them, either from infection or because of detachment because of softening bony structure.

I have used the bone-graft treatment of Drs. Murphy and Albee and obtained good results in all cases of nonunion wherein such treatment has been used, especially when the inlay of grafts is cut and inlaid in such a manner that each stratum of periosteum and bone of the fracture meet and approximate a like stratum of the graft introduced. This can usually be done, after which not only will union occur, but the individual cells of both graft and bone will be stimulated, and overgrowth and callus formed with strength equal to, or exceeding that normal to the part.

Digitized by Google

It has been found that when an open operation was attempted in from two to four weeks after injury, in cases of oblique and in some cases of transverse fracture of the femur, leg, arm and forearm, with tendency to overlapping, that it was difficult and sometimes impossible to overcome the muscular contraction. When this occurs an open operation should be done, as soon as the patient can be brought into favorable environment, because this is the class of cases that give most trouble and this condition is the cause of nonunion.

It has been my custom to give an anesthetic in all cases in which manipulation is too painful or muscular rigidity is marked and endeavor to secure crepitus, if possible, that I may be more certain that no muscle, fascia, or loose fragment of bone is interposed between the fractured ends of the bone. While it may be true that nonunion is often due to defective innervation, diseases of the bone, syphilis, or excessive rarefaction, we must admit that a defective relation of the fragments is the prime factor to be considered. However, an entirely different condition may produce nonunion because of a lack of proliferation of soft and bony cell tissue.

I have seen several cases in healthy and vigorous young persons in which there existed little or no displacement, and in which immobilization was easy and complete, that ended in nonunion, due, no doubt, to a restricted local reaction and defective hyperemia with insufficient nutritive and reparative local reaction, which easily yielded to vigorous friction of the ends of the bones.

The fear of converting a simple and noninfected fracture into an open and possibly an infected one was so great that, rather than take the chance of creating an infected compound fracture, one was willing to take some chance of obtaining a fairly good functional result, even though the Roentgen ray might

Digitized by Google

show imperfect apposition. Hence, we are no longer able to cover up our mistakes because the Roentgen ray will show them. My experience has been that when the Roentgen ray shows that the bones were in proper apposition in the beginning and union complete in the end of treatment, and that no mistake has been made, no matter how seemingly unsatisfactory the results were before this knowledge was obtained, the psychologic as well as the physiologic functions always improved afterwards.

I have used the two extremes in the open and closed methods of treating fractures, but my functional results were not always satisfactory, which prompted me to use the medium and extremes conservatively. Since doing this not only were my functional results more satisfactory, but the general contour, in the normal axis of the limb, was better, which prompted the following conclusions:

1. All fractures that can be adjusted manually and can be fixed in a position that will insure a good functional result, even though the Roentgen ray shows a lack of perfect end-to-end approximation, are to be treated by the closed method.

2. In all fractures with marked deformity, such as overlapping, angulation, lack of contact of fractured surfaces, evidence of soft or detached osseous tissue between the ends of the bones, and especially compound fractures when it is apparent that union will not take place, the open method is invariably used.

3. The open method being used, I prefer the Lane plates, when sufficient smooth bone surface for their attachment can be obtained. When this cannot be done, prepare the ends of the bones for good and satisfactory apposition. If not sufficiently jagged make at least one lateral and one anteroposterior dovetail in the ends of the bones to prevent them from displacement, after which wire, and if proper retentive appliances be used good results should be expected.

Digitized by Google

4. The bone-graft inlay should always be used in nonunion, especially when the pathologic softening of the ends of the bones exists augmented by infection or misplacement of the ends, including soft tissue between them, but not in simple fresh fracture or fractures, to which the Lane plate will be better adapted.

5. The mechanical immobilizing support must be satisfactory, otherwise previous preparation, no matter how good, will be a failure. No rule can be made for the use of plaster of Paris and splints, except that the former should not be used when any swelling is present and should never be left on too long, because atrophy of the soft tissue may do the immobilization harm; but splints, when properly made and adjusted, are always satisfactory.

6. The Roentgen ray should be employed early whenever possible, to aid in a proper estimation of the extent and location of the fracture, to determine whether the open or closed method should be used, and if the former, it should be done promptly. The Roentgen ray should again be used, when the patient is discharged, for anatomic and functional reasons.

Utica Block.

ABSTRACT OF DISCUSSION

Dr. Roland Hammond, Providence, R. I.: I agree with most of what Dr. Cokenower said. I believe that as orthopedic surgeons we have a great opportunity in the treatment of fractures. The orthopedic mind naturally inclines to the solution of mechanical problems such as are involved in the treatment of a fracture. There are three requisites necessary in the treatment of a fracture: (1) a complete Roentgen-ray study of the fracture before and after reduction; (2) the use of anesthesia in practically every case; and (3) at times a consultation. We can no longer treat a fracture according to textbook methods. Every case is a separate study, according to the conditions as shown by the Roentgen ray. In treating a fracture I always make a roentgenogram so as to show what the condition is. Then under ether I reduce the fracture. Take a plate while the patient is still under ether, and if it shows proper reduction, put the fracture up. If not, I keep on until I

Digitized by Google

have proved that the fracture can be reduced by further manipulation, or that it cannot be reduced and may require an open operation. I think a good many of the fractures of the long bones, especially of the femur, are not properly reduced, because countertraction is overlooked. Traction is employed, but countertraction is not, and in setting a fracture of the leg, especially of the femur or of both bones, if the limb is put on to a frame where traction can be applied with a windlass, with counterpull in the perineum, you can put on the plaster or whatever apparatus you choose to employ, without depending on an assistant to hold the leg. The windlass will hold the part firmly so that the plaster can be properly applied. I disagree with Dr. Cokenower as to the use of Lane plates. I believe in most cases they can be dispensed with, and if any form of fixation is to be used, it is much better to employ the bone graft. I think with proper external fixation most fractures can be held, but the metallic internal splint has already given too much trouble in this country to warrant its further use, except in very exceptional circumstances.

Dr. Roland Meisenbach, Buffalo: I wish to bring before the Section's notice a point which I have observed in connection with fresh fractures and anesthetics, namely, the fact that with nitrous oxid and oxygen as an anesthetic, one does not get complete relaxation; that is, the muscular tone remains fairly tense. This is of great value in setting a fresh fracture, either with or without incision; namely, the semicontracted muscles tend to hold the fragments in place and act as a lock, as it were; whereas, if an ether anesthetic is given, complete relaxation will often tend to a flail-like condition at the point of fracture. If you can reduce your fracture without complete relaxation, in manv places you can approximate it and it will hold. I think this also accounts for the fact that many fractures, especially of the wrists, are successfully reduced without an anesthetic.

Dr. J. W. Cokenower, Des Moines, Iowa: I cannot agree with Dr. Hammond that it is necessary to cut down and use a bone graft in a healthy bone or fresh fracture and one that can be put in apposition. It certainly ought to be held in position by the proper mechanical appliances; so that bone grafts as well as Lane splints are the proper things only in properly selected cases. With the attention that orthopedic surgeons of this country have given to bone surgery, they are absolutely and justly entitled to treat fresh fractures, and in doing so there will be less trouble afterwards and much less litigation. I believe that the time will come when a majority of fresh fractures will be referred to orthopedic surgeons, because in the end, results are to be considered and the public is the umpire of our work. I think they will decide in our favor, because we are able to do the work and do it right.

Digitized by Google

FRACTURES

NEW IDEAS AND NEW INSTRUMENTS

H. R. ALLEN, M.D.
Professor of Orthopedic Surgery, Indiana University School of Medicine
INDIANAPOLIS

It is fortunate that a paper on new surgical treatment of fractures does not imply that all fractures shall be treated by open surgical methods. However, it does imply correctly that neither the closed nor open methods are as efficient as they should be. Within a short time the entire subject of closed treatment will have to be rewritten on a selection of entirely different basic mechanical principles.

The conventional methods still in practice, since the days of Columbus, when the world was flat, depend on most excellent mechanical principles. These principles, sound and unalterable as they are, happen to be absolutely inappropriate for the mission expected of them. Their absolute soundness does not guarantee their appropriateness any more than the unsoundness of ancient argument guaranteed for us a flat earth. Man alone is responsible for the misuse of judgment in selecting inappropriate ways and means.

In new open surgical treatment it is naturally consistent to find a composite mixture of modern sparkling ingenuity within the calcified shroud of St. Christopher. Surgical ingenuity is not efficient because of ingenuity alone. It must be coupled with additional qualities in order to be sufficient. A Lane plate for instance, involves a trace of ingenuity; but, in my opinion, to leave a foreign body permanently embedded in a wound borders on bad surgery, whether that permanent foreign body be a pair of forceps or a

Digitized by Google

pair of spectacles or a bunch of screws, loose or penetrating the holes of a steel plate. To leave a foreign body permanently embedded in a wound is at least an unnecessary procedure.

Up to the present time we have seen outside and inside bone splints of various kinds. Those outside remain dry, those inside wet, of course. Now comes a new variety of amphibious appliances existing both inside and outside at the same time. There are several varieties. A few will illustrate the generic qualities of all. They are protruding nails elevating, depressing and anchoring cleats, protruding wire loops thrown around bone and secured to an outside straight edge, and, lastly, the bone gimlet with its low melting alloy handle. All of these devices are amphibious, that is, they extend from bone out through soft tissues into the open air. They are all silver or silver plated, with polished smooth sides. After union occurs, they have served their purpose and are removed without secondary surgical operation. They do not remain as permanent foreign bodies. To install them, the length of incision and the amount of dissection about the bone is greatly reduced. They do not come in contact with the fracture zone. They do not compress periosteum or bridge across fractured areas. They are applied remote from the fracture zone unless desired to traverse it. They are not inadjustable, but at all times provide excellent outside control over inside conditions, and up to the present time, no case of infection can be attributed to them, although in my hands and in the hands of others, they have passed through external pus areas without producing deep or internal infection.

To say that children and patients of all ages do not suffer or complain while wearing these transfixing or protruding devices would at first suggest straining a point in veracity; but, on second thought, you may correctly compare these devices to deep sutures. If your patients do not complain of pain from their

Digitized by Google

deep sutures, they will not complain from these protruding devices, because, at the time of their application, all soft tissue strain is relieved by overstretching or by insignificant incision. Furthermore, a suture has a compression and constriction element, which is here absent. From the foregoing suggestions and other good reasons and from my past and from your future experience, I have dared to make the statement that this method is comparatively free from pain.

While waiting for the first case of infection, it may be well to recall that, of all safe drainage material, nothing surpasses silver, and of all known methods of drainage, none excels through-and-through drainage. The combination of through-and-through silver drainage may play a very important part in the absence of infection.

The use of protruding nails, cleats, etc., and wire loops secured to outside straight edges is self-evident after a moment's observation of the illustrations, Figures 4, 5 and 6. My practice with the wire loops is to use soft steel wire silver plated. The loop passing around the bone should never constrict the bone or the periosteum. It should have as near 180 degrees bearing on the bone as possible. As it enters the skin it approaches the bone at a tangent, passes 180 degrees around the bone, and then leaves as a tangent out through the soft tissues and skin to its outside straight edge attachment. In case more bearing is essential, at least 60 degrees of unrestricted circumference should be provided. In this event the wires must be twisted five times on each other to the right. Then in order to remove them, after bone union occurs, they are to be untwisted five times to the left, and the loop pulled out (Fig. 5, *A, B, C, D, E, F*). In employing silver plated wire nails, one should be sure to use very long thin "finishing nails." The heads protrude far enough so that a good hold may be taken on them with extracting forceps, as they sometimes become tightly *embedded* (Fig. 4 *B*).

Digitized by Google

The flat silver plated drills with their alloy handles may be used with or without an exploratory incision over the zone of fracture. Usually, I make the incision in order to secure an absolute and accurate reduction, and I should announce here that absolutely accurate maintenance of reduction is possible with this system of treatment. The bones are brought into absolute reduction, the bone adjusting lever being used if necessary (Fig. 2 *D, E, F, G*). The exploratory incision provides digital and ocular inspection. The bone pins are passed through the bone an inch or so on both sides of the fracture zone. While the reduction is held absolute and accurate, the low melting handles are brought into line, touched with the soldering iron and the ends are fused together. The operator releases his hold on the bones, and they remain locked in absolute reduction as if by magic. An alloy button is then cast on the end of each drill, and a segment of the alloy fused to each button, thus affording additional stability in locking the broken ends tight together. The exploratory wound is sutured, and a wet antiseptic dressing is applied over it and around the projection of each transfixing pin. It must be remembered that no two pins should lie in the same plane. It is difficult to put them parallel and in the same plane. Fortunately, the easy unparallel way is the correct way, and the more the drills depart from parallelism, the more secure this system becomes. If a carpenter desires to make a studding stand erect on a floor he does not drive all of his nails parallel or in parallel planes. He "staggers" or "toe nails" the nails into place, and the studding "stays put." A Lane plate and all similar devices depend on parallelism of screws (Fig. 2 *A, B*). Furthermore, the screws have only from 1/16 to 3/16 inch bearing for their threads. The long end of the screw projects into the bone canal or fragile cancellous tissue, and is totally and absolutely devoid of function. The transfixing pins have bearings in both layers of hard bone, which are

Digitized by Google

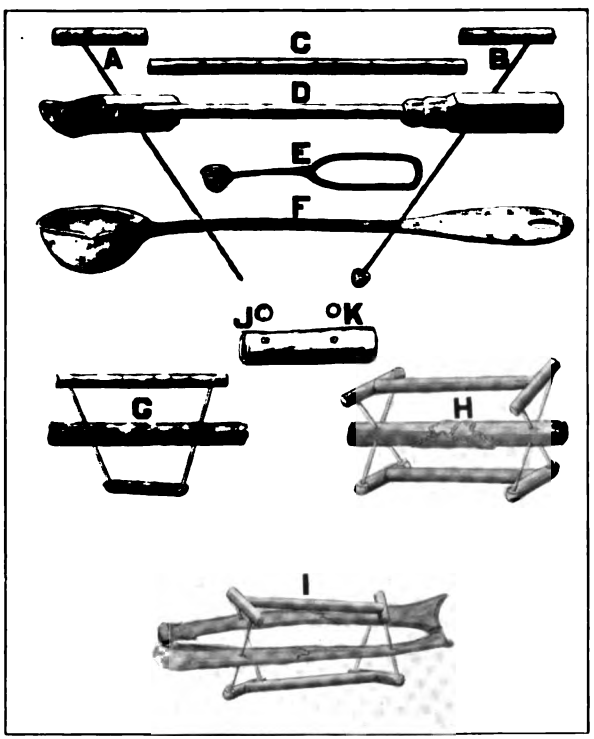

Fig. 1.—*A*, *B*, bone pins with low melting alloy handles (160 F.). The drill point on *B* has cast on it an alloy button used to couple it with another drill point. *C*, a bar of low melting alloy for joining drill handles in case they are not long enough to reach each other without such extensions. *E*, ladle for casting alloy buttons on points of drills. *F*, a large ladle for melting alloy over flame or in hot water. *J*, *K*, different shaped holes, *J* due to reciprocating movement of flat drill, *K* due to continuous rotation of any form of drill. *G*, diagrammatic scheme for holding fragments of broken bones in accurate reduction. The two pins do not lie in the same plane. Each represents a scheme for holding fractured ends by using constant normal distance rods. *I*, fracture of radius and ulna. Note the process of preserving normal length and proper separation of fragments. No rotation, angularity or overriding is permissible under this system.

Digitized by Google

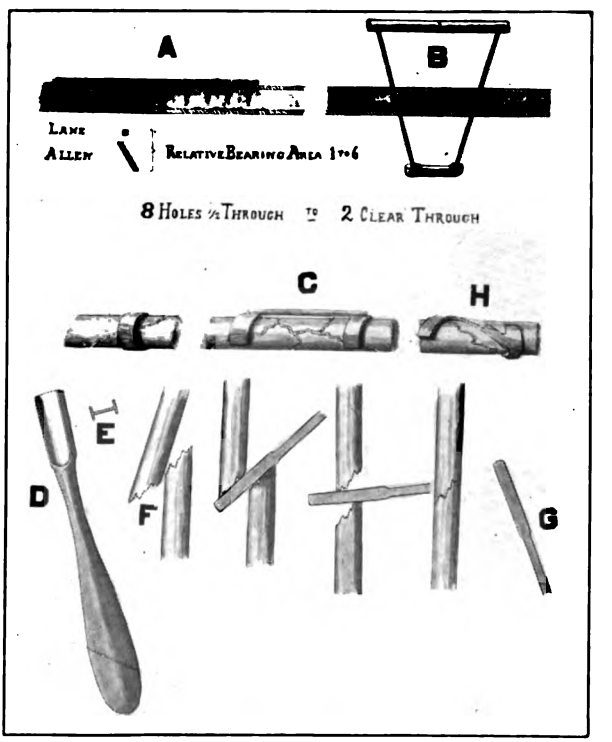

Fig. 2.—*A*, Lane plate with eight screws all parallel; only one-sixth of their entire length traverses hard bone. The portion within the canal of the bone is hopelessly without function. *B*, Allen system, providing long, hard, bony bearings and providing outside control over inside conditions. *C*, bone cleats welded cold on bone. *H*, metal welded on ordinary calling cards without burning the cards. *D*, Allen's bone-adjusting lever. *E*, cross-section showing the I-beam features which prevent bone fragments from slipping laterally. *F* to *G*, methods of using lever in overriding bone displacement.

Digitized by Google

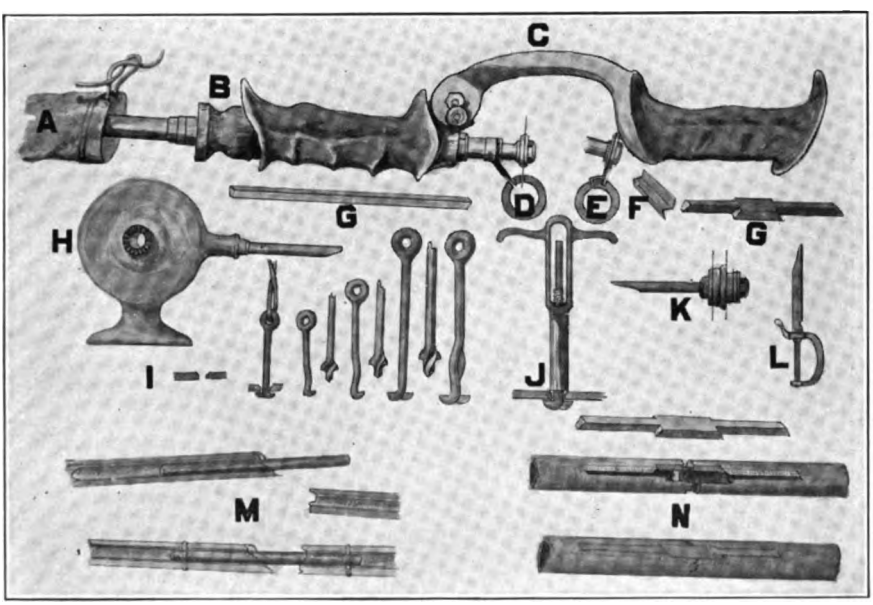

Fig. 3.—*A*, *B*, *C*, *D*, Allen's bone saw assembled in the process of cutting a wedge-shaped bone graft by one of its two methods. *A*, sterile sleeve to cover driving cable from motor to saw. This saw may be driven by any motor desired; hand-driven motors are by no means to be overlooked, as they will work regardless of electrical conditions. *B*, junction of driving cable from motor to this draw-knife or spoke shave type of saw. *C*, movable or lockable left handle. *D*, wedge-shaped cutting device assembled. *E*, *F*, different devices for cutting wedges. *H*, dowel pin cutter. *I* to *J*, elevation and depression tools with their countersinking shouldered drills. *K*, adjustable double saw. *L*, routing tool attachable to saw. *M*, telescopic bone grafting scheme. *N*, double wedging automatic locking bone graft.

Digitized by Google

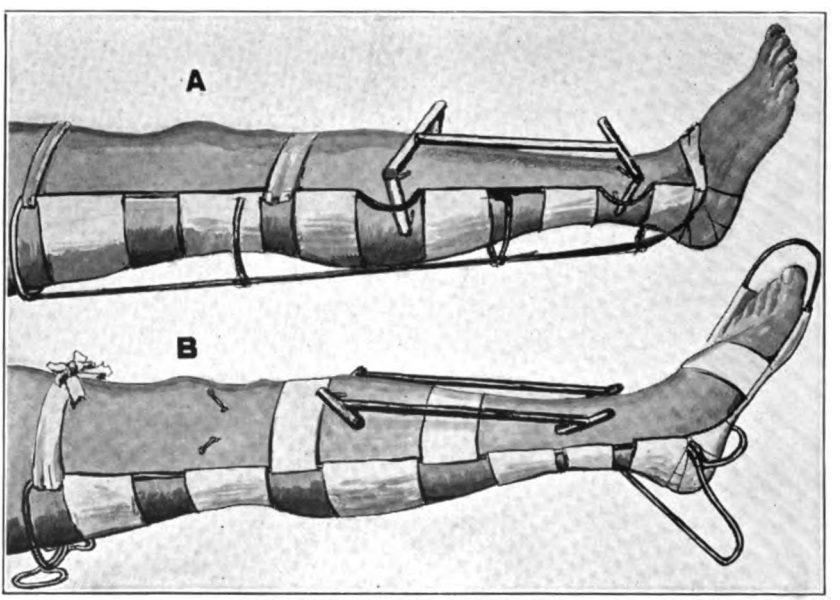

Fig. 4.—*A*, wire and adhesive plaster brace used in connection with bone pins and constant distance rods in treating a shattered tibia and fibula. *B*, use of protruding nails in securing broken off portion of the tibial head; also constant distance rods and bone pins with low melting alloy handles. Note that the wire brace among other duties keeps the bed clothes from resting on the foot and also prevents the leg from rolling.

Digitized by Google

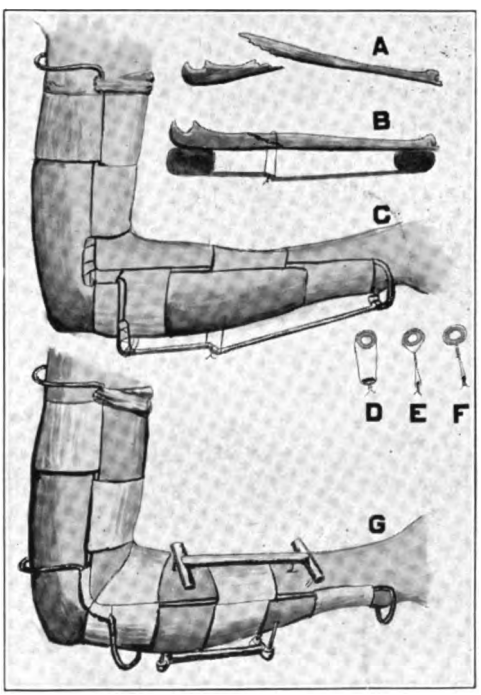

Fig. 5.—*C*, wire and adhesive plaster braces used in connection with the wire loop method of treating fractures. *A*, *B*, conditions of fracture and the three lever points essential to fixation. *G*, wire brace and bone pins employed in fracture of both radius and ulna.

Digitized by Google

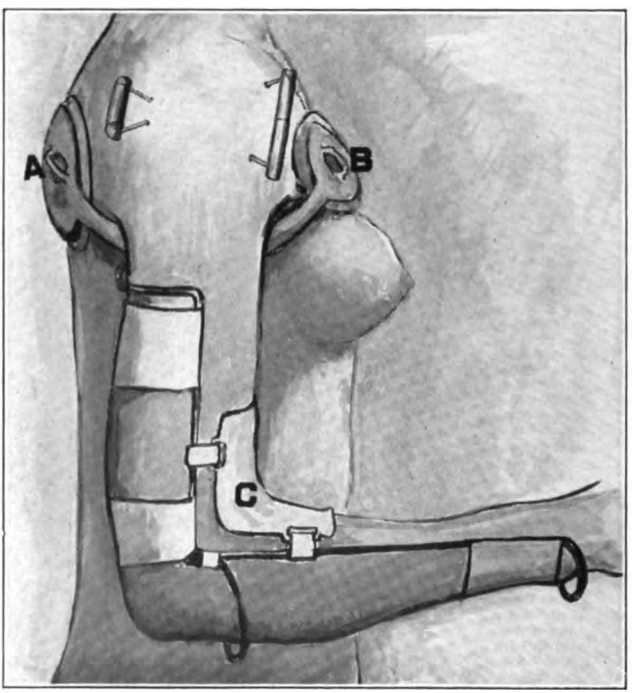

Fig. 6.—Brace and bone pins for fracture of head of the humerus. The pins prevent rotation of the fractured head on shaft. Absolute and accurate maintenance of reduction is possible by this method. The crutch under the arm and the anterior elbow plate provide fixed points for the application of fixation forces. In case the axilla is burned or from other causes cannot be used for superior fixation points, adhesive bandages upon the back, abdomen and side attached to loops *A* and *B* constitute a stable superior fixation base which may be depended on.

Digitized by Google

more remote from each other than the diameter of the bone. This is due to the fact that the drills pass obliquely through the bones.

Every man who has bored round holes in bones for wires or screws or nails knows from his roentgenograms and secondary operations that in about a fortnight these round holes have become oval or egg shaped. With a Lane plate there is no chance to take up the slack. With the transfixing pins one has absolute outside control over inside conditions and can take up as much slack or correct as much rotation as desired without a secondary surgical operation. One merely melts or cuts the handles apart on one side, separates or rotates them as one likes, and then fills in the gap between the handles with a drop or more of the low melting alloy. When the Roentgen ray shows bone union, one is at liberty to melt the alloy off of both ends of the drill rods, paint the rods with iodin, and allow them to dry thoroughly, when they will be easily pulled through the holes originally made. These holes, it must be remembered, form a free working hole through both hard and soft tissues. Gentle traction with the fingers is sufficient to extract them. The alloy melts at about 160 F., so that warm water will melt it; or if one is in a hurry, the knife-bladed soldering iron may be used (Fig. 1 *D*). Twist drills and continuous rotation with flat drills should not be used; they should be sent through the bones with a reciprocating movement passing through a working arc of about 165 degrees and not through as much as 180 degrees (Fig. 1 *J, K*). In this way two things happen: the nerves and blood vessels are pushed aside, and the hole through the bone is not a complete circle, but has a pair of internal opposed bone ridges which guarantee a tight fit against the drill shaft as shown in the illustration. A twist drill with its uninterrupted rotation not only drills a round hole, but also will wind up and extract loose soft tissues on itself.

Digitized by Google

Concerning bone grafts, I desire to present two methods. One is known as the telescopic bone graft and the other as double opposed wedge graft, which automatically locks itself and the fractured bones together (Fig. 3 *M, N*).

If a portion of a shaft of a long bone is absent, the gap may be bridged as follows: A deep canal or tunnel is drilled into the axis of the longer fragment, and a shorter canal into the shorter fragment; a long dowel pin is turned up to fit the bored canal, the dowel pin slipped down into the long canal, the two canals brought into line and the dowel pin worked toward and well into the short canal (Fig. 3 *M*). The short end is pinned with a transverse bone pin, and then when the broken bone is pulled to its normal length, the long telescoped end is secured with another transverse bone pin as shown in Figure 3 *M*. If desired, the dowel pin need not be circular, but may have a flat side with periosteum still intact. The ends of the periosteum may be stripped up and put in contact with the periosteum at each end of the fracture.

Another interesting bone graft is the double opposed wedge graft. It involves the use of a wedge-cutting saw, like the one presented, which has two different ways of cutting wedges, as shown in Figure 3 *A, B, C, D, E, F, G*. The male wedge and the female, or the positive and negative wedges, must be accurately cut. The ends of the wedges are cut with opposing wedges or bevels. The broken bone is pulled far enough apart to let the wedge drop into place (Fig. 3 *N*). The traction is then released, the soft parts drag the bone fragments tight into place, and by the double opposed keystone or opposed wedges the bones are locked in place, requiring no bone pins to hold them together. Before attempting this operation, one must become adept in accurate bone cutting. In this form of graft the periosteum may be left intact throughout the entire length and breadth of the graft.

Digitized by Google

The last method of bone cleating may have some novel features of unusual interest. It consists of a process of welding any desired metal on a bone in the form of a cleat or key or wedge or "C" clamp or any pattern desired. The metal to be used is atomized and the minute particles of metal are impelled against the recipient area until they are welded cold on each other to any desired thickness. The specimens presented to you show the bone is not burned. The periosteum of one bone is still intact, although it is scraped away from the other bone. The pasteboard calling card has metal welded on it, although the card is not burned (Fig. 2 *H*). Around one of the bones a German silver band is welded; about the other is a band first of steel, then copper and then brass; then on this practically any other metal may be welded on cold. Interesting as this may be, I cannot recommend its use, because any foreign body permanently left in a wound is, I believe, not only unnecessary but borders very closely on bad surgery.

Concerning the splints used in connection with all of these new methods, I cannot refrain from making an appealing request. Please use wire and adhesive plaster braces or splints. They are simple, light, strong, sanitary, cheap, durable, adjustable and betray the first requisite of new fracture work. If a man is not mechanic enough to make these little things, he is unfit to attempt accurate fracture work. When you go home buy some tinned steel wire and practice making them. They do not hide the work you should be proud of, but leave it always open for free examination and inspection. You can treat other conditions aside from fractures with wire and adhesive plaster appliances. They are appropriate to many deformities and make excellent framework over which gauze may be stretched in employing open air treatment. The gauze is kept from the wound or lesion and the gauze is a filter against dust. When you learn to use them,

Digitized by Google

no one can lead you back to plaster of Paris. In the new treatment of fractures I most certainly include these new wire braces among the new ideas and new instruments.

ABSTRACT OF DISCUSSION

Dr. P. C. H. Pahl, Los Angeles: I read an article by Steinman in which he said he produced traction on the tibia, fibula and I think also the femur by means of nails passed through the bones. It has occurred to me many times that there were cases of fracture of both tibia and fibula and of the femur in which it was very difficult to produce traction by the means of adhesive plaster. Sometimes the adhesive plaster irritates, and sometimes the tissues are lacerated. When there are many fragments, bone grafts and Lane plates are out of the question; traction then is the only thing, and in order to gain this I have made what I have called a spine tractor—two thorns that go into the bone through little incisions, and then traction is applied. I have done this in twenty-one cases. I am very sorry to say that two of the patients subsequently died, although I did not personally have absolute control over them. It is possible to produce traction, and I have produced as much as 65 pounds in the beginning and gradually reduced this to twenty-five pounds, the treatment lasting for two months and a half. I did this in a Mexican who had a fractured femur, in the upper end, in which there were five fragments. Personally, I have not had the experience which warrants cutting down to the bone on a man who has five fragments in his femur. In this case I put the spines into the condyle of the femur, making the traction vertical, with the leg flexed. I have never been able to make traction vertical with the knee extended, but with the knee bent, it is possible to do so. The first traction was so much that the patient was lifted up in bed, and, of course, there was much lack of apposition, but finally the fragments came into proper position, and the man got a functional leg. What Dr. Allen says about positive fixation has also occurred to me. I have an instrument which I call a "multiple spine splint." I made one for the tibia. I place two spines on the lower end and two on the upper end of the fibula and tibia. I make, if necessary, a small incision over the fracture, reduce the fracture, and then tighten these four spines, or two sets of spines, which really make a bone vise. These cases were all satisfactory. I must say, however, that prejudice against them is very great, and in a municipal hospital where there are many men, it is almost impossible to use them.

Digitized by Google

Dr. H. M. Sherman, San Francisco: I was much impressed with one statement which Dr. Allen made, and that was the fact that he never got infection. Now a long time ago I began to nail the neck of the femur in fractures of that part of the skeleton, and it always became infected if the nail head was on the surface. Longer ago than that, Parkhill devised this scheme of fastening bones, but all the openings which passed through the skin became infected. The Lambotte scheme, and all the variations and modifications of that, where a drill point or a nail goes through the skin and then into the deeper tissues and remains there, always call for infection. We are now making what we call skeleton traction by a pin through the femur, instead of a Buck's apparatus, and it is a method by which we always get local infection. Dr. Allen says he puts those bits of wire pegs through an infected area into the deeper parts, and never gets an infection. I want him to tell us how he avoids infection, because if he will tell us that, he will put into our hands not only his own apparatus, ingenious as it may be, but he will give us the most important piece of information in his possession—one for which surgery is anxiously waiting—and we will all begin to look around for mechanical ideas and will be able to take care of fractures as easily as he.

Dr. Allen cites the fact, which is perfectly well known, that a screw in a bone bearing weight always causes a necrosis of the part of the bone against which it is pressing so that the holes become oval; and they become even more than that; they become quite large places. I put two screws in a dog's bone, setting them in the bone very firmly, about an inch apart, and then put a little elastic band around them and sutured the wound. The wound healed and in about a month I opened it and found that both of those screws had been pulled out of the bone by that little elastic. The pull of a little piece of india rubber was sufficient to make a round hole oval, and then to pull the screw out of this oval hole. Does not Dr. Allen get the same kind of pressure, absolutely, with the wire pegs which he puts through the bones, so that we can expect the same results under these circumstances? These are things I should very much like to have Dr. Allen explain to us.

Dr. H. R. Allen, Indianapolis: Dr. Pahl suggests the inadvisability of cutting down on a femur fractured in five places. Such a case should be treated by the application of fixation forces for fixation purposes. If any fragment remained uncontrollable under the closed method it could be cut down on and treated by the open application of fixation forces for fixation purposes. We must not delude ourselves by thinking that the irregular muscle force is in any sense a balance or counterpart of a constant force. The appli-

Digitized by Google

catiocation of a constant force through a weight and pulley implies motion of parts desired to be kept quiet and fixed. The application for fixation forces implies absence of motion and the presence of fixation. To oppose the constant force of gravity by the irregular force of muscle necessarily leaves a plus or minus balance of force resulting in motion. Fixation forces are not concerned with motion. Dr. Sherman presents two good points: one refers to the application of a rubber band and the other to the possibilities of infection. A rubber band, of course, while inactive is inert, but duractivity it represents a constant force and must be dealt with according to its own generic qualities of constancy. Concerning infection, or rather the absence of it, I am inclined to believe that my good fortune in this regard has been influenced possibly by the technic employed. The operation field should be scrubbed with soap and water, rinsed with mercuric chlorid solution, then washed with alcohol and painted with iodin, which is removed with ether. Every instrument, in fact everything, is wet with mercury solution while it is near or in contact with the wound. Each wound is thoroughly irrigated with mercuric chlorid solution, and after suturing with mercuric chlorid soaked silk a wet mercuric chlorid dressing is applied and maintained as a permanent dressing. I believe in the use of mercuric chlorid. I also believe in through and through silver drainage.

Digitized by Google

THE EXPERIMENTAL TRANSPLANTATION OF THE EPIPHYSIS

WITH OBSERVATIONS ON THE LONGITUDINAL GROWTH OF BONE *

S. L. HAAS, M.D.
SAN FRANCISCO

No subject in bone surgery has been so extensively investigated during the last few years as has that concerning the transplantation of bone. As a consequence of these studies certain of the resulting changes that take place after transplantation have been solved, but there is still lacking a uniform agreement relative to some of these processes. From the clinical standpoint, however, there is a universal acceptance as to the successful applications of bone transplantations. Thus for the filling in of a bone defect, for the curing of a pseudo-arthrosis, for the producing of an ankylosis of the spine or the joint, and for the correcting of a nasal and other deformity, the transplantation of bone serves a very definite purpose. In all of these conditions a piece of diaphyseal bone with its periosteum is selected for the transplantation material.

From a practical standpoint it is not absolutely imperative that a transplant remain entirely alive and its cells be capable of proliferation, although if it possess these properties it is more likely to be successful. If it be demanded, in addition to the mere passive function of filling in a defect or acting as a framework for the ingrowth of neighboring bone, that the transplant must also possess the active property of increasing in length, within itself, then it is absolutely essential that its cells remain alive and

* From the Pathological Laboratory and the Surgical Pathological Laboratory of Leland Stanford, Jr., University School of Medicine.

Digitized by Google

be capable of dividing and extending in a linear direction.

As the longitudinal growth of bone is due to proliferation of the tissue at and adjoining the epiphyseal cartilage, it is necessary to include that part of bone in a transplant when an increase in length is desired. It is not alone sufficient that the cells of the part remain alive after transplantation, but they must retain their ability to multiply in such a manner as to further increase the length growth. In such a case there is an additional requirement of the transplanted tissue besides the mere supporting property of diaphyseal bone. This additional requirement demands that the tissue retain the active function and inherent property of the normal epiphysis to increase the length of bone. The epiphysis is to be considered as a highly specialized tissue which will undoubtedly respond to the general laws of regeneration and transplantation, in that the more highly differentiated the tissue and the more dependent on its blood, vascular, lymphatic and trophic nerve supply it be, the less likely is the possibility of the successful transplantation of that particular tissue. On the independency of the epiphysis to withstand these losses depends its functional transplantability.

It is surprising that this interesting and complex subject has not been more extensively investigated. Aside from the scientific problems connected with such a study there are offered numerous opportunities for clinical applications of a successful method. Instances of such possibilities are found in cases of destruction of the epiphysis following tuberculosis and acute infection of the bones in early childhood; in certain neoplasms necessitating the removal of the epiphysis, in congenital shortening of the limbs, in defective growth after infantile paralysis, in destructive traumatic injuries of the epiphysis, in rachitis, and in congenital dislocations of the hip. Since the reports of transplantation of joints by Lexer, Kuttner

Digitized by Google

and others, it would be very important to know the behavior of the epiphysis after transplantation before attempting such procedures on growing individuals.

From the optimistic conclusions of Rehn and Wakabajashi[1] in 1912, one would be entirely justified in attempting to perform the transplantation of the epiphysis in order to correct any of the above-mentioned conditions when there was loss of the function or the destruction of the epiphysis. These investigators performed homoplastic transplantations on two months old rabbits of the same brood, using the upper end of the radius including the epiphyseal cartilage. They concluded from their experiments that the epiphyseal cartilage after homoplastic transplantations retains its full life properties, showing no evidence of degeneration, and from the very first took over the function of its resected predecessor. These conclusions cannot be accepted without comment, as they were drawn from experiments in which the proximal part of the radius was transplanted, the epiphysis of which shares only a small part in the production of the length growth and therefore a failure of its functions would not be very noticeable when compared with the marked activity of the distal epiphysis. They have relied entirely on a comparison of the roentgenograms of the two feet which were only taken at the conclusion of the experiment in order to determine the variation in growth. As the place of union was evident in their expermients they could have easily determined, by means of measuring at the time of the operation and at conclusion of the experiments, whether or not the transplanted piece actually increased in length.

In the same year appeared Axhausen's[2] experimental work in which he performed homotransplantations

1. Rehn, E., and Wakabajashi: Die homoplastische Transplantation des Intermediärknorpels im Thierexperiment, Arch. f. klin. Chir., 1912, xcvii, 1.

2. Axhausen, G.: Ueber den histologischen Vorgang bei der Transplantation von Gelenkenden, in besondere über die Transplantationsfähigkeit von Gelenkknorpel und Epiphysenknorpel, Arch. f. klin. Chir., 1912, xcix, 1.

Digitized by Google

in young rabbits. He used the lower end of the femur, thin sheets of epiphyseal cartilage, and patella, for his transplantation material and transplanted them under the skin. He found that the greater part of the epiphysis died and that only that part remained alive which was situated beneath the perichondrium. In the middle part of the epiphysis he noticed degenerated areas, and he claimed that ossification took place only in the cartilage that remained alive. In these experiments there was lacking functional stimulation, and for that reason the results are open to criticism.

The results of Axhausen's work were diametrically opposite to Rehn and Wakabajashi. On the other hand, they agreed to a certain extent, with those of Enderlen[3] and Helferich.[4] The latter investigators, who were the pioneer workers on this particular subject, performed experiments of epiphyseal transplantations as early as 1899. They reimplanted the epiphysis in rabbits, using the lower epiphyseal cartilage of the ulna with an adjoining piece of the epiphysis and the diaphysis. Helferich, from the macroscopic findings, reported that the epiphyseal cartilage under favorable conditions need not lose its property of producing length growth. A lessening of this property might be observed but there was not an entire loss. Enderlen, who made the microscopic study of these preparations, reported that the reimplanted epiphyseal cartilage retained its vitality to a large extent. In agreement with Axhausen he noticed that the best maintained were those parts near the perichondrium, while those at the center showed evidence of degeneration. There was an increase in width of the epiphyseal cartilage due to an ossification coming from the living cartilage. The ulna was retarded in growth and, on that account, caused a bending of the radius.

3. Enderlen: Zur Reimplantation des resecirten Intermediärknorpels beim Kaninchen, Deutsch. Ztschr. f. Chir., 1899, li, 574.

4. Helferich: Versuche über die Transplantation des Intermediärknorpels wachsender Röhrenknochen, Deutsch. Ztschr. f. Chir., 1899, li, 564.

Digitized by Google

Aside from the investigations of Zoppi[5] who found in his autotransplantation of the epiphysis a regular healing in and the formation of new bone, while in his heteroplastic transplantations there resulted a complete failure; and the studies of Galcarzi,[6] who found that there was a calcification of the epiphysis and loss of function in both auto and homotransplantation, there have been no other attempts to solve this problem prior to the beginning of the present work. During the last year several additional articles have appeared and they will be briefly reviewed.

Of these recent articles the first that appeared was by von Tappeiner[7] who performed reimplantations and homotransplantations on dogs six and twelve weeks of age, using the distal half of the metatarsal. In his reimplantations he found that there was no disturbance in length growth even after six months, while in his homotransplantations he noticed a regular increasing shortening which was proportional to the length of time that had elapsed. He emphasized the importance of early function, and states that the younger the animal the less the amount of shortening. From his homotransplantations he concluded that for clinical applications the transplantations of the epiphysis is unsuccessful.

A short time later there appeared an extensive article by Obata[8] who performed on rabbits reimplantations, autotransplantations and homotransplantations of the entire metatarsophalangeal joint with either a part or an entire metatarsal and phalanx. In some experiments the transplants were made from the dead animal either with or without keeping for a time in salt solution. He also repeated the experiments of

5. Zoppi: Quoted by Rehn and Wakabajashi, Note 1.
6. Galcarzi: Quoted by Rehn and Wakabajashi, Note 1.
7. Von Tappeiner, Fr. H.: Studien zur Frage der Transplantations fähigkeit des Epiphysenknorpels und des Gelenkknorpels, Ztschr. f. d. ges. exper. Med., 1913, i, 491.
8. Obata, K.: Ueber Transplantation von Gelenken bei jungen Tieren, mit besonderer Berücksichtigung des Verhaltens des Intermediärknorpels, Beitr. z. Path. Anat. u. z. allg. Path., 1914, xlix, 1.

Digitized by Google

Rehn and Wakabajashi by transplanting the head of the radius from one animal to another. In his conclusions he stated that there was more or less shortening in all the cases, but that it was most marked in the homotransplantations. A bony union occurred in all the experiments except in homotransplantations, in which condition a pseudo-arthrosis resulted. In homotransplantations of the head of the radius he found only a slight degree of shortening. He does not agree with Rehn and Wakabajashi that this transplanted epiphysis functionated, but ascribes the evening up of growth to more extensive proliferation of the distal epiphysis. In the transplantations from the dead animal he noticed no evidence of growth and found with one exception that a pseudo-arthrosis occurred.

The next article that appeared was by Heller,[9] who carried out reimplantations of the distal epiphysis of the radius and ulna as well as homotransplantations between related and nonrelated rabbits. He also made a few reimplantations and autotransplantations in goats. He reported that the epiphysis did not keep up its normal length growth in any of the forty-five experiments in which the epiphyseal cartilage was transplanted in the form of half joints. The least amount of shortening took place in the reimplantations, while a greater degree occurred in homoplastic transplants, most marked in the nonrelated animals. In homoplastic transplantation he believed there was a complete cessation in function of the epiphysis, and he ascribed all growths to the nonoperated proximal epiphysis. From his experience with goats, because of the more marked degree of shortening, he concludes that the larger the transplant and the greater the size of the animal, the more marked will be the shortening. In concluding, he

9. Heller: Experimentelle Untersuchungen über die Transplantation des Intermediärknorpels in Form der halbseitigen Gelenktransplantation, Arch. f. klin. Chir., 1914, civ, 843.

Digitized by Google

said that in autotransplantations there was a lively regeneration of the epiphyseal cartilage from the perichondrium and that a not inconsiderable amount of bone apposition could be recognized, but nevertheless the bone growth remained checked and could not be utilized for practical purposes, especially so in cases of homotransplantations. He thinks that the most favorable conditions for the transplantation of the epiphyseal cartilage would be in the form of a thin sheet without adhering bone particles, so that it could come more directly in contact with the nourishing fluids of the body. In a postscript he added that in his more recent experiments on two months old animals, in which after autotransplantations of the epiphyseal cartilage in the form of very thin sheets, he found almost a normal growth. The exact details of these experiments are not given, so one cannot conjecture on the cause of the variations from his previous results.

The most recent article is by Minoura[10] on the transplantation of metatarsophalangeal joints of two months old rabbits into the soft tissues. Either the whole or half joint that was either intact or split longitudinally was transplanted into the back, subcutaneous tissue, liver, or abdominal cavity of the same or different animal. In some instances the joint was placed in a Ringer's solution before transplantation or was removed from a dead animal. He observed that the transplanted joints became encapsulated after one or two weeks. The healing always appeared the same whether it was in the abdominal cavity, subcutaneous tissue, liver, or the muscle. The longitudinally split half joints underwent quicker organization than the unsplit and resorption took place more rapidly when the parts were allowed to remain in Ringer's solution. He concluded that autotransplantation was

10. Minoura, M.: Studien über Gelenktransplantation (inkl. Intermediarknorpel) in Weichteile, Frankfurter Ztschr. f. Path., 8, 1914, xv, 397.

Digitized by Google

superior to homotransplantation and that the substitution processes were more active, quicker and intense, and that autoregeneration was more significant and continued for a longer period. Not much difference was noticed between transplants from the dead or from the living animal. In no case after transplantation, even in autotransplantation, was there any regular growth of the epiphyseal cartilage (only an irregular proliferation was found in the periphery) and in no case was there a lengthening of the transplanted joint. In comparing these experiments with those in which the transplantations were made into bone defects, it was noticed that the new formation was less evident, the degeneration appeared earlier in the new-formed tissue, and the resorption played a greater rôle, as in these cases the functional requirements of the respective tissue was lacking.

The prevailing opinions of these investigators indicate that the epiphyseal cartilage after transplantation loses more or less of its power to proliferate and thereby to increase the length of bone. In general they found considerable growth in reimplantations, less in autotransplantations, and practically none in homotransplantations. The greater the variations in the species the greater will be the growth disturbances. None of the authors agreed with Rehn and Wakabajashi in that there was no disturbance in growth after homotransplantation of the epiphysis.

All of the seventy-five experiments of this series were performed on dogs, the same animal often being used for two or more observations.

The majority of the animals were from one and a half to four months of age at the time of operation. In some animals the ages were not definitely known. They showed a definite growth after operation, but the metacarpals had not changed in length. This paradoxical condition can be explained by assuming that growth ceases in the metacarpals before it does in the longer bones.

Digitized by Google

The metacarpal and metatarsals were selected because they possessed but one epiphysis situated at the distal end of the bone and any growth which occurred could only be ascribed to proliferation at that particular epiphyseal cartilage. These bones were also easily measured at the time of operation and any change in length could readily be determined at the conclusion of the experiment. Another advantage in using these particular bones is that the adjoining bones serve as a natural splint.

METHOD OF OPERATION

All of the operations were performed under general ether anesthesia. The extremity was shaved and painted twice with tincture of iodin and the operation carried out with the usual aseptic technic.

The incision was made on the dorsal surface of the foot and special precautions were taken in order to preserve the normal vascular and nerve supply to that particular region.

In removing the segment to be transplanted special care was exercised so as not to injure the epiphyseal cartilage. In the very young animals a sharp knife was used, while in the older animals a small saw was necessary to sever the bony connections of the transplantation material.

The small transplants were anchored in place by means of an X-shaped silk suture, while the larger pieces were reinforced by an additional suture passed through the cortex of the diaphysis of each fragment. The total length of the operated and adjoining bones, also the removed and implanted segments were carefully measured. The wound was closed in layers and the foot encased in a plaster dressing, which was removed in from fourteen to twenty-one days. The animal was allowed its freedom from the start. Primary healing resulted in all but two cases.

Digitized by Google

At the conclusion of the experiment a roentgenogram was taken of the corresponding two feet. Then the foot was dissected and measurements made of all the metacarpals of both the operated and the normal foot. One half of a longitudinal section was preserved in Kaiserling's solution and the remaining part placed in Orth's fluid for further study.

It will be possible to give in this paper only the observations of the changes in growth following the various operative procedures.

In the interpretation of the results certain standards of comparison have been adopted in order to determine the various changes. The two inner metacarpals have been found from repeated observation on normal extremities to be of equal length or within 1 mm. of each other. It has also been noticed that the corresponding bones of each foot are practically of the same length. Thus there is a definite standard of comparison by means of which any change in growth may be calculated.

EXPERIMENTS

The following sets of Experiments Were Performed:

1. Reimplantation of an entire metacarpal or metatarsal: In these experiments the entire bone with its articular surfaces and periosteum intact, was raised from its position and immediately replaced. Table 1 shows the results.

Conclusion: After reimplantations of entire metacarpals or metatarsals, in growing animals, there is complete cessation of the growing function of the epiphysis.

2. Autotransplantation of an Entire Metacarpal or Metatarsal: An entire bone was transplanted from one foot to another foot of the same animal. Results are given in Table 2.

Digitized by Google

TABLE 1.—REIMPLANTATION OF AN ENTIRE METACARPAL OR METATARSAL

Number	Age Mos.	Duration of Experiment Days	Measurement at Operation Cm.	Measurement at Necropsy Cm.	Growth of Operated Bone Cm.	Growth of Normal Bone Cm.	Remarks
1. E2.....	5	52	3.05	3.15	0.1	0.7	
2. E2.....	5	52	3.15	3.3	0.15	0.7	
3. E3.....	5	208	6.3	3.2	—0.1	0.4	
4. E3.....	5	208	6.3	3.2	—0.1	0.4	
5. E4.....	3.5	113	3.65	3.6	—0.05	2.95	
6. E4.....	3.5	113	3.65 cut	3.7	0.05	2.75	Incised
7. E5.....	7	107	5.5	5.2	—0.3	0	
8. E6.....	4	298	5.6	4.9	—0.6	0	
9. E6.....	4	298	5.6 cut	4.9	—0.7	0	Incised
10. E13-R.....	Old	115	Not taken. Growth ceased	Not taken	0	0	Incision; shows degen.
11. E13-L.....	Old	115	Not taken. Growth ceased; cut	Not taken	0	0	

TABLE 2.—AUTOTRANSPLANTATION OF AN ENTIRE METACARPAL OR METATARSAL

Number	Age Mos.	Duration of Experiment Days	Measurement at Operation Cm.	Measurement at Necropsy Cm.	Growth of Operated Bone Cm.	Growth of Normal Bone Cm.	Remarks
1. E1.....	5	109	6.9 cut	1.5	—5.4	0	Cut off end
2. E1.....	5	109	6.9	6.6	—0.3	0	
3. E17.....	9	36	6.7 cut	6.1	—0.5	0.3	Long incis. at both ends
4. E8.....	6	91	6.7 right	6.8	0.1	0	
5. E8.....	6	91	6.7 left	6.4	—0.3	0.2	
6. E10-R.....	3.5	89	4.8 cut	4.3	—0.5	0	Incision; showed evidence of degeneration
7. E10.....	3.5	89	4.8	4.3	—0.5	0	

Digitized by Google

Conclusion: The transplanted bones not only failed to grow, but showed definite evidence of degeneration and decrease in length.

3. Reimplantation of Split Metacarpal: The reimplanted bone was divided longitudinally and reinserted. Results are given in Table 3.

Conclusion: As these animals had reached the end of their growing period no observations can be made on the disturbances in length grows. Some of the bones showed definite evidence of absorption and decrease in length.

4. Autotransplantation of Split Metacarpal or Metatarsal: Before transplanting to another foot the bone was split longitudinally. Results are given in Table 4.

Conclusion: In the single observation in this group in which the animal showed evidence of growth in the normal bones there was a definite decrease in size of the transplant, showing that the splitting of the bone had no favoring influence on the viability of the epiphysis.

5. Reimplantation of the Epiphyseal Cartilage: In this series of experiments the epiphyseal cartilage, including a piece of adjoining epiphysis and diaphysis, was excised and immediately reimplanted. Table 5 gives the results.

Conclusion: In none of these experiments was there an increase of more than 2 mm. in length since the operation, while the normal bones showed as much as 7 mm. of growth. A difference of 2 mm. in length is within the limits of error in measurement or lengthening due to failure of close approximation. After reimplantation of the epiphyseal cartilage there is at first a slight increase in length while at a later period there is a decrease in length.

6. Autotransplantation of the Epiphyseal Cartilage: In these experiments the resected epiphyseal cartilage was interchanged with a corresponding piece from a bone of the other foot. Results are noted in Table 6.

Digitized by Google

TABLE 3.—REIMPLANTATION OF SPLIT METACARPAL OR METATARSAL

Number	Age Mos.	Duration of Experiment Days	Measurement at Operation Cm.	Measurement at Necropsy Cm.	Growth of Operated Bone Cm.	Growth of Operated Bone Cm.	Remarks
1. E9.....	?	31	5.7	5.6	—0.1	0	
2. E14-6.....	4.5	237	5.9	5.8	—0.1	0	Consid. change in marrow
3. E15.....	6	38	5.8	5.8	0	0	
4. E18-2.....	6	223	6.05	3.3	—2.8	0	

TABLE 4.—AUTOTRANSPLANTATION OF SPLIT METACARPAL OR METATARSAL

Number	Age Mos.	Duration of Experiment Days	Measurement at Operation Cm.	Measurement at Necropsy Cm.	Growth of Operated Bone Cm.	Growth of Normal Bone Cm.	Remarks
1. E12.....	Very old	235	?	6.1	—0.2	0	Incised degen.
2. E17-R.....	6	36	6.7	6.1	—0.6	0.4	Incised end necrotic

TABLE 5.—REIMPLANTATION OF THE EPIPHYSEAL CARTILAGE

Number	Age Mos.	Duration of Experiment Days	Measurement at Operation Cm.	Measurement at Necropsy Cm.	Growth of Operated Bone Cm.	Growth of Normal Bone Cm.
1. E14-6.....	4.5	37	5.9	5.7	—0.2	0
2. E23-13.....	1.5	23	3.9	4.1	0.2	0.4
3. E24-14.....	?	4	3.6	3.8	0.2	0
4. E33-44.....	1.5	43	2.7	2.8	0.1	0.7
5. E38-26.....	4.0	55	4.4	4.2	—0.2	0.1
6. E41-39.....	5.0	43	4.55	4.5	—0.05	0.5

Digitized by Google

Conclusion: With the exception of two experiments there was no definite evidence of increase in size after autotransplantation of the epiphyseal cartilage. In these two positive results the increase in size was very limited being only 0.35 cm. as compared with 1.4 cm. of normal growth. On section of the bones the epiphysis of the operated bones showed definite signs of degeneration, while the epiphysis of the nonoperated bones presented a normal appearance. After autotransplantation of the epiphyseal cartilage its function to increase in a linear direction is entirely lost or only persists in a very limited degree.

7. Reimplantation of Varying Lengths of the Epiphyseal End of the Metacarpal and Metatarsal Bones: In this series of experiments one-third, one-half and two-thirds of the epiphyseal end of the metacarpal was removed entirely from its normal bed and reinserted immediately in the same position. Results are noted in Table 7.

Conclusion: In none of these cases with the one exception of Experiment 8 E 34-43 L, was there any evidence of increase in length growth. The exact reason for the increase in this experiment cannot be definitely determined. It is possible that for some special reason this particular epiphysis proliferated for a short time. In the gross specimen there is no evidence of epiphyseal cartilage, so what growth occurred took place early and only for a limited time. In view of the large number of negative results this experiment cannot be definitely considered as indicating an active functioning of the transplanted epiphysis. Whether a long or short piece of bone was transplanted with the epiphysis was of no consequence as there was practically complete failure of the growth in every case. Incisions or boring of holes into the bone seem to hasten the degenerative processes.

8. Autotransplantation of Varying Lengths of the Epiphyseal End of the Metacarpal or Metatarsal:

Digitized by Google

TABLE 6.—AUTOTRANSPLANTATION OF THE EPIPHYSEAL CARTILAGE

Number	Age Mos.	Duration of Experiment Days	Measurement at Operation Cm.	Measurement at Necropsy Cm.	Growth of Operated Bone Cm.	Growth of Normal Bone Cm.	Remarks
1. E9-4	?	86	5.1	5.0	0	0	
2. E10-5	3.5	89	4.8	4.5	—0.3	0.1	
3. E15-7	6.0	38	5.8	5.9	0	0	Piece inserted was 0.75 mm. wider than that removed
4. E23-13-R	1.75	23	4.0	4.2	0.2	0.6	
5. E23-13-L	1.75	23	3.6	3.8	0.2	0.4	
6. E32-39-R	1.75	136	2.5	2.85	0.35	1.4	
7. E32-39-L	1.75	136	2.55	2.9	0.35	1.4	

TABLE 7.—REIMPLANTATION OF VARYING LENGTHS OF THE EPIPHYSEAL END OF THE METACARPAL AND THE METATARSAL BONES

Number	Age Mos.	Duration of Experiment Days	Measurement at Operation Cm.	Measurement at Necropsy Cm.	Growth of Operated Bone Cm.	Growth of Normal Bone Cm.
1. E5-1	5	107	Total 5.4; resected ½ piece 2.7	5.2	—0.2	0
2. E7	7	155	Total 7.4; resected ⅔ piece 4.4	3.7*	—3.7	0.3
3. E22-12	1.5	22	Total 4; resected ⅔ piece 2.55	3.9	—0.1	0.5
4. E30-38-R	?	13	Total 2.4; resected ⅓ piece 0.7	2.3	—0.1	0
5. E30-38-L	?	13	Total 2.4; resected ⅔ piece 1.8	2.5	0.1	0
6. E31-36	1.75	17	Total 2.5; resected ½ piece 1.25	2.5	0	0.1
7. E33-44	1.5	44	Total 2.7; resected ½ piece 1.5	2.7	0	0.7
8. E34-43-L	1.5	115	Total 2.8; resected ⅓ piece 1.1	3.25	0.45	1.20
9. E34-43-R	1.5	115	Total 2.8; resected ⅔ piece 2.0	2.95	0.15	1.45
10. E37-40	2	38	Total 3.05; resected ⅔ piece 2.3	3.0	0	0.3
11. E38-26	4	85	Total 4.5; resected ½ piece 2.25	4.2†	—0.3	0
12. E41-39	4.75	44	Total 4.4; resected ⅓ piece 1.8	4.3‡	—0.1	0.5

* Infection. † Bored holes—nonunion at operation. ‡ Nonunion.

Digitized by Google

These experiments differ from those of the previous group (7) in that the segment of bone was interchanged with a corresponding segment from the opposite foot. Results are noted in Table 8.

Conclusion: There is a uniform failure of growth after autotransplantation of varying lengths of the epiphyseal end of the bones. The normal bones show a marked increase in length. Boring holes into transplants increases the degenerative processes.

9. Two Stage Autotransplantation of Different Lengths of the Epiphyseal End of the Metacarpal or Metatarsal: In this set of experiments the distal one-third, one-half or two-thirds was united to the proximal two-thirds, one-half or one-third respectively of the adjoining metacarpal or metatarsal. After a sufficient length of time for union had elapsed a second operation was performed in which the distal segment was entirely separated from its surrounding tissues thereby completing the autotransplantation. Results are shown in Table 9.

Conclusion: In this set of experiments there was evidence of almost normal growth up to the time of the second operation, but after severing the epiphyseal end from its surrounding tissue there was a marked diminution in growth. This shortening took place even when there was firm union with the normal proximal segment. It was noticed that in cases where nonunion occurred that there was more marked disturbances in growth — even in the first part of the experiment. Under these very favorable conditions for transplantation there was considerable diminution of the function of the epiphysis after transplantation.

GENERAL CONCLUSIONS

1. From the practically uniform failure of increase in length of the bones after transplantation of the epiphyseal cartilage, either alone or with an accompanying piece of the epiphysis and diaphysis, both in

Digitized by Google

TABLE 8.—AUTOTRANSPLANTATION OF VARYING LENGTHS OF EPIPHYSEAL END OF METACARPAL AND METATARSAL BONES

Number	Age Mos.	Duration of Experiment Days	Measurement at Operation Cm.	Measurement at Necropsy Cm.	Growth of Operated Bone Cm.	Growth of Normal Bone Cm.
1. E19-5	5.0	34	Total 5.6; resected ½ piece 2.5	5.65	0.05	0.6
2. E19-5-R.	5.0	34	Total 5.6; resected ½ piece 2.6	5.6	0	0.6
3. E20-10-L.	1.5	25	Total 3.6; resected ½ piece 1.8	3.6	0	0.5
4. E21-11	1.5	42	Total 3.8; resected ½ piece 1.9	3.7	0	0.6
5. E29-37-R.	2	143	Total 2.6; resected ⅓ piece 0.7	2.75	0.15	1.15
6. E29-37-L.	2	143	Total 2.5; resected ⅓ piece 0.7	2.6	0.1	1.3
7. E35-41-R.	1.75	111	Total 3.0; resected ½ piece 1.55	3.0	0	1.6
8. E35-41-L.	1.75	111	Total 2.95; resected ½ piece 1.5	3.0	0	1.4
9. E36-42-R.	1.75	43	Total 2.8; resected ⅔ piece 2.1	2.9	0.1	0.55
10. E36-42-L.	1.75	43	Total 2.9; resected ⅔ piece 2.1	2.95	0.05	0.6
11. E40-37-L.	5.5	43	Total 4.3; resected ⅓ piece 1.8	4.2	0	0
12. E40-37-R. Homo.	5.5	43	Total 4.1; resected ⅓ piece 1.6	3.9	0	0.15

TABLE 9.—TWO STAGE AUTOTRANSPLANTATION OF DIFFERENT LENGTHS OF THE EPIPHYSEAL END OF THE METACARPAL AND THE METATARSAL BONES

Number	Age Mos.	Duration of Experiment Days	Measurement at First Operation Cm.	Measurement at Second Operation Cm.	Measurement at Necropsy Cm.	Growth of Operated Bone Cm.	Growth of Normal Bone Cm.
1. E16	9.0	89	Total 6.9; resected ½ piece 3.2	No second operation	6.9	0	0.
2. E20-10	1.5	25	Total 3.5; resected ½ piece 1.9	Not taken; union at first	4.0*	0.5	0.5
3. E21-11	1.5	42	Total 3.7; resected ½ piece 1.9	No second operation	4.3	0.6	0.6
4. E22-12	1.5	22	Total 3.9; resected ⅔ piece 2.85	No second operation	4.0†	0.1	0.4
5. E25-26	2.0	155	Total 4; resected ½ piece 1.9	Total? Resected piece 2	3.6†	—0.4	0.15
6. E26-27	1.5	64	Total 3.1; resected ½ piece 1.5	Total 3.7. Resected piece ?	3.85	0.75	1.6
7. E27-28	1.5	80	Total 2.9; resected ⅓ piece 1	Not taken	3.3‡	0.4	1.6
8. E28-29	1.5	67	Total 3; resected ⅔ piece 2.3	Total 3.7. Resected piece 3.	3.9	0.9	1.5
9. E37-40	2.0	38	Total 3; resected ⅓ piece 1	Total 3.25. Resected piece 1.2	3.3	0.3	0.3
10. E39-41	1.75	46	Total 4.4; resected ⅓ piece 1.6	Total 4.4. Resected piece ?	4.25‡	—0.15	1.1

* Died two days after second operation. Nonunion at second operation. † Nonunion. ‡ Nonunion first.

Digitized by Google

reimplantation and autotransplantation, it must be concluded, that epiphyseal cartilage loses its power to functionate after such transplantations.

2. As the degenerative processes were more advanced in autotransplantation than in reimplantation, it can be almost certainly predicted that there would be a more marked degeneration in homotransplantation.

3. Whether a small or large sized transplant was taken was of no consequence, as there was the same failure of growth in every instance. Incisions into the periosteum or boring holes into the cortex hastened the degenerative processes.

4. There was marked disturbance of growth following the two-stage autotransplantation, in spite of the fact that osseous union was secured before severing the epiphyseal transplant from its surrounding and nourishing tissues.

5. The epiphyseal cartilage must be considered as a very vulnerable tissue, its viability being directly dependent upon its blood supply.

Shreve Building.

I wish to express my indebtedness to Professor Blaisdell of the Surgical Laboratory, who assisted in the operative work, and to Professor Ophuls of the Pathological Laboratory, under whose direction the above work was performed.

ABSTRACT OF DISCUSSION

Dr. D. B. Phemister, Chicago: The finding of Dr. Haas that there is apparently no longitudinal growth through the epiphyseal cartilage after transplantation is very interesting. One would expect cartilage to live if any tissue lives when transplanted, because it is nourished by a lymphatic instead of a blood vascular circulation. Hyaline articular cartilage covering the ends of bones is frequently detached with or without a portion of underlying bone and becomes a loose body in the joint. The bone cells, if any are present, always die and are absorbed, but the cartilage, receiving sufficient nutrition from the synovial fluid, remains alive indefinitely. The deeper cells which have a columnar arrangement, slowly undergo necrosis. I have studied histologically ten or twelve such specimens of the various ages and have noted trans-

Digitized by Google

formation of the superficial cartilage into fibrinous connective tissue in the older specimens. In one specimen that had been free in the joint for ten years there was proliferation of the cartilage and a connective tissue capsule had formed. The injury of the transplant resulting in disturbance of longitudinal growth might be either to the epiphyseal line or to the juxta-epiphyseal bone. The small amount of longitudinal growth occurring in some of his experiments might possibly be accounted for by longitudinal growth in the shaft itself. We see the shaft of a bone increase one-half an inch or more in length as a result of an inflammatory process, as syphilis or in osteitis deformans, where the epiphyseal lines are closed. Consequently, there is no reason why in the absence of the normal process of longitudinal growth, and where there is a great demand for it, the cells of the shaft should not proliferate and increase the length of the bone.

Dr. J. T. Rugh, Philadelphia: I think the important lesson for us as practical orthopedic surgeons is the postponement of our operative work in this type of cases until adult life or until the expectation of any natural increase in growth is past. I know in my own experience I have been sorely tempted at times to replace a very imperfect hip joint, in the case of congenital dislocation, or similar condition with the head of the fibula, but have thus far refrained, and I shall continue to do so in the future. The lesson I have learned from this experimental work of Dr. Haas has been of enormous importance.

Dr. Roland Meisenbach, Buffalo: The work of Dr. Haas, in my opinion, is of great value. Although he has gotten some negative results, I think it touches on many things of value which will in the future give us a better understanding of one of the most important parts of the long bone; namely, the epiphysis. It may also assist in giving us a better understanding of the function of the epiphysis. I am particularly interested in this work because several years ago I did some research work on the chemical and mechanical stimulation of the epiphysis. In this work, I had occasion to observe the epiphysis both microscopically and macroscopically in about two hundred rabbits. In studying the epiphyseal and diaphyseal lines, it was interesting to see from the experimental work the close relation to the practical work; that is, the cases which we see daily that have interference of growth or which have stimulation of growth of the epiphysis. This work is really the fundamental source of all fracture and bone-graft work. I would like to ask Dr. Haas whether the transplant is divided from above or below the diaphyseal line. This will, I believe, change the results of the experiments materially. In my experiments I was able to stimulate and retard bone

Digitized by Google

growth, depending on which part of the epiphyseal cartilage was attacked in the experiment. I have a few lantern slides which I prepared for the Pan-American Congress which show sections of the epiphysis and epiphyseal line in different stages of stimulation. That is, that by either toxic or mechanical means it is possible to cause more bone to form in the region of the epiphyseal end of long bones, as in my experiments with tibiae, or to almost cause an arrest of growth. One slide shows that by means of toxic agents it has been possible to cause the entire epiphyseal line to close at a much earlier period by months than normally. This explains, I believe, many of the cases which have focal infection at some part of the body that later on developed joint lesions, and in which the joints became deformed; also it explains the arrest of growth following fractures, and therefore I think that an attempt to transplant the epiphysis depends largely on the point from which we take the transplant and the technic employed.

Dr. S. L. Haas, San Francisco: As Dr. Phemister has mentioned, cartilage is a very resistant tissue. It is able to withstand a considerable amount of injury and is dependent on the surrounding tissues and fluids for its nourishment. I have only studied a few microscopic preparations from these experiments and have found that the cartilage near the perichondrium remained alive. It is possible that some of this cartilage may continue to proliferate, but I doubt if it would cause any decided increase in the length of the bone. There is a distinction between growth in length and increase in size. It was noticed in some of these experiments that there was a marked swelling about the epiphyseal cartilage without any increase in length, showing that although there was cell growth there was no purposeful longitudinal increase like the normal epiphyseal cartilage. It was merely the regular cell division and multiplication which manifested itself by spreading in the line of least resistance. It was shown in the old experiments of Hunter and Duhamel that the longitudinal growth of bone takes place only at the epiphyseal ends. In these experiments two pegs were driven into the diaphysis and in spite of an increase in length of the bone there was no change in the distance between the two pegs. As to the increase in length following destructive osteomyelitis, it might be due to the general wild multiplication during the processes of regeneration, which, being unrestricted, spreads in all directions.

In regard to Dr. Meisenbach's question as to whether the transplantation was made above or below the epiphyseal line, I presume he wishes to ascertain the relation of the incisions to the metaphysis, which is the most actively growing part of the bone. In all the excisions of the epiphyseal

Digitized by Google

cartilage a piece of adjoining epiphyseal and diaphyseal bone was removed so as not to injure that particular region. Heller, in a postscript to his article, stated that he had succeeded in transplanting the epiphyseal cartilage in the form of very thin sheets of cartilage and that there resulted almost a normal growth. He does not give the exact details of his experiments, but from the results of my experiments I am forced to entertain some doubt as to the correctness of his conclusions. It is possible that by some special method he is able to get these good results.

Digitized by Google

THE ROLE OF THE NOSE, THROAT AND ACCESSORY SINUSES IN THE ETIOLOGY OF CHRONIC INFECTIOUS ARTHRITIS

ROLAND HAMMOND, M.D.
PROVIDENCE, R. I.

For many years it has been recognized that perhaps the chief problem to be considered in chronic infectious arthritis is the determination of the etiologic factor within the body. It is reasonable to suppose that if the arthritis be due to some suppurative process, the joint condition *should* be relieved provided the etiologic factor can be found and removed. In the presence of more than one source of infection, it may require clear judgment and careful analysis of the history and physical findings, in order to determine which factor is responsible for the arthritis in a particular case.

Every organ, every secretion, and nearly every inch of the body has been carefully scrutinized in an attempt to determine the cause of the disease in numerous cases of chronic infectious arthritis. One of the regions of the body which has seemed to offer a fruitful field for such investigation is the domain of the "nose and throat man"—the ears, nose, throat and accessory sinuses.

Many articles have been written of late years, placing emphasis on the importance of these organs in their relation to arthritis. Some of the recent writers have attributed so much importance to this region, as the site of infection in a large number of cases of arthritis, that I was led to undertake the investigation on which this paper is based.

Digitized by Google

The experience of many workers in this field seems to show an undoubted connection between tonsillitis and arthritis in many cases, especially those acute in onset and character. This study was undertaken to determine, if possible, what percentage of cases of chronic infectious arthritis were found to have coexisting disease of the tonsils, and of the ears, nose and accessory sinuses as well. As would naturally be expected, such examinations would lead to the discovery of disease in the teeth and gums. Whenever possible the dental conditions were studied, their possible relationship to the arthritis analyzed, and proper treatment instituted if found necessary. We also wished to determine the efficacy of treatment by the nose and throat surgeons in these cases, and have endeavored to trace every patient operated on by them, and to ascertain the effect of this treatment on the arthritis.

I wish to state at the outset that I did not share the opinion of those workers in this field who believe that a recognizable focal infection is present in nearly all cases of chronic infectious arthritis. Nor could I be convinced, from my experience in these cases, that the removal of a focal infection would necessarily cure an arthritis of some months' duration. It is a matter of common experience with those who see a large number of these cases, that a brilliant result is occasionally obtained by the removal of tonsils containing pus pockets, or by the drainage of a suppurating sinus. Similar results are obtained when a focus of infection anywhere in the body is removed. In my experience such a happy outcome in the case of chronic infectious arthritis is the exception rather than the rule.

Most of the cases of chronic infectious arthritis which have come to the orthopedic clinics of the Rhode Island Hospital and St. Joseph's Hospital during the past two years, in which the etiology was not readily determined, have been referred to the ear,

Digitized by Google

nose and throat departments of these hospitals for examination. This included a majority of the cases of infectious arthritis. Cases in which a gonorrheal infection had immediately preceded the onset of the joint condition were not referred for examination, since the disease was usually limited to one joint, and the connection between the gonorrhea and the arthritis seemed fairly well established.

The cases were not selected in any way, but, as they appeared, were referred for examination and treatment by the nose and throat surgeons when deemed necessary by them. The cases were nearly all polyarticular in distribution, and were the bulk of that interesting and often puzzling group of joint cases, encountered in the daily routine of any adult orthopedic clinic. Cases were referred for examination, even in the absence of any symptoms pointing to disease of the ear, nose, throat or sinuses.

Otherwise these cases were all treated in the routine manner. They were referred to other departments of the hospitals, when necessary, for consultation and treatment, and laboratory and Roentgen investigations were made in nearly every case. In classifying these cases as positive or negative, according as they showed disease of the nose, throat or sinuses, or did not, the opinion of the nose and throat surgeon has been taken as the sole criterion, even in cases in which it seemed to the orthopedic surgeons that some other etiology was probable.

The result of this investigation is shown in Table 1:

TABLE 1.—PREPONDERANCE OF TONSILLAR INFECTION

Total number of cases studied	61
Cases with doubtful nose and throat evidence	3
Cases with negative nose and throat evidence	28
Cases with positive nose and throat evidence	30
Cases with positive nose and throat evidence in which nose or throat operation was performed	12
Cases with positive nose and throat evidence in which such operation was not performed	18

In Table 1 the large proportion of cases showing tonsillar infection is noteworthy.

Digitized by Google

Of the 12 patients operated on, the tonsils were removed in 9, pockets in the tonsils were opened in 1, the frontal sinus was drained in 1, and a deviated septum corrected in 1. In two of the cases of tonsillectomy the adenoids were also removed, and in another case the midturbinate was removed to drain the ethmoid cells.

Of the 18 patients not operated on, the tonsils were infected in 12, there was sinusitis in 3, otitis media in 1, necrosed teeth in 1, and Riggs' disease in 1.

The condition of the arthritis following operation for disease in the nose or throat in 12 cases is shown in Table 2:

TABLE 2.—CASES SHOWING POSITIVE NOSE OR THROAT DISEASE AFTER OPERATION

Marked improvement	2
Slow but gradual improvement	3
No improvement (one with ankylosis)	2
Better in one joint, worse in two others	1
Worse in joints after operation	1
Not found	3
	12

The advice given in 18 cases with positive nose and throat evidence in which operation was not performed is shown in Table 3:

TABLE 3.—CASES SHOWING POSITIVE NOSE AND THROAT AFFECTIONS NOT OPERATED ON

Operation advised but either refused or not yet performed (4 improved without operation)	10
Operation not advised (2 improved without treatment)	4
Operation not advised but treatment advised (1 improved without treatment)	2
Referred to dentist	2
	18

Of the 28 patients with negative nose and throat evidence, 5 had necrotic teeth, 3 had Riggs' disease, and 2 had had arthritis following removal of adenoids and tonsils, in one case six weeks, in the other nine months, after the operation. In the last two cases no connection between the operation and the arthritis is presupposed. In making this report we feel that care should be taken in drawing conclusions from a

Digitized by Google

TABLE 4.—POSITIVE NOSE AND THROAT EVIDENCE IN CASES WITH OPERATION

Name	Age	Joints	Duration	Nose or Throat Condition	Operation	Results
E.	9	L. knee	2 weeks	Tonsils infected, adenoids present	Tonsillectomy	Improved
L.	23	L. elbow, r. knee, r. wrist, l. ankle	5 months	Acute tonsillitis	Tonsillectomy	Slight gradual improvement
E.	26	Elbows, wrists, hands, r. knee	7-8 years	Tonsils infected, adenoids present	Tonsillectomy, adenectomy	No improvement (ankylosis)
K.	27	Hands, wrists, r. knee, r. elbow	1¼ years	Tonsils infected	Tonsillectomy	R. wrist better; l. wrist and l. elbow worse
E.	28	Shoulder, knees, wrists, ankles	6 months	Tonsils infected	Tonsillectomy	Throat better, joints worse
C.	24	Shoulders, knees, feet	6 months	Deviated septum	Septum corrected	Not found
M.	48	L. knee, l. elbow, r. wrist	5 years	Tonsils infected, teeth necrosed	Tonsillectomy (arthrotomy)	Improved, both throat and joints
D.	12	L. hip, hands, r. knee	3 months	Tonsils infected	Tonsillectomy	Very slight, gradual improvement
C.	21	Knees, ankles, wrists	2 months	Frontal sinusitis	Sinus drained	Not found
D.	14	L. ankle, knees, hips...	7 years	Tonsils infected	Tonsillectomy	Joint condition no better, but less pain
W.	44	Shoulders, knees, spine	4 months	Tonsils infected	Tonsillectomy, adenectomy	Slow, gradual improvement
G.	42	Wrists, hips, ankles....	11 years	Pus on midturbinate....	Turbinate removed, pockets in tonsils opened	Not found

Digitized by Google

small number of cases. The difficulties in the way of proper deductions are many. It is a well known fact that deep in its crypts the most innocent appearing tonsil may harbor micro-organisms of a harmful nature. The *Streptococcus hemolyticus,* which is the special agent found in associated joint lesions, lies in deep chronic abscesses and sealed crypts. Consequently it is very difficult in a doubtful case to determine whether operation should be urged or decried. In the case of an infected sinus, the difficulty of proving its relationship to an existing arthritis is even greater.

It would have been profitable to have investigated other focal sources of infection in these joint cases, such as necrotic teeth, Riggs' disease, lesions of the genito-urinary and gastro-intestinal tracts, gallbladder and other infections. Since the study was limited to the nose, throat and accessory sinuses, however, the conclusions must be based on a study of diseases of those organs.

The results of operative treatment in these cases were, on the whole, not encouraging. The removal of tonsils or the draining of a suppurating sinus have produced marked improvement in the joint conditions in these cases in only a few instances. Often there has been slow, gradual improvement as is seen under routine orthopedic treatment. The general condition of the patient has improved after the nose and throat operation in nearly every case. It seemed as if a load had been removed and the general health was much better.

It is to be remembered that the majority of these cases are chronic in nature, and marked improvement is not reasonably to be expected except with the lapse of considerable time. This is even more true when ankylosis is present.

In most of these cases the damage seems to occur early in the course of the disease. The time for

Digitized by Google

TABLE 5.—POSITIVE NOSE AND THROAT EVIDENCE IN CASES WITHOUT OPERATION

Name	Age	Joints	Duration	Nose or Throat Condition	Operation Advised	Results
G.	35	Knees, ankles	3 weeks	Frontal sinusitis	None	Not found
F.	48	Shoulders, knees, hips, wrists	5 months	Left otitis media.....	None	Improved
D.	12	Knees, r. ankle	6 months	R. tonsil infected.....	Tonsillectomy	Improved
D.	8	Knees, feet	4 months	Tonsils infected, adenoids present	Tonsillectomy, adenectomy	Improved
D.	54	R. wrist, r. elbow, r. knee	3 months	Tonsils infected	Tonsillectomy	Not found
B.	34	Feet, l. knee.....	2 months	Tonsils infected	Tonsillectomy	Not found
V.	21	Knees, hip, ankle, hand, spine	3 weeks	Tonsils infected	Tonsillectomy	Not found
S.	42	Wrist, knee, shoulder, ankle	3 months	Mucopus in epipharynx Riggs' disease	Teeth extracted	No improvement (ankylosis)
B.	45	Hands, feet, shoulder, knees	11 years	Suppurative ethmoiditis and polypi	Turbinectomy	Slight, gradual improvement
W. B.	26	R. ankle, r. knee.....	1½ years	Necrosed teeth	Referred to dentist.....	Not found
E.	18	Feet, hands	5 months	Tonsillitis, ethmoiditis?	None	Not found
M.	48	Feet, r. thumb, r, knee	4 months	Pockets in tonsils, sinusitis, Riggs' disease	None	Improved
S.	56	Wrists, ankles, knees...	2 years	Tonsils infected	Tonsillectomy	Not found
K.	38	Shoulders, knees, hands, spine, feet	3 months	Tonsils infected	Tonsillectomy	Not found
B. B.	15	Knees, feet, wrists, elbows, shoulders	4 weeks	Tonsils infected, adenoids present	Tonsillectomy, adenectomy	Much improved
L.	39	Hands, r. hip, r. ankle	2½ years	Otitis media, sinusitis.	None	Died of periostitis femur
C.	24	Knees, shoulders	1½ years	Tonsils infected	Tonsillectomy	Not found
W.	32	Knees, feet, shoulders, ankles	6 months	Tonsils infected, Riggs' disease	None	Slight, gradual improvement

Digitized by Google

investigation and treatment of a focus is in the early stages or even before the onset of the arthritis. Patients who have had previous attacks and have recovered without permanent damage to the joints should have the focus removed, if it can be discovered, to prevent the recurrence of other attacks. This is especially true in the numerous cases in which attacks of tonsillitis have been followed by arthritis. When permanent damage to the joint structures has occurred, but little improvement may be expected from removal of any focus of infection, beyond the improvement in the general health.

The difficulty lies in determining with certainty that the focus which has been discovered is really the cause of the arthritis. Many cases show diseased tonsils or a suppurating sinus coexistent with carious teeth or Riggs' disease. Which factor in such a case shall be considered the responsible cause? The removal of one or all of these foci may have no beneficial effect on the arthritis, and we may find that absorption from the gastro-intestinal tract, or some other source, is the real cause.

Our experience has shown that the greatest benefit in these cases is to be expected from stimulating measures tending to build up the general health of the patient, trusting to later improvement in the local joint conditions as the patient responded to treatment.

I am indebted to the surgeons of the ear, nose and throat departments of the Rhode Island Hospital and St. Joseph's Hospital for their cooperation and interest in the work. To Dr. Harlan P. Abbott, surgeon to the ear, nose and throat department of the Rhode Island Hospital, I wish to express my deep gratitude for the painstaking examinations he has made. and his zeal in following up the cases. With a few exceptions, all these cases have been examined by Dr. Abbott personally. This adds to the value of the examination, and I trust also to the value of any deductions which may be made. I wish also to thank my colleagues for kindly allowing use of material on their services.

266 Benefit Street.

Digitized by Google

THE CLINICAL TYPE OF ARTHRITIS ORIGINATING ABOUT THE TEETH

THOMAS B. HARTZELL, M.D., D.M.D.
Research Professor of Mouth Infections, University of Minnesota Medical School
MINNEAPOLIS

The etiology of rheumatism has attained a new position in the last few years, and to Alfred Mantle, consulting physician to the Royal Halifax Infirmary, Harrogate, England, should be credited the first work leading to change of position concerning the etiology of this disease. When he commenced his work, bacteriology was in its infancy. At a meeting of the British Medical Association which was held at Brighton, he read a paper in the section of medicine, presided over by the late Sir William Broadbent, the title being, "The Etiology of Rheumatism Considered from a Bacteriological Point of View,"[1] at which time he demonstrated the organisms he had found both macroscopically in culture and microscopically.

Even prior to that time, Mantle had discussed the frequency of rheumatic symptoms in scarlatina.[2] His observations in this paper suggested that the throat, joints, and serous membranes become infected during bacterial invasion, and he suggested the possibility of acute rheumatism itself having a like origin. He also witnessed the two epidemics of rheumatic fever which pointed strongly to infection. He embodied his clinical observations in a thesis which he

1. Mantle, Alfred: The Etiology of Rheumatism Considered from a Bacterial Point of View, Brit. Med. Jour., 1877, i.
2. Mantle: Quart. Med. Jour., quoted by Mantet, Practitioner, London, January, 1912.

Digitized by Google

sent up for the Doctorate of Medicine and naively remarks that these views did not gain acceptance by the examiners, one of them being the late Dr. W. Miller Ord. Though this dampened his enthusiasm, his thesis was accepted. The material on which he based his later paper, published in 1877, was founded on a study of a typical case of acute rheumatism from which he obtained under antiseptic precautions, by means of a sterilized hypodermic syringe, a dram of serum withdrawn from the knee-joint. This he placed in sterilized gelatinized meat infusion, which was placed in an incubator. These plantings produced copious bacterial growth. From six other cases, over a period of several months, he obtained serum from effused joints with like results. Following this he made blood cultures in sixteen cases, taking every precaution to prevent contamination from without, and he tells us in most of these cultures, bacteria were found. Subsequent to this, he was permitted, by the Home Office, two experiments which were conducted in the Durham College of Medicine, in which he injected two monkeys with his cultures. These experiments failed to produce the disease in the monkeys, however, and for the time being, his research was set aside.

The next work of importance in England in this line was published by Poynton and Paine in 1900, though between 1877 and 1900 considerable research in this field was done on the continent. Guttman in 1877, Birch-Hirschfeld, Bouchard and Charin, Triboulet, Sahli and Sacaze "found organisms in acute rheumatism." "In 1891 Achalme first found his bacillus. In 1894 several observers in Germany, Italy and France, described organisms occurring in joint fluids and blood of patients suffering from acute and 'chronic' rheumatism." In 1895 Newsholm demonstrated that the disease might be epidemic and in the same year Leyden isolated a delicate diplococcus. Mantle tells us Achalme's results seemed nearest his

Digitized by Google

own. In 1900 Poynton and Paine[3] published a letter in the *Lancet,* in which they fully acknowledged Dr. Mantle's priority in this field, though their work was undertaken and accomplished without knowledge of Doctor Mantle's work until after their attention was called to it by the editor of the *Lancet.* Beatson and Ainley Walker in 1903[4] confirmed the results published by Poynton and Paine and others isolating a diplococcus in fifteen cases, and Beattie in 1904,[5] produced a combination of lesions similar to those of rheumatic fever in man.

That much wonderful work has been done in later years confirming this earlier work and largely adding to what we have already gained is known to all. It would be valuable did time permit to refer to the bibliography of this subject in detail. I cannot in passing neglect, however, to especially speak of the work of Rosenow[6] on "The Etiology of Arthritis Deformans," and many other articles from this same author; "Experimental Myocarditis," by Leila Jackson,[7] and the work of Klotz,[8] from the pathologic laboratories of the University of Pittsburgh.

That inflammation of the joints can be caused by many organisms which gain access to the para-articular tissues is probably true. We are all acquainted with the classic effects of the gonococcus when distributed in these tissues. John B. Murphy, in a paper read before the Hennepin County Medical Association, cited from his practice a case of joint infection in which the colon bacillus was isolated. The relationship of the *Streptococcus viridans* to chronic joint infection has been firmly fixed by Rosenow and other observers, but so far as I know, little has been done to establish

3. Poynton and Paine: Lancet, London, 1900, xi, 1306.
4. Beatson, R. M., and Walker, E. W. A.: Brit. Med. Jour., 1903, i, 237.
5. Beattie: Jour. Path. and Bacteriol., 1904, ix, 272.
6. Rosenow, E. C.: Etiology of Arthritis Deformans, THE JOURNAL A. M. A., April 11, 1914, p. 1146.
7. Jackson, Leila: Experimental Myocarditis, Jour. Infect. Dis., September, 1912, p. 243.
8. Klotz: Arterial Lesions Associated with Rheumatic Fever, Jour. Path. and Bacteriol., 1913, xviii.

Digitized by Google

dental-path relationship for the admission of infectious material causative of joint lesions. Perhaps the first contribution directly relating dental infections to joint infections was published by Kenneth Goadby,[9] in which he describes a series of three cases of chronic arthritis of the deformans type wherein, by the removal of infected teeth, he was able to cure these cases, one of which had been completely disabled for a period of many months. Coincident with the treatment of these cases, he was able to isolate an organism termed by him "streptobacillus malae," which he was able to grow on egg agar. He also exhibts a streptococcus from an infective gingivitis to show the morphologic difference between it and his *Streptobacillus malae.* In this article, he recounts the result of animal inoculation in which he was able to produce by the introduction of his *Streptobacillus malae,* disease in the joints of rabbits. Just what organism this *Streptobacillus malae* is, I do not fully understand. There is not the slightest doubt, however, that his work is valuable and it is doubtless true that his *Streptobacillus malae* was in the particular cases cited by him responsible for the joint infections described. I believe to him must be given the credit for first establishing the fact that the dental path is an important avenue of infection for the planting of rheumatism.

In my own work since 1896, I have noted a seeming relationship between mouth sepsis and chronic rheumatism, because of the coincidence of cure of rheumatism following the extraction of abscessed teeth or the cure of a pyorrhea. This had occurred in my experience sufficiently often to occasionally call forth inquiry from the patient. Therefore I have been keeping rather carefully the records of those cases in which such results were noted, and, when my attention was drawn to Goadby's contribution to the liter-

9. Goadby, Kenneth: Practitioner, London, 1912, lxxxviii, 107.

Digitized by Google

ature of rheumatism coincident with the recovery of a patient, who had experienced marked relief from a somewhat troublesome joint inflammation, involving the knees, ankles, and insteps, following drainage of a chronic dental abscess, it caused an increased interest on my part in chronic joint infections, and I at once sought opportunity to make a careful study of them, and began with the case of a bedridden woman, whose history was briefly the following:

The patient had always been strong and healthy and able to do her own work. She was exposed to rain and cold, contracting as a result a severe torticollis, which was succeeded by inflammation of the shoulders, later involving the knees, ankles, and insteps. Though this patient had a considerable mouth infection, the treatment directed toward the teeth seemed to do little or no good. A vaccine was prepared and administered with little or no benefit.

Despite the discouragement in this case, I persisted in this work and when the opportunity to do a systematic research, supported by animal inoculation, presented itself through the use of funds appropriated by the National Dental Association, I was enabled to continue my study in the university hospital of the school of medicine, in cooperation with the medical staff of the college of medicine and with the constant help of Dr. Arthur T. Henrici, instructor in bacteriology in the school of medicine. I am also indebted to Dr. Harold J. Leonard, who has carried out the mouth treatment in those patients resident in the university hospital, of which there were in all sixteen cases, seven of which gave an acute history. Our method of study has been briefly as follows:

When patients presenting joint infection have entered the hospital, they have been referred to us for investigation and treatment of mouth conditions, whereupon careful roentgenographic examination of the teeth and jaws has been made in the roentgenogram laboratories of the hospital. Whenever dental abscesses were present, we have isolated the abscessed teeth with dry

Digitized by Google

gauze, cleansing the tooth or root with iodin, and whenever possible, cauterizing the tissue about the neck of the tooth, then extracting the tooth and biting off the root tips with sterile forceps, which tissues have been immediately dropped into culture mediums. These plantings have invariably produced, among other organisms, the *Streptococcus viridans* and this has been the organism which we have used in our animal inoculation in the intensive study of a certain number of these cases.

Though we have carried on intensive study and animal inoculation from material obtained from a comparatively few of the patients presented in this series, we have invariably found the *Streptococcus viridans* present in the confined dental abscess, and, in order to satisfy ourselves as to its common presence in the tissues about the teeth, we have cultured up to the present time from 220 patients and have invariably found this organism to be present not only in the confined dental abscess but in the superficial tissues of the peridental membrane about the teeth. We have found this so constantly that we were impressed with the idea that it must always be present. We, therefore, have attempted to obtain teeth which were free from *Streptococcus viridans* and to that end have extracted a number of living teeth containing healthy pulps. The roots of these living teeth with healthy pulps have usually also afforded growth of *Streptococcus viridans* when planted in the manner just described unless we cauterized the gingival crevice. Following this technic, we have been able to find, out of a total of twenty vital teeth examined, ten teeth containing living pulps, the roots of which have proved to be germ-free when planted in broth. We believe that the dental path is commonly infested with *Streptococcus viridans,* not only the superficial tissues immediately surrounding the teeth but all dental abscesses.

Digitized by Google

We have been able to produce typical joint lesions in three rabbits by its inoculation. We have also been able to secure a large number of satisfactory recoveries from joint infection by the elimination of peridental infections, in some cases by extraction, and in others, by drainage of abscesses or the elimination of pyorrhea pockets. In all, we have in our series 127 cases which it has been my fortune to observe including the 16 cases before mentioned in which the patients were resident in the university hospital. Twenty-five patients have been bedridden, 102 have been of the ambulatory type, only 15 of the 127 commenced with chill and fever, and of these 15 commencing with chills and fever, tonsil and throat infection was noted in all save 2. The infection in these two cases was due to a rapid and excessive work to eliminate pyorrhea pockets and abscesses, suddenly overloading the circulation of the patient with bacteria from these lesions.

The bedridden cases with few exceptions were of the chronic type, some of them being absolutely helpless, two of them in one family, man and wife, the man at present has been in bed two years, and incapable of doing anything for himself, the wife having been helpless now for eight years. The extraction of the abscessed teeth for the man produced streptococci in rich culture, though he was unbenefited by the extraction or by a vaccine subsequently administered from the cultures obtained from his abscesses. The wife refused treatment, though the gums in this case contained the roots of twenty broken-off teeth. As this patient declined to go to the hospital, no treatment was attempted.

The 102 ambulatory cases very from individuals presenting a mild soreness of the joints to persons going about on crutches. They vary in length of time of the disease from a few weeks to many years. None of them have complained of either chill or fever, the disease beginning in the great majority of cases with tenderness in the muscles of the neck, particularly the

Digitized by Google

sternocleidomastoid. Oftentimes, the mandibular joint is involved. Following tenderness in the mandibular joint and muscles of the neck, the shoulders are commonly attacked. In fifty of these cases, however, the first tenderness noted was in the finger joints, oftentimes a single joint being sore for a considerable period of time before the others commenced to be tender.

Following the fingers, the shoulder joint is next in frequence. In the lower extremity, the knee joint has been first attacked in 65 per cent. Later the joints of the feet, and of these, the metatarsopharyngeal articulation of the great toe is most often attacked. The disease when of the dental-path origin seems to be characterized by exacerbation and remission. Sometimes, weeks or months intervene between them, but each exacerbation is generally a little worse to bear than its predecessor. Fever is rarely present, hyperplasia of the connective tissues about the joints being constantly present. This hyperplasia of the tissue about the joint gradually leads to great thickening and effusion and finally to exostosis. One of the fairly constant features is the partial disarticulation of many of the phalangeal joints of both hands and feet.

Eventual destruction of the articular surfaces of the knee joints is to be expected, though it is comparatively slow in its progress. First evidence of destruction of the articular surface is made evident to the patient by a mild crepitus accompanied by pain, which crepitus sometimes increases to a sufficient degree to be heard at a distance of several feet when the joint is put in motion. It would seem, therefore, that arthritis of dental-path origin is characterized by slow onset with exacerbations and remissions, which exacerbations seem coincident with the filling to distention of dental abscesses or retention of pus from deep pyorrhea pockets, which drain directly into the circulation.

The amount of material absorbed may be great, as a pyorrhea case with one-quarter inch average depth of pocket has 7½ inches of ulcerating surface

Digitized by Google

from which to absorb pus, which in the end firmly seats disease in the tissues of the individual. I have constantly noted exacerbation of joint inflammation following surgical treatment of pyorrhea or the curettage of alevolar abscesses, and exacerbation is particularly likely to occur as tension of continued abscess fluid increases.

Treatment of pyorrhea pockets by curettage and evacuation of dental abscesses confers a double benefit. Such surgical interference necessarily inoculates the patient with a large number of organisms, inducing an effect similar to that of an efficient vaccine, with the added advantage that the constant supply is shut off from the focus disturbed. When many pyorrhea pockets or abscesses exist, it is important to permit from three to six days to intervene between treatments in order to gain the full advantage of what might be called surgical autoinoculation. Certain it is that the above method brings about a constant and permanent gain generally ending in cure, whereas if sudden complete extirpation of all foci is practiced, as, for example, extraction of all the teeth at once, as is done in some instances, or extraction of all the teeth and removal of tonsils on the same day, the end result will be positive harm.

This type of arthritis is easily controlled when of dental origin, if the foci of infection are early recognized and eliminated. When, however, such foci obtain in an active state for a considerable period of time, the disease becomes so firmly fixed that elimination of the primary focus does little in the way of repair, though elimination does limit further progress of the disease. The kidney, blood vessels and heart relationships in arthritis of dental-path origin are similar to those that exist with other types of arthritis, for in our experimental work we find that while organisms obtained in the dental path may cause acute inflammation in the joints of animals inoculated, they also attack heart, kidney and blood vessels. The

Digitized by Google

dental lesion presents a very favorable site from which to secure the offending organism for the purpose of obtaining material for a vaccine, and the elimination of the dental neighborhood infection by extraction is always helpful if such extraction is carried on at intervals and treatment given gradually, whereas if elimination is undertaken rapidly and by rough surgical procedure, the disease is often unbenefited or made worse.

The great majority of cases wherein we have myositis accompanied by inflammation of articular and periarticular tissues without marked pathologic changes in the joints themselves almost invariably may be permanently cured by elimination of primary foci. When cure in this type of case does not so occur, an autogenous vaccine, the material for which should be obtained during surgical treatment, may be of great benefit. The greatest thought regarding this disease when of dental-path origin is that it is certainly preventable and generally curable if taken early, whereas if left until grave pathologic changes in the articular tissues have occurred, treatment at the most can only relieve pain and prevent involvement of other joints.

716 Donaldson Building.

ABSTRACT OF DISCUSSION

ON PAPERS OF DRS. HAMMOND AND HARTZELL

Dr. J. W. Cokenower, Des Moines, Ia.: In consideration of the fact that the oropharyngeal cavity is not much less than a septic tank for infection, it is not strange that we should look to this cavity for the source of many of the infections that we find in joint disease. Two years ago at Minneapolis before this section I read a paper on joint disease due to infection from other parts of the body, especially the tonsils and teeth, and since that time I have been making a tabulation of cases that have come under my observation, numbering forty-seven, and that involved not only the joints of the upper, but the joints of the lower extremities. In investigating their true etiology I found the percentage relation to the different parts by infection as follows:

Forty-four per cent. was traceable to the oropharyngeal cavity; only 8 per cent. to the thoracic cavity; 28 per cent. to the abdominal cavity, and 20 per cent. to the pelvis, and in each one of these cases treatment to remove the cause resulted entirely satisfactorily; hence I think that routine

Digitized by Google

treatment of joint disease should be a thing of the past. It is not difficult to get satisfactory results if you ascertain definitely the etiology. These two papers, in my opinion, are valuable on a subject that has only in recent years been given especial attention. I believe that it will be given more attention in the future. I do not believe that any joint disease should be treated, unless the etiology is positive, without referring to the oropharyngeal cavity.

Dr. Emil S. Geist, Minneapolis: We appreciate the necessity of having men who are not only tooth carpenters, but who are stomatologists, in order to take up this work successfully. As I emphasized once before, sometimes there is some tooth disturbance and a patient is sent to the dentist. He is quickly returned with his teeth pulled, or, there having been a little dental work done as a result of the reference, returned with the remark "that the teeth are all right now" and the real disease is often not recognized. In other words, we must have men of the type of Dr. Hartzell to cooperate with us in this work if we are to get results.

Dr. Henry W. Frauenthal, New York: We have considered this work so important, at the Hospital for Deformities and Joint Diseases, that we uniformly examine the gums for pyorrhea infection, and also in a great many cases it is necessary to take roentgenograms of the mouth for these blind abscesses, and in doing so we have been greatly surprised by their frequency. It has become so important, I think, that it is only going to be a short time before dentists will not alone fill teeth, but will examine for blind abscesses. Also, a very important thing in filling teeth is that they must be *fully* filled to the tip of the root and not opened up for the infection of the roots.

Dr. H. R. Allen, Indianapolis: As a factor of safety, our attention should be called to one point in tonsillectomy. Nose and throat men have two procedures: local anesthesia is one, and general anesthesia is the other. If you refer a child to a nose and throat man to have the tonsils removed and he uses a general anesthetic and allows one or both lungs to fill up with blood, you lose the child, and it puts a bad mark down both for the orthopedist and for the nose and throat man. I refer no case for tonsillectomy to a nose and throat man who uses general anesthesia unless he guarantees to me that the child's mouth and head will be held lower than the rest of the body. I feel rather emphatic on this point, because one year ago my right lung was filled and my left up half way, which only left the upper half of my left lung for breathing purposes. I feel very fortunate in being able to be here today, as I had a serious attack of pneumonia following my tonsillectomy. It is merely a matter of elevation. It is a simple mechanical fact that fluids will flow down

Digitized by Google

hill. They will flow into the lungs if the lungs are down or they will flow out of the mouth if the head is low.

Dr. M. C. Harding, San Diego: I think we have all had the experience that Dr. Hammond speaks of — looking for the focus, then hoping or thinking we had found it and cleared it up, but failing to get a recovery from the arthritis. I am sure that has been my experience. For a number of years past I have been making a routine examination of all of my patients so far as the teeth, nose and throat conditions are concerned, but I was impressed with this same point, that often I did not get results. While in the Orient I noted the fact that practically every patient had enlarged cervical glands. So the examination for enlarged cervical glands has also become a routine habit with me, one which I have carried out in this country, where a surprisingly large number have been found. It is a point which no doubt many of you have carried out, but if you have not you will be surprised at the number of enlarged glands you will find. Now the glands of the neck, as you of course know, are simply a continuation of the tissues of the tonsils and adenoids. The infection can remain there indefinitely, at some future time to crop out and give trouble.

Dr. J. P. Lord, Omaha: I want to mention two points: One, that we cannot depend on the varying reports of the nose and throat men. They do not have the same conception of it as we do. I have had patients go through the hands of two or three of these men, with the specific recommendation that they determine the condition of the tonsils, and whether they required removal. After negative reports, the disease had continued, and having been backed up by an internist, who insisted the focus was there, the tonsils were removed on general principles. When that was done, the cases have been cured. Another instance: A case of mine gave me great trouble in its persistence, and the patient's parents were questioned repeatedly in regard to the thoroughness with which tonsillectomy had been done two years before. They said it had been done by a most capable specialist and it was impossible that anything could be there. But there was a fragment of tonsil and a focus there. We had it removed. The laboratory demonstrated the presence of the streptococcus. The patient got well. I do not take the testimony of anybody. See that any doubtful focus is removed, no matter where it is, even though you have to go to the appendix or gallbladder for it.

Dr. Thomas B. Hartzell, Minneapolis: I should like to say that I do not advocate or wish to convey the idea that the dental path of infection is more than one element in this matter of arthritis, but slides which I have prepared show bacterial masses on the teeth, their port of entrance, and channels of distribution.

Digitized by Google

SYPHILIS OF THE SPINE

ITS FREQUENCY AND THE VALUE OF ITS CHARACTERISTIC LESIONS AS A DIAGNOSTIC SIGN OF SYPHILIS *

JAMES L. WHITNEY, M.D.

AND

WALTER I. BALDWIN, M.D.

SAN FRANCISCO

There is a general belief that syphilis of the joints is a rare disease. This is the more remarkable inasmuch as the various forms of syphilitic arthritis have been clearly enough described, not only in separate papers, but in textbooks as well. For example, Goldthwaite, Painter and Osgood[1] include in their textbook an accurate description of the various lesions which may occur, and give references to literature, but add, as to frequency, that "there are great differences of opinion," and state of the toxic form (type of arthritis deformans): "This must be rare, we believe, in this country." On the other hand, many observers have believed that the incidence of joint lesions is high, especially in hereditary cases. Thus, among the latter, von Hippel asserts an incidence of 56 per cent., and Fournier of 40 per cent. The recent paper of O'Reilly[2] should be mentioned, in which he contends that this disease is much commoner than usually supposed, and furnishes a full review of the literature.

With regard to the frequency of syphilitic joint lesions in general, we shall here only refer to the paper by one of us (Whitney) in which it is shown that

* From the University of California Medical School, with the aid of a grant from the George Williams Hooper Foundation for Medical Research.

1. Goldthwaite, Painter and Osgood: Diseases of the Bones and Joints, Boston, D. C. Heath & Co., 1909, p. 441.
2. O'Reilly: Am. Jour. Orthop. Surg., 1914, xi, 3.

Digitized by Google

among 544 syphilitics studied in the University of California Hospital, the diagnosis of syphilitic joint lesions was made in 83, or 15.2 per cent. These joint cases are listed in Table 1.

TABLE 1.—SYPHILITIC JOINT LESIONS AMONG 544 CASES OF SYPHILIS

Infectious type (including both synovitis and destructive lesions):	
General or multiple	9
Elbow	3
Finger	1
Hip	8
Knee	3
Spine	41
Toxic type	18

It was further found that of all cases of arthritis seen, 18.7 per cent. gave evidence of being syphilitic Of the infectious type of arthritis 27.9 per cent. were syphilitic, and of the toxic type 8.2 per cent. These figures are striking, and show that syphilitic joints are much commoner than is generally supposed. Even of the arthritis deformans type, syphilis seems to be a causative factor in a very considerable number.

It will be noticed that among the joints involved, the spine is by far the commonest. If the incidentally discovered abnormalities of the spine had been included, which were not considered important enough to be mentioned as a separate diagnosis, the figures would have been far more striking.

We have for some years in the University Hospital recognized as extremely common, and very characteristic, certain lesions of the spine found in syphilitics. For this view Dr. S. J. Hunkin of San Francisco is primarily responsible, who used to insist on this fact long before the Wassermann reaction gave him the confirmation needed to convince others.

The following study was undertaken to put our strong impressions into the definite form of figures. A series of 100 cases of syphilis was carefully examined for joint lesions, with special reference to the condition of the spine. The cases were those of patients who happened in, day by day, to the medical clinic, and the only selection was in choosing only proved syphi-

Digitized by Google

litics, and in rejecting four who, though showing, as we believed, the characteristic spinal lesions, presented also complicating factors (in one case a gonococcus urethritis, in one a rheumatic fever, and in two a history of trauma).

The results of this study were rather more striking than we had anticipated, for out of 100 cases were found only twenty-six with perfectly normal spines (Cases 1 to 26), while six more are classed as doubtful (Cases 27-32).[4] The remaining sixty-eight cases had spinal abnormalities of some kind, and of these all but four were of a type which we have learned to consider more or less characteristic of syphilis.

As to the nature of these arthritic lesions occurring in syphilis, we distinguish, as already indicated, the infectious and the toxic type. The latter form is of the nature of what is often called arthritis deformans, hypertrophic and villous lesions being present, and less often atrophic changes. Usually many joints are involved, the spine being among the commonest. In such a case the spine is more or less uniformly stiff, and the Roentgen ray will usually show the characteristic osteophytes of hypertrophic joint-disease.

Of the infectious type, two forms are easily distinguishable. One is destructive, presumably a gummatous formation in the vertebral body (in other joints at the epiphysis), leading to a picture which closely resembles tuberculosis, and which, we feel sure, is commonly diagnosticated as such.[5]

In this paper we shall not go into a detailed description of the toxic or of the gummatous varieties, since they have been accurately described by many observers.

4. It is suggestive that nineteen of these patients had had early treatment: in two cases indifferent, in seven considerable and in ten vigorous.

5. Closely allied to this group is the Charcot joint in tabes, which Eloesser of this city has duplicated experimentally by traumatizing a joint whose posterior nerve roots had been cut. We suspect that in some of these cases there may be, on occasion, an actual invasion by the *Spirochaeta pallida*, giving a mixed clinical picture, so that it is at times impossible to be sure whether the lesions are gummatous or purely neuropathic in character.

Digitized by Google

The second form of the infectious type, however, seems to have escaped almost unnoticed, and deserves more careful consideration. This form consists in a synovitis without destructive change. As occurring not uncommonly in the knees of congenital cases, this lesion has been long recognized; but the main contention of the present paper is its commonness in other joints, especially those of the spine, and its occurrence in acquired syphilis as well as congenital.

In the spine this process attacks the synovia of the various spinal joints, leading at first to lessened motion from spasm, but as the acuteness of the process subsides, adhesions are usually formed which limit motion, and in many cases give complete fixation. As far as can be judged, these adhesions are permanent, and are entirely unaffected by antisyphilitic treatment. They may, however, be broken up by forcible manipulation, a measure which we have often advised when there was enough deformity to give a faulty posture with strain.

When stiffening occurs, either from spasm or from adhesions, there is likely to be a characteristic deformity which may suggest an early form of Pott's disease. This may be either a slight prominence of the spines, a flattened area, or even a shallow depression. The question of whether the deformity is to consist of a forward or a backward bowing is largely dependent on the natural curves at the area involved, and the consequent directions of strain. But the suggestion is here tentatively made that a second factor may be operative, namely, that the flexor spasm may predominate in case the process involves chiefly the intervertebral joints, and the extensor spasm where the articulations of the laminae are the main seat of trouble. The former would tend to produce a convexity, the latter a concavity of the spinal outline. Perhaps the most characteristic single type of deformity is a prolongation of the dorsal curve into the dorsolumbar region, where a concavity is normal, or

Digitized by Google

a flattening at this level. It is also to be noted that deformity may be altogether absent until tests of mobility show an area of more or less complete fixation.

It appears that the spine offers ideal conditions for the formation of permanent adhesions, being composed of a series of joints which interplay and functionate in concert. In case one part of this complex is immobilized by spasm, its function can be completely taken over by neighboring parts, and the affected joints are thus allowed to remain fixed until the adhesions have become permanent. On the other hand, in such joints as the knee or wrist it is impossible to shift function in this way, and feeble adhesions from a low-grade process are almost inevitably broken down.

It is characteristic of this condition that only a limited number of vertebrae are involved as a rule, thus distinguishing this form of stiffness rather sharply from osteo-arthritic changes, which in general are likely to be pretty evenly distributed throughout the back. Reference to Table 2 will show that the stiffness frequently affects only three or four vertebrae, though the commoner occurrence is in from six to eight, and sometimes the whole dorsal region, or even the whole spine is affected. Thirty-six of the 100 cases have lesions rather strictly limited in extent (Cases 33-68); twenty-five have a distinct localization, and in addition a lesser or greater stiffness of the whole spine (Cases 69-93). The localized areas we believe to be always of the infectious type; the general stiffness may be a lesser grade of the same infectious process, or may represent a (toxic) osteo-arthritis of the spine on which is superimposed the infectious local process. Some of the cases (71, 81, 88, 92) have more or less well-marked osteo-arthritis or other joints to suggest that the spinal process is also toxic.

The active synovitis is a relatively early manifestation of the disease. Cases 35, 37, 45, 47 and 68 are examples of this early occurrence. On account, how-

Digitized by Google

Fig. 1.—Case 90. Tabes. General spinal stiffness, most marked in upper dorsal region. Showing maximum hyperextension possible, also marked hypotonicity (see Fig. 2) which allows patient to put palms to the floor, and even to bend elbows, with knees kept straight.

Fig. 2.—See legend Figure 1.

Digitized by Google

Fig. 3.—Case 66. Tabes. Marked stiffness ninth dorsal to first lumbar; fair mobility elsewhere. Showing maximum hyperextension and hypotonicity (Fig. 4).

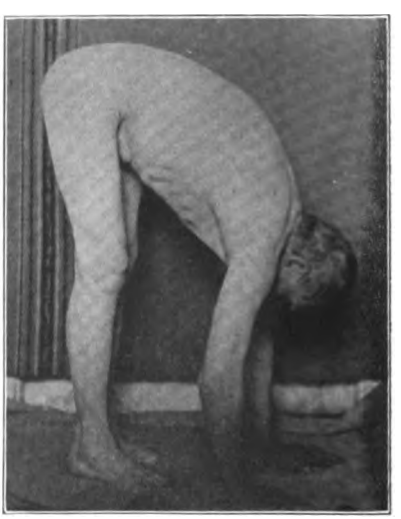

Fig. 4.—See legend Figure 3.

Digitized by Google

ever, of the persistence of the adhesions which so frequently follow, the characteristic deformity and stiffness appear to remain throughout life. For this reason they are found in numerous cases in which the disease occurred years before, the Wassermann is negative, and there is every evidence that syphilis as an active disease is abolished. This fact adds to the value of these lesions in the diagnosis of syphilis, namely, that it is found in old syphilitics, when every other evidence of the disease may be lacking.

Pain is usually not a prominent symptom even in the early (active) cases, though we believe that a large part of the backache and "rheumatic pains" of secondary syphilis may be explained on this basis. As compared to tuberculosis, the pain on motion and the sensitiveness, as well as the consequent spasm, are not striking, even in case of destructive lesions. Roentgenograms of the spine in the synovial form are practically negative, showing no appreciable bony change in either early or late stages.

There is one more striking characteristic of these cases. This is a frequently occurring hypotonicity of the ligaments and muscles of the uninvolved portions of the spine, and notably of the sacro-iliac joints and the hips. Out of thirty-six patients with sharply localized processes, but otherwise normal spines, eighteen could touch the floor with their fingers, keeping the knees straight (Cases 51-68). Of twenty-five patients with general as well as localized stiffness, eleven could do the same (Cases 83-93). Of seven patients with evenly distributed spinal stiffness, two could touch the floor (99 and 100). Not a few of these could put palms to the floor, and two or three could then bend their elbows, still with straight knees. The usual tests for sacro-iliac relaxation were invariably positive in these cases of hypotonus.

This hypotonicity was described years ago by Frenkel as a sign of tabes, and it will be observed that several of the present series which had the most

Digitized by Google

marked hypotonus were cases of tabes or cerebrospinal syphilis. But this is by no means exclusively a characteristic of the cases with nerve syphilis. Instead of calling it with Frenkel a sign of tabes, we are inclined to call it a sign of syphilis, which is usually more marked in nerve cases. It is also to be remembered that a considerable degree of hypotonicity, to the extent, at least, of the ability to touch the floor easily, is by no means uncommon in normal people, and therefore cannot, when alone, be considered pathologic.

The characteristic thing is not the hypotonicity alone, but this combined with a stiff back, or with a back showing areas of restricted mobility. This combination of the two findings we have long regarded as almost sure proof of syphilis, and it is one of the points which we especially desire to emphasize in this paper, that in this we have a pathognomonic sign which is of quite as much interest to the general diagnostician as to the orthopedist. The abnormalities here described are easy to demonstrate, especially after a little practice, and we have long felt that the routine examination of the spine as a part of the general examination deserves more general adoption.

In addition to the series of cases of syphilis examined, it was felt that a series of negative controls was also called for. Twenty-five patients were examined, who were thought to be certainly nonsyphilitic, and the lesions which we consider characteristic were found in none of them. At the same time, it was recognized that it is more difficult to assemble a series of known normal patients than one of proved syphilitics. A certain number of cases had to be excluded from both series because syphilis could not be absolutely proved on the one hand, or definitely excluded on the other. Of these rejected cases, a certain number had localized stiffness with or without hypotonicity, but no single patient was encountered with this finding who did not also show some other suggestion of syphilis. The

Digitized by Google

impression gained from our experience with this sign in the last several years is strong that the combination here described is at least rare in nonsyphilitic persons.

For the purposes of the present study we felt obliged to consider the Wassermann reaction as the deciding factor in the diagnosis of syphilis, cases being excluded from the positive series if the reaction was negative, unless the other evidence was indisputable. We feel no doubt, however, that we have thus excluded a considerable number of syphilitic cases. O'Reilly[2] agrees with Wysocki that the diagnosis of bone and joint syphilis must depend on the Wassermann test, and this represents the usual teaching. From this opinion we must strongly dissent. Apart from the results of treatment, we believe that a considerable number of cases of bone, and especially of joint, syphilis give a negative reaction. Thus, in the past year one of us (W. I. B.) has seen four cases of tibial osteoperiostitis with repeatedly negative Wassermann, which showed a typical clinical and Roentgen-ray picture of syphilis, and cleared rapidly on antisyphilitic treatment. We are sure, on the basis of many observations, that a not inconsiderable percentage of cases of spinal syphilis of the types here described will give a negative Wassermann. Therefore, as far, at least, as treatment is concerned, we are in the habit of paying attention to local and general findings even in the absence of a positive Wassermann. It is here that a general consultant can often be of great assistance to the orthopedic specialist, since the demonstration of any other suspicious signs amply justifies a course of specific treatment in doubtful cases.

A brief summary of the findings in the 100 syphilitic patients is given in Table 2.

Recapitulation.—Among 100 unselected cases of syphilis were found:

Twenty-six patients with normal spines, of whom seven showed hypotonicity.

Six patients classed as doubtful, of whom one showed hypotonicity.

Digitized by Google

TABLE 2.—SUMMARY OF FINDINGS IN 100 SYPHILITICS

Case No.	Hospital No.	Sex*	Age	Spine†			Other Joints	Hypotonicity‡	Probable Duration	Early Treatment	Wass. Reaction¶	Remarks
				Cervical	Dorsal	Lumbar						
1	2917	♀	32	0	0	0	0	0	12 yrs.	0	+	Keratitis.
2	505	♂	33	0	0	0	0	0	8 yrs.	++	+	Treated at U. C. H. from start.
3	3567	♂	42	0	0	0	0	0	20 yrs.	0	+	Cerebrospinal syphilis.
4	1513	♂	32	0	0	0	0	0	11 yrs.	0	++	
5	670	♂	32	0	0	0	0	0	7 yrs.	++	+	
6	12464	♀	36	0	0	0	0	0	18 yrs.	0	++	
7	4721	♂	26	0	0	0	0	0	3 yrs.	++	++	
8	13303	♂	26	0	0	0	0	0	6 wks.	++	+++	Primary; treated at once.
9	8286	♂	36	0	0	0	0	0	7 yrs.	Little	+++	
10	14344	♂	28	0	0	0	0	0	3 mos.	+	+++	
11	12013	♂	44	0	0	0	0	0	16 yrs.	+	±	Undoubted history.
12	14035	♂	30	0	0	0	0	0	4 wks.	0	+++	Primary; untreated.
13	11497	♂	29	0	0	0	0	0	14 yrs.	+	+	Pills. Three years.
14	12896	♂	35	0	0	0	0	0	2 mos.	++	+++	Vigorously treated since primary.
15	14001	♂	43	0	0	0	0	0	19 yrs.	+	++	Pills. Three years.
16	12118	♂	38	0	0	0	0	0	15 yrs.	+	+++	
17	6851	♂	31	0	0	0	0	0	2 mos.	++	+	
18	10006	♂	32	0	0	0	0	0	6 yrs.	0	None	Undoubted history.
19	11173	♀	33	0	0	0	0	0	12 yrs.	0	+++	
20	14870	♂	30	0	0	0	0	++	3 mos.	0	+++	
21	10508	♀	32	0	0	0	0	++	18 mos.	+	+++	
22	12583	♂	36	0	0	0	0	+	14 yrs.	+	—	General paralysis.
23	13981	♀	16	0	0	0	0	++	4 mos.	0	+++	
24	1129	♂	23	0	0	0	0	++	3 yrs.	++	±	Treated at U. C. H. from start.
25	10208	♀	30	0	0	0	0	+	1½ yrs.	0	None	Syphilid.
26	10990	♂	48	0	0	0	0	+	27 yrs.	0	+++	
27	13328	♂	38	0	Sl. 8-9	0	0	0	6 yrs.	Little	+	
28	357	♂	36	0	Sl. 4-9	0	0	0	9 yrs.	++	+++	
29	10837	♂	15	0	Sl. 9-11	0	0	0	6 mos.	++	+++	Primary; treated vigorously.
30	11728	♀	21	0	Sl. 8-11	0	0	0	5 mos.	++	+++	Primary; treated vigorously.
31	957	♀	32	0	Sl. 7-12	0	0	0	3 yrs.	0	++	
32	604	♀	47	0	Sl. 2-6	0	0	+	2 yrs.+	0	+	
33	12222	♂	44	0	++ 8D-1L	(2-5) 0	0	0	8 yrs.	0	++	
34	13346	♀	54	0	++ 7-11	0	0	0	20 yrs.	0	None	Gumma of leg.
35	10981	♀	20	0	++ 7-12	0	0	0	6 mos.	0	+++	
36	9554	♂	35	0	+++ 9-11	0	0	0	8 yrs.	0	+++	
37	5513	♂	31	0	++ 3-10	0	0	0	1½ yrs.	+	+++	Salvarsan after primary; nothing since.
38	5115	♀	21	0	++ 3-10	0	0	0	3½ yrs.	0	+++	
39	1415	♂	12	Sl.	+ 8-7 + 12D-1L	(2-5) 0	+	0	Congenital	0	+	Old healed case. Formerly synovitis of knees and destructive lesion of spine. No evidence of activity at present.
40	7212	♂	36	0	++ 6-10	0	0	0	15 yrs.	0	—	Gummata of buttock; rapid healing after salvarsan.
41	2621	♂	56	0	+ 1-6 ++ 6-12	0	0	0	5 yrs.	Little	+++	
42	13184	♂	37	Sl.	Sl. 1-7	(2-5) 0	Sl. hips	0	14 yrs.	0	++	

Digitized by Google

43	13411	♂	26	0	+++ 7D-1L + whole ++ 3-7	0	0	0	9 yrs.	0	+	
44	9630	♂	66	(1-4) 0	++ 5C-3D 0 4-12	0	0	0	50 yrs.	0	None	Late syphilid; undoubted history.
45	14668	♂	19	0	+ 4-10	0	0	0	2 mos.	0	+++	Primary and roseola.
46	12980	♂	13	0	++ 2-8	0	0	0	Congenital	0	+++	
47	13695	♂	25	0	++ 3-11	0	0	0	3 mos.	0	None	Syphilid.
48	14181	♂	22	0	++ 5-10	0	0	0	5 yrs.	0	++	
49	13520	♀	28	0	+ 6-8	0	0	0	?	0	++	
50	2748	♂	50	0	+ 1-6 ++ 6-11	Sl.	0	0	4 yrs.	+	+	
51	10192	♀	41	0	+ 1-12	0	0	++	19 yrs.	0	+++	
52	5057	♂	34	0	Sl. 1-5 +++ 5-11	0	0	+	10 yrs.	0	+++	
53	15029	♂	64	0	++ 5-11	0	0	+	11 yrs.	+	+	
54	1290	♂	48	Sl.	++ 7-11	0	0	+	17 yrs.	+	+++	
55	11842	♂	41	0	+ 1-8 ++ 9-12	+ 1-5	0	++	15 yrs.	0	+++	Cerebrospinal syphilis.
56	12082	♂	29	0	+ whole ++ 6-10	0	0	+	5 yrs.	0	+++	
57	3916	♂	31	0	+ whole ++ 6-10	0	0	++	2 yrs.	++	+++	
58	6665	♂	34	0	++ 5-10	0	0	++	2 yrs.	++	None	Treated U. O. H. since primary.
59	2204	♂	31	0	++ 9-11	0	0	+	14 yrs.	Little	+	Tabes.
60	2403	♀	25	0	+ 1D-2L ++ 2-7D	(2-5) 0	0	+	6 yrs.	0	+++	
61	5227	♀	22	0	++ 4-8	0	0	+	2 yrs.	0	+	
62	1338	♂	45	0	+++ 6-10	Sl.	Sl. hips	+	— yrs.	0	++	Cerebrospinal syphilis.
63	5674	♂	30	0	+ 7D-1L	(2-5) 0	0	+++	11 yrs.	0	++	Cerebrospinal syphilis.
64	14023	♀	27	0	+ 5-8	0	0	++	6 yrs.	0	+++	
65	3489	♀	37	0	+ 7-12	0	+	+	18 yrs.	0	+	Synovitis of knees and elbows.
66	13340	♂	45	0	++ 9D-1L	(2-5) 0	0	+++	16 yrs.	0	+++	Tabes.
67	6276	♀	48	0	++ 4-10	Sl.	0	+	30 yrs.	0	++	
68	11455	♀	26	0	+++ 4-8	0	0	++	15 mos.	0	+++	
69	11827	♀	36	Sl.	++ 1-12	+++ 12D-3L	0	0	14 yrs.	0	+++	Possible early tabes.
70	14971	♂	35	Sl.	++ 1-5 +++ 5-12	+	0	0	7 yrs.	+	—	Undoubted history.
71	3929	♂	49	Sl.	Sl. 1-6 +++ 6-11	+	+	0	13 yrs.	0	+++	Arthritis of almost all joints, most marked of hands.
72	13661	♂	58	0	++ 1-6 +++ 7-12	+	0	0	5 yrs.	Little	—	Undoubted history.
73	9758	♂	40	Sl.	+ 1-5 ++ 6-11	+	0	0	?	0	+	Gumma of clavicle.
74	5417	♂	42	Sl.	Sl. 1-6 ++ 7-12	+	0	0	?	0	++	
75	12572	♂	21	+	+ 1-5 ++ 5-11	++ 1-2 + 3-5	0	0	33 yrs.	Little	+++	Tabes.

* ♀ means female; ♂ means male.

† In these columns 0 means no abnormality found; + means demonstrable stiffness; ++ marked stiffness, and +++ rigidity at the level of the vertebrae whose numbers are given.

‡ In this column 0 means no abnormal hypotonicity; + means that patient could easily touch the floor with finger tips when knees were stiff; ++, patient could touch floor with knuckles; +++, still greater degree of hypotonicity.

¶ The Wassermann report does not always represent condition at the time of this examination; sometimes it is taken from the record of a considerable time before.

Digitized by Google

TABLE 2.—SUMMARY OF FINDINGS IN 100 SYPHILITICS—Continued.

Case No.	Hospital No.	Sex*	Age	Spine†			Other Joints	Hypotonicity‡	Probable Duration	Early Treatment	Wass. Reaction§	Remarks
				Cervical	Dorsal	Lumbar						
76	9784	♂	46	Sl.	+ 1-4 ++ 5-9 + 10-12	Sl.	0	0	20 yrs.	Little	+++	Tabes.
77	5365	♂	34	Sl.	+ 1-6 +++ 7D-8L	+ 4-5	0	0	11 yrs.	0	+	
78	6577	♀	12	+	+++ 2-6 + 7-12	Sl.	+	0	Congenital	0	—	Roentgen ray shows rarefaction of sacrum and ilia, and destruction of head and neck of left femur.
79	10668	♂	30	++	+	+	0	0	?	0	+	Roentgen ray shows destruction of cervical vertebrae 3, 4 and 5.
80	14300	♂	33	Sl.	+ 5-12	+	0	0	?	0	+++	
81	1504	♀	60	Sl.	+ 1-5 ++ 5-11	+	+	0	— yrs.	0	++	Moderate general osteoarthritis.
82	13852	♂	50	Sl.	++ 1-12	+ 1-3 ++ 3-5	0	0	?	0	+++	Thoracic aneurysm.
83	13160	♀	39	0	+ 1-6 +++ 7-12	+	0	++	9 yrs.	0	+++	Insane.
84	12891	♂	32	+	+++ 1-12	+	0	++	16 yrs.	0	—	Tabes.
85	14444	♂	60	Sl.	+++ 3-10	Sl.	0	+	35 yrs.	++	+	
86	1591	♂	48	Sl.	Sl. 1-4 +++ 5-11	Sl.	0	+	20 yrs.	0	+	
87	37	♂	53	0	Sl. 1-4 ++ 5-10	Sl.	0	+	23 yrs.	+	+	Cerebrospinal syphilis.
88	2006	♂	64	+	++ 1-4 +++ 5-10	+11 D-5L	+	+	— yrs.	0	+	Hypertrophic changes, hips and fingers.
89	12502	♂	56	Sl.	+ 1-5 ++ 6-11	Sl.	0	+++	35 yrs.	0	—	Tabes.
90	6980	♂	56	+	++ 3-9 + 9-12	Sl.	0	+++	35 yrs.	+	+	Tabes.
91	8892	♂	40	Sl.	+ 1-4 ++ 5-11	Sl.	0	+	22 yrs.	0	+++	
92	13139	♂	62	+	+++ 1-9 + 10-12	0	+	+	37 yrs.	0	+	Hypertrophic changes in fingers.
93	784	♂	50	+	+ 1-5 ++ 6-12	+	0	++	15 yrs.	0	None	Tabes.
94	11828	♂	50	Sl. 1-5	++ 6C-2L	+ 3-5	Hips	0	23 yrs.	0	+++	Hypertrophic arthritis of hips.
95	1313	♂	38	+	++	++	0	0	16 yrs.	0	+++	Roentgen ray suggests gumma of fifth lumbar.
96	17	♂	55	0	+	Sl.	0	0	23 yrs.	+	—	Undoubted history.
97	13580	♂	37	++	+++	++	Sl. hips	0	13 yrs.	+	—	Flamboyant case of active synovitis—"poker spine."
98	12411	♀	43	+	++	+	0	0	?	0	+	Probably hypertrophic.
99	710	♂	47	+	+	+	Sl. hips	+	?	0	+	
100	7972	♂	51	+	++	Sl.	0	++	18 yrs.	0	+++	

Digitized by Google

Thirty-six patients with sharply localized stiffness, but otherwise flexible spines, of whom eighteen showed hypotonicity.

Twenty-five patients with localized stiffness, and less marked general stiffness, of whom eleven showed hypotonicity.

Seven patients with uniformly stiff spines, of whom two showed hypotonicity.

Nine patients showing evidence of toxic arthritis in other joints.

Three patients with gumma of the spine.

One patient with destructive syphilis of the hip.

CONCLUSIONS

A localized stiffness of the spine is strongly suggestive of syphilis, being present in over half of this series, and rare in nonsyphilitic cases.

Localized stiffness of the spine in conjunction with hypotonicity of the uninvolved spine and the pelvic and hip joints is almost pathognomonic of syphilis.

It is found in obsolete as well as in active cases.

It is a sign easy to demonstrate.

A negative Wassermann reaction should not be interpreted as excluding syphilis in the presence of other signs which suggest joint syphilis.

University of California Hospital.

ABSTRACT OF DISCUSSION

Dr. H. W. Frauenthal, New York: In a paper I read before this section last year I made the statement that in my experience in examining orthopedic cases uniformly for syphilis, about 15 per cent. of them gave a positive Wassermann, either blood test or from spinal fluid. This has been borne out by other observers in France, Germany and Sweden. I simply want to refer to an interesting abstract of a paper in The Journal, June 19, 1915. The characteristic thing about spinal syphilis is the absence of deformity. The characteristics of Pott's disease are absent, while the Roentgen ray shows the increasing tissue, which is also characteristic of periostitis of the spine, and there is not the rarefied tissue from the absorption that occurs in tuberculosis of the spine (Pott's disease). I think there are a great many cases of tuberculous spines which are syphilitic, that is, a great many syphilitic spines and other joints which are treated as tuberculous; but in an institution in which uniform blood and spinal cord fluid tests are made, syphilitic joint disease is quite fre-

Digitized by Google

quent. I think that if it were a uniform custom in orthopedic institutions to look for syphilis in supposed tuberculous joints, the positive Wassermann test would be obtained frequently. One of the most important things combined with this is the fact that the men who taught, twenty-five years ago, that syphilis and tuberculosis were antagonistic will find that this does not prevail. There is often a tuberculous infection on a syphilitic base, and in order to cure the tuberculosis, it is necessary also to treat the syphilitic infection. I made this statement about ten years ago in a paper on syphilitic joint disease, before we had blood and serum determinations.

Dr. James L. Whitney, San Francisco: I had the pleasure of collaborating with Dr. Baldwin in the examination of the series of cases here reported, and should like to emphasize two points as seen by an internist rather than an orthopedic surgeon. The first is the value to both of cooperation between the specialist and the general diagnostician. Many patients are doubtless treated as tuberculous, who might, on the basis of a thorough general examination, be shown to be syphilitic. We have seen not a few such cases which, after long and fruitless mechanical treatment, yielded promptly to specific medication.

The second point is the possible value of the spinal condition as an aid in the diagnosis of syphilis in general. Diagnosticians are constantly on the lookout for signs which point toward syphilis. Of such signs I have found slight irregularities of the pupil especially valuable in directing suspicion toward syphilis. It seems to us, on the basis of this work, that the findings in the spine may prove to be equally valuable in this respect. Over half of our cases of syphilis have this localized stiffness of the spine, and over 30 per cent. have this stiffness combined with hypotonicity of spine and pelvis. The latter finding we believe to be found only in syphilitics, and even in the absence of other confirmatory evidence, including the Wassermann reaction, should be a sufficient basis for antisyphilitic treatment.

Dr. D. B. Phemister, Chicago: I should like to ask which portion of the spine shows the localized stiffness, and if Roentgen-ray examination shows bony changes in this region?

Dr. Carl C. Crane, San Francisco: A few years ago it occurred to me that there were many children in the clinics who were returning regularly for braces, splints and various other appliances in whom the diagnosis of tuberculosis had been made. They were not doing well; perhaps they were holding their own; they were pale, thin and inactive. They were given iodids and mercury, and within a fortnight a mother, nearly frantic, came in crying, saying that she could not make Johnny use his crutches any longer; that he was jumping on wagons and walking on his sore hip. The boy,

Digitized by Google

with many others, improved very rapidly, became ruddy, strong and active, and shortly afterward dispensed with his crutches and all other apparatus. This was simply an example of what was observed in many instances of so-called tuberculosis, of the hip in particular, and of other portions of the skeleton in general.

Dr. Walter I. Baldwin, San Francisco: In answer to Dr. Phemister's question, we have statistics of over 100 cases, collected mostly by Dr. Whitney, which show exactly the localization of the stiffness in the spine. I do not have time today to go into all the different phases of the diagnosis between syphilis and tuberculosis, but I have some lantern slides which illustrate this hip density with rigidity. I can say, however, that it is most common in the cervical region.

Digitized by Google

JUVENILE DEFORMING OSTEOCHONDRITIS OF THE HIP

GEORGE J. McCHESNEY, M.D.
SAN FRANCISCO

My reason for presenting a paper on this subject lies, first, in the newness of knowledge concerning it, only two years having elapsed since Perthes' article before the German Congress of Surgeons; and secondly, in the importance of recognizing the disease, and of saving our little patient from a wearisome course of treatment for tuberculosis of the joint, to which, in its early stages, osteochondritis shows a close resemblance, but in its later stages, a vast difference.

To define briefly, juvenile deforming osteochondritis (the name given by Professor Georg Perthes of Tübingen) is a progressive destruction and crushing, principally of the upper femoral epiphysis, characterized by a slight limp, mild subjective symptoms, a fairly constant limitation of abduction, and a benign course with complete recovery under little or no treatment.

ETIOLOGY

A history of limping by parents is only occasionally elicited, and would hardly seem to have any significance. The disease appears when the child is in good health, and is not especially concerned with any specific trauma, although in two of our three cases, mild injuries were associated with the onset.

Quite constantly boys are affected in the second five years of life. No explanation has been offered for this phenomenon, although one might presume

Digitized by Google

that the strenuous exercise of the male animal at this time of his life might produce a constant strain and tend to a breaking down of the structures in consequence, when no one tissue was at fault.

SYMPTOMS

A slight limp is the obvious symptom. This occurs early and persists till late, becoming more and more intermittent, and is accompanied by slight or no pain. The limp may last from two to four years, says Perthes, and then lessens, in spite of greater destruction of the epiphysis, as seen in successive roentgenograms.

The symptom next in importance is the elimination of abduction, seen constantly, and persisting much as the limp does. It is marked at first, and is due to alterations in shape of the epiphysis and acetabulum, according to Perthes, although he admits that limitation of abduction may be well developed when the flattening of the epiphysis is slight. Under narcosis he could overcome the limitation to a great degree, although not altogether, showing that muscle spasm played an important rôle. This was done in one of our cases with a similar result.

Also rather constantly is reported a limitation of in or out rotation to a slight extent. Other motions are said to be unimpaired, although in two of our cases we found limited hyperextension.

Slight shortening and atrophy are occasional symptoms of lesser note.

Pain is almost a negligible factor, and in these three cases none was elicited by our examinations. There was an occasional complaint of spontaneous pain in the early stages.

PATHOLOGY

According to the studies of Perthes, including an arthrotomy, in which the joint was inspected and specimens removed for microscopy, there is a delay in ossification of the cartilage of the epiphysis, and

Digitized by Google

to a lesser extent also in the juxta-epiphyseal cartilage of the neck and isolated areas in the acetabulum. This forms what he calls "cartilaginous isles," or defects in ossification. He also notes calcareous nodules or dark spots on the ossific nucleus of the epiphysis. As a result we have flattening or crushing of the epiphysis, because cartilage persists in places where bone is needed to bear the increasing weight of the growing child and withstand the traumatisms of a boy's rough play. Its shape also is a factor in this connection, for Quain says, "The epiphyseal cartilage in the young bone is not a flat plate situated at the junction of the head and neck, but an arched lamella, which at the summit of its convexity lies near the center of the articular head."

Later the flattened epiphysis breaks into two or three pieces, and finally unites to the neck, which has become much shorter and thicker than normal, although still preserving the normal angle.

ROENTGEN-RAY FINDINGS

These are so distinctive that Delitala,[1] in an exhaustive review, asserts that a Roentgen examination alone is sufficient for the diagnosis.

The flattening or crushing of the epiphysis is the salient feature. This is progressive, being slight at first, and increasing till the epiphysis, instead of being a rounded outline, is reduced to a flattened plate or disk, often divided into two or three parts. Later these appear to fuse, and the whole finally unites to the diaphysis. The cartilaginous isles mentioned above as appearing in the juxta-epiphyseal line and in the acetabulum are sometimes seen in good roentgenograms.

DIFFERENTIAL DIAGNOSIS

Here we must consider tuberculosis, juvenile deforming arthritis, polyarticular acute arthritis or rheumatism, coxa vara and osteomyelitis.

1. Delitala: Am. Jour. Orthop. Surg., 1915, xii, 555.

Digitized by Google

To distinguish it from tuberculosis we can place considerable reliance in the von Pirquet test, in the clinical examination showing the principal limitation of motion in abduction, a little in internal rotation and none in other directions, as opposed to tuberculosis, which usually shows some limitation in all directions. The lack of pain or joint spasm is another point, while the roentgenogram, showing none of the general rarefaction of tuberculosis in the early stages, in the later offers conclusive differences in the shape of the epiphysis.

Juvenile deforming arthritis is accompanied usually by joint crepitation, the pain is quite severe, and there is considerable stiffness and marked limp. The von Pirquet test should help, and the roentgenogram sometimes resembles Perthes' disease closely as to the crushing of the epiphysis, but often shows osteophytes or spurs, which osteochrondritis does not. Furthermore, the joint cartilage is intact, a point emphasized by Perthes.

In coxa vara the roentgenogram and the von Pirquet test are our only means of differentiation; but they should be quite sufficient. Clinical examination and history may fail us altogether.

In acute articular arthritis we have acute onset, much pain and disability, limitation of motion in all directions, fever, etc. The roentgenogram would show no change.

Acute osteomyelitis should present no difficulty. In chronic or healed osteomyelitis, reliance should be placed on the history and Roentgen findings.

TREATMENT

Perthes, with the widest experience of any one, concludes that operation is not indicated, that correction of abduction under anesthesia may be a good procedure, and that plaster spicas do no harm beyond inducing some atrophy, but that extension with massage is probably better.

Digitized by Google

I cannot agree with Delitala, who thinks that weight bearing has nothing to do with the crushing of the epiphysis, and that intimate alteration in the process of ossification is the only factor. Until we know the pathology absolutely and definitely, the child should be protected from weight bearing in the acute stage, but in the later stages allowed to run about regardless of the apparently alarming changes the Roentgen ray might show, as all cases run a benign course and tend to spontaneous recovery.

Perthes reports five cases seen from five to thirteen years after onset. The history and course were typical, although thought at that time to be tuberculosis. The uniform result was a broad flat head on a short thick neck, resembling coxa vara. There was a constant slight limitation of abduction. Otherwise functions and motion were restored. There was no pain or limp.

During the last two years Dr. Sherman and I have observed three examples of this disease, with histories as follows:

Case 1.—B. F., boy, aged 3½ years, seen first by us in July, 1913, came from a family in which the parents and older children had never limped; his infancy had been normal; he had had pertussis at the age of 1½ years. He complained of pain in the left knee at the time of a fall six weeks before first seen; he limped a little and got better. Again five days before the first visit he twisted the left foot and leg; he heard a snap, and then had pain and difficulty in walking. At the first visit he walked with a decided limp, but on the table had free joint motion, except that the heel would not go so high into the opposite scarpa as normal. Two days later, when reexamined, the limp had disappeared. The von Pirquet was negative. The boy was not seen for ten months, during which time he had intermittent soreness and would limp for a few days. He then showed no limitation of motion or limp, but the roentgenographic changes were marked. Wassermann negative, normal thymus, genitalia, hemoglobin 75 per cent. In April of this year he was seen again. In the eleven months' interval he has had five or six limping spells, each lasting a day or two, accompanied by slight hip pain; the attacks lessened in severity, the last one occurring in September, 1914.

Digitized by Google

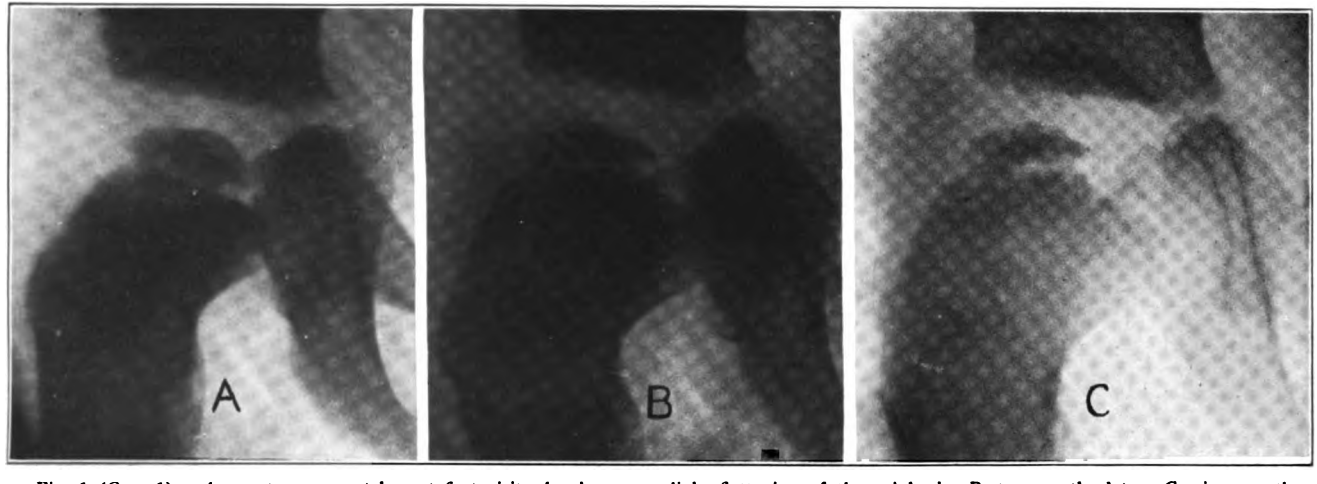

Fig. 1 (Case 1).—*A*, roentgenogram taken at first visit, showing very slight flattening of the epiphysis; *B*, ten months later; *C*, nine months later than *B*, showing fragmentation as well as flattening.

Digitized by Google

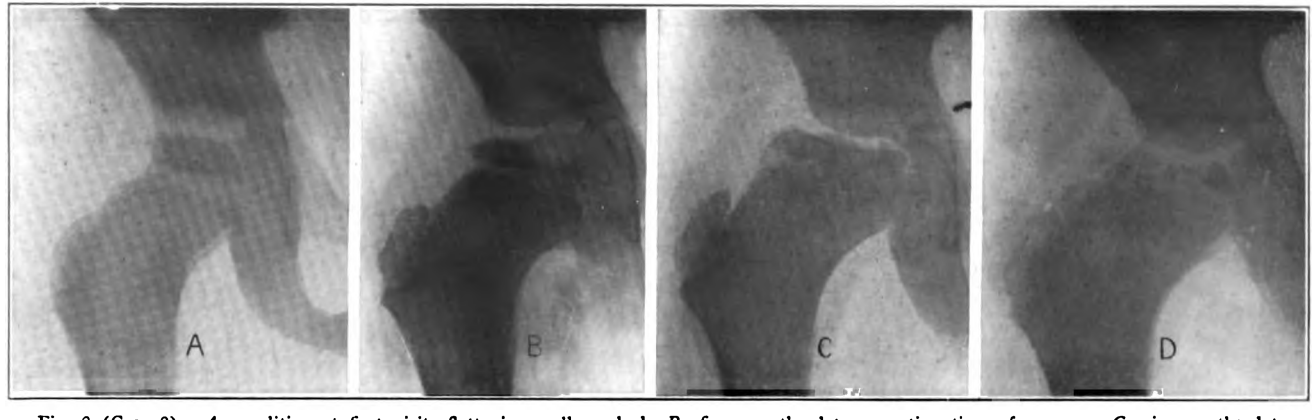

Fig. 2 (Case 2).—*A*, condition at first visit; flattening well marked; *B*, five months later; continuation of process; *C*, six months later; fragmentation appearing; *D*, seven months later; fragmented sections fusing to diaphysis.

Digitized by Google

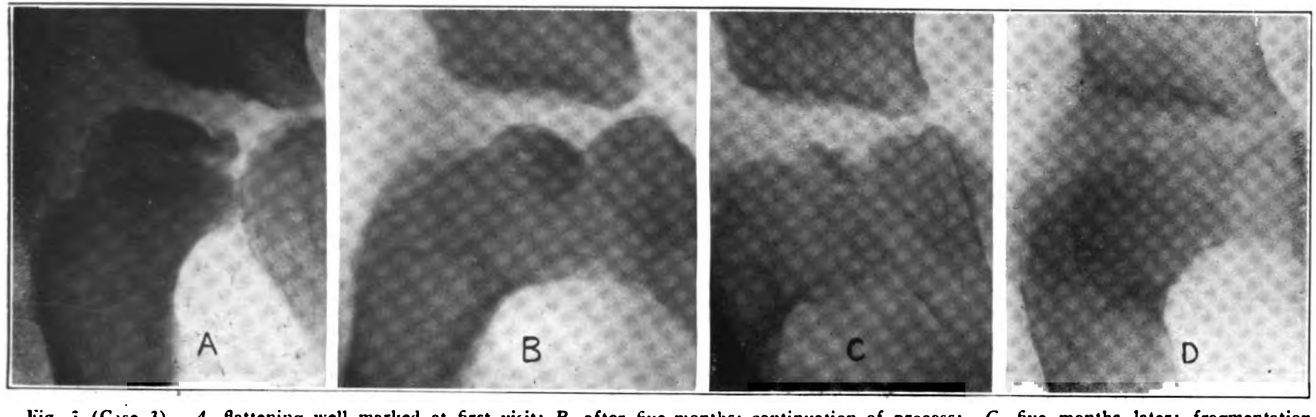

Fig. 5 (Case 3).—*A*, flattening well marked at first visit; *B*, after five months; continuation of process; *C*, five months later; fragmentation appearing; *D*, three months later; continuation of process.

Digitized by Google

Digitized by Google

The parents say he has a tendency to stumble because he will not lift the foot so high as the right one, and is a little clumsy in running. Examination shows 40 degrees' abduction, as against 45 in right. Five cm. atrophy midthigh; hyperextension normal; no shortening.

No treatment was given.

CASE 2.—L. W., boy, aged 6½, was first seen in December, 1913. The parents had never limped; the child was healthy as a baby; he had had pertussis and roseola, both lightly; he commenced to limp six months before the first visit, and complained of pain in the left knee, not enough to stop play. When seen in the office, he had no limp and no limitation of motion. Tonsils were removed, although no Rosenow bacilli found. A month later he had no limp, but only 14 degrees abduction were permitted, and slight limitation of hyperextension.

Von Pirquet and 2 mg. Koch's Old Tuberculin were both negative. Wassermann was also negative.

The child was put in spica and on crutches to protect the joint. This was continued four months, when the abstract of Söderlund's article[2] induced us to remove the spica and consider the condition as therein described.

The course of the disease since has been quite typical. The parents have endeavored to make him use crutches, but he is as apt as not to discard them when at play, the joint being absolutely without pain.

CASE 3.—B. C., boy, aged 7, seen first in May, 1914, with no history of limping, had whooping cough and measles lightly in infancy, but no other illnesses. Limping commenced after a fall from a tree, and the boy complained of pain in the groin. He limped a little, steadily, for three months, and then was placed under our care. We found only 15 degrees' abduction permitted, with limited rotation and hyperextension. Roentgenoscopy revealed marked flattening of the epiphysis. The von Pirquet and Wassermann tests were negative. In three weeks, the adduction and other joint restrictions being on the increase, an anesthetic was given, the adduction overcome, and a plaster-of-Paris splint applied.

At the end of seven months, or last March, there being abduction of 35 degrees, with free joint motion, splint treatment was discontinued, in spite of the increased flattening of the epiphysis, as shown in roentgenograms. Since March he has been kept on lift and crutches, although without them he has a slight limp, because of restricted motion; he has a little fulness over the neck of the femur; 25 degrees' abduction are permitted, and two-thirds normal rotation.

2. Söderlund, G.: Nontuberculous Hip Joint Disease in the Young, Upsala Läkaref. Förh., 1914, xix, Nos. 2-3; abstr., THE JOURNAL A. M. A., May 2, 1914, p. 1444.

Digitized by Google

He has had no pain since the fall from a tree when the symptoms began.

These three histories and accompanying roentgenograms are quite typical of the syndrome brought into prominence by Perthes two years ago. Keeping it carefully in mind will save a small percentage (Delitala saw six in 1,500 cases of coxitis) from the dreaded diagnosis of tuberculosis. To us also will be given the satisfaction of making a definite advance in the scientific accuracy of our diagnoses.

One should also consider that other joints may be similarly affected. Ridlon,[3] two years ago, before this section reported two cases of osteochondritis dissecans, producing defects in the cartilage of the knee, resulting in small free bodies in the joint. Other rare and little understood joint affections may in time be grouped under a common pathology, having as the salient feature an inflammatory defect, a breaking down or delayed ossification (as in Perthes' disease) of the cartilage.

350 Post Street.

ABSTRACT OF DISCUSSION

Dr. H. M. Sherman, San Francisco: The cases were of interest to us because we had read of the condition before we found it in one of the children. The diagnosis must be made primarily, because an inaccurate diagnosis might cause one to put the child into a splint for a long while when it might not be really necessary. The local diagnosis, apart from the general one, can be made on two bases: first, on the clinical examination, in which one does *not* find the typical symptom of a hip joint tuberculosis, and second, by means of a roentgenogram. These two things, with a negative von Pirquet and a negative Wassermann, should serve to establish the character of the condition. We intended to treat all of these children without any splints at all after we had made our first diagnosis, but one of them evidently was suffering a certain amount of irritation in the neighborhood of the joint, which caused a reaction that impeded motion. We thought that needed protection, so that it was put into a spica which held the hip still for a certain length of time

3. Ridlon, John: Osteochondritis Dissecans, The Journal A. M. A., Nov. 15, 1913, p. 1777.

Digitized by Google

until we could safely take it off. Since then the patient has been without splints. We have not had opportunity to watch the patients far enough into life to know what the ultimate result will be.

Dr. Haas' paper, it seems to me, comes in here with great usefulness in the experiments which he made on the results of interfering with the circulation in a bone. I refer to the case in which he showed us two pictures in which there had been interference with the growth of a metatarsal bone following an interference with the circulation outside the bone. It would look as if that might be the case in these children with osteochondritis at the hip. If there has been an injury, that might be credited with having interfered with the circulation sufficiently to change development processes. If there has been no history of an injury—and of course one cannot always get a history of all the falls that a child has, because a child cannot tell—if there has been no history, it would not be unreasonable to suppose that every child falls more or less, and that an injury had occurred, in spite of there being no record of it. Experimental work would be difficult, except on animals in which the anatomy was so well worked out that you could tell just where each artery was going; but experimental work should promise an answer to questions of etiology.

Digitized by Google

Digitized by Google

REPORT OF COMMITTEE ON THERAPEUTIC METHODS AND RESULTS IN JOINT TUBERCULOSIS

To the Orthopedic Section, American Medical Association:

Mr. Chairman and Gentlemen:—Your committee appointed one year ago to report on "Therapeutic Methods and Results in Joint Tuberculosis," respectfully submits the following:

The questions on which it was hoped that the work of this committee might shed some light are the following:

1. Are the diagnostic methods in general use calculated to differentiate tuberculous from other joint conditions?

2. Is it possible to determine and recommend for general use certain therapeutic methods as better than others in the treatment of joint tuberculosis?

3. Should similar joint lesions be treated differently in children and adults?

The committee held one meeting in St. Louis on Nov. 9, 1914, with Dr. Allison, chairman of the section, and Drs. Ely, O'Reilly and Orr present. Methods of procedure for our investigation were discussed, and the following questionnaire was agreed on:

Feb. 9, 1915.

Dear Doctor:—At the last meeting of the American Medical Association a committee was appointed to investigate and report on methods and results in the treatment of joint tuberculosis.

In pursuance of this object we respectfully request that you answer the following questions:

1. Do you diagnose tuberculous joint disease:
   - *a.* On the clinical findings alone?
   - *b.* On the use of tuberculin?
   - *c.* On animal injection of aspirated material from the infected joint?

2. In the treatment of tuberculosis of the different regions please indicate the therapeutic measures on which you are accustomed to rely.

Spine	Hip	Shoulder	Elbow Knee	Wrist Ankle
Recumbency	Traction	Splints	Splints	Splints
Jackets	Plaster	Operation	Operation	Operation
Braces	Braces			
Operation	Incision			
	Drainage			
	Aspiration			

Digitized by Google

Please comment.....
.....
.....
.....
.....

3. Do you use the same or different methods of treatment in children and adults?

Please comment.....
.....

4. Are you willing to exhibit patients treated by your methods to the committee or a subcommittee designated for the purpose?

These questions are being submitted to a large number of surgeons and due credit will be given for special methods or results. Please mail your reply in the enclosed stamped envelope.

Very truly yours.

LEONARD W. ELY, *Chairman*,
J. ARCHER O'REILLY.
H. WINNETT ORR, Secretary.

This query was sent out to about three hundred surgeons of whom somewhat less than one hundred replied.

These replies may be briefly summarized as follows:

Diagnosis:		Hip:	
Clinical findings	39	Traction	45
Tuberculin	37	Plaster	44
Animal injection	25	Braces	33
Children:		Incision	22
Conservative	50	Drainage	17
Radical	3	Aspiration	23
Adults:		Shoulder:	
Conservative	21	Splints	38
Radical	29	Operation	31
Spine:		Knee and Elbow:	
Recumbency	47	Splints	48
Jackets	50	Operation	37
Braces	35	Wrist and Ankle:	
Operation	36	Splints	52
		Operation	56

Eight general surgeons reported that they referred all joint conditions to orthopedists.

Your committee submits the results of its inquiry without comment. It recommends a continuance of the work. The chairman feels that his substitution by someone in the same region of the country as the other two members will facilitate the labors of the committee.

LEONARD W. ELY, *Chairman*,
J. ARCHER O'REILLY,
H. WINNETT ORR,
Committee.

Digitized by Google

INDEX

PAGE

Allen, H. R.: paper on fractures..... 145
Discussion on same..... 153
Discussion on focal infection and arthritis..... 194
Discussion on rickets..... 108

Allison, N.: paper on orthopedic surgery and the crippled..... 13

Arthritis and the teeth; paper by T. B. Hartzell..... 184
Discussion 193

Arthritis, sinus infection in etiology of; paper by R. Hammond.... 176
Discussion 193

Baldwin, W. I.: paper on syphilis of the spine..... 196
Discussion on same..... 209

Blanchard, W.: paper on structural changes in congenital hip dislocation 58
Discussion on same..... 66
Discussion on excision of vertebral process..... 28

Bunions, operative treatment of, by the Mayo method; paper by M. S. Henderson..... 39
Discussion 43

Cokenower, J. W.: paper on the treatment of fractures of the long bones 138
Discussion on same..... 144
Discussion on focal infection and arthritis..... 193

Conlin, B. M. J.: discussion on the operative treatment of bunions.. 45

Cowan, J. F.: discussion on lymphoid marrow and tuberculosis..... 97

Crane, C. C.: discussion on lumbosacro-iliac lesions..... 35
Discussion on syphilis of the spine..... 208

Ely, L. W.: paper on lymphoid marrow and tuberculosis..... 84
Report of committee on therapeutic methods and results in joint tuberculosis 219
Discussion on congenital dislocation of the hip..... 65
Discussion on lumbosacro-iliac lesions..... 35
Discussion on osteomyelitis..... 122
Discussion on the operative treatment of bunions..... 44

Epiphysis, transplantation of; paper by S. L. Haas..... 155
Discussion 172

Fassett, F. J.: paper on late results of excision of the transverse process of the fifth lumbar vertebra..... 19
Discussion on same..... 29
Discussion on knee joint disability..... 136
Discussion on lumbosacro-iliac lesions..... 35

Feet, painful; paper by H. W. Frauenthal..... 67
Discussion 80

Femur, anteversion of neck of, in connection with congenital dislocation of the hip; paper by R. A. Hibbs..... 48
Discussion 64

Fractures; paper by H. R. Allen..... 145
Discussion 152

Fractures of long bones, treatment of; paper by J. W. Cokenower.. 138
Discussion 143

Frauenthal, H. W.: paper on painful feet..... 67
Discussion on same..... 83
Discussion on focal infection and arthritis..... 194
Discussion on rickets..... 107
Discussion on syphilis of the spine..... 207

Geist, E. S.: discussion on focal infection and arthritis..... 194
Discussion on painful feet..... 81

Golden, J. F.: discussion on the operative treatment of bunions.... 46

Haas, S. L.: paper on experimental transplantation of the epiphysis 155
Discussion on same..... 174

Digitized by Google

Hammond, R.: paper on the role of the nose, throat and accessory sinuses in the etiology of chronic infectious arthritis..... 176
Discussion on fractures of the long bones..... 143
Harding, M. C.: discussion on focal infection and arthritis..... 195
Hartzell, T. B.: paper on the clinical type of arthritis originating about the teeth..... 184
Discussion on same..... 195
Henderson, M. S.: paper on the operative treatment of bunions by the Mayo method..... 39
Discussion on same..... 46
Discussion on excision of vertebral process..... 26
Hibbs, R. A.: paper on anteversion of the neck of the femur in connection with congenital dislocation of hip..... 48
Discussion on same..... 65
Discussion on congenital dislocation of the hip..... 65
Hip dislocation, congenital; paper by R. A. Hibbs..... 48
Discussion 64
Hip, dislocation, congenital, reduced by manipulation followed by arthrotomy; paper by J. T. Watkins..... 52
Discussion 64
Hip dislocation, congenital, structural changes in; paper by W. Blanchard 58
Discussion 64
Hip, juvenile deforming osteochondritis of; paper by G. J. McChesney 210
Discussion 216
Huntington, T. W.: discussion on osteomyelitis..... 120
Joint tuberculosis, report of committee on therapeutic methods and results in; L. W. Ely, J. A. O'Reilly and H. W. Orr..... 219
Knee joint disability due to hypertrophy of the alar ligaments; paper by R. O. Meisenbach..... 127
Discussion 136
Langnecker, H. L.: paper on lumbosacro-iliac lesions..... 30
Discussion on same..... 37
Lord, J. P.: discussion on excision of vertebral process..... 29
Discussion on focal infection and arthritis..... 195
Discussion on the operative treatment of bunions..... 44
Discussion on osteomyelitis..... 121
Lovett, R. W.: paper on the roentgenographic appearances in rickets 99
Discussion on same..... 108
Discussion on painful feet..... 80
Discussion on rickets..... 108
Lowman, C. L.: discussion on lumbosacro-iliac lesions..... 37
Lumbosacro-iliac lesions; paper by H. L. Langnecker..... 30
Discussion 35
Lymphoid marrow and tuberculosis; paper by L. W. Ely..... 84
Discussion 97
McChesney, G. J.: paper on juvenile deforming osteochondritis of the hip 210
McClure, C. R.: discussion on lumbosacro-iliac lesions..... 36
Meisenbach, R. O.: paper on knee joint disability due to hypertrophy of the alar ligaments..... 127
Discussion on same..... 136
Discussion on excision of vertebral process..... 29
Discussion on fractures of the long bones..... 144
Discussion on lumbosacro-iliac lesions..... 36
Discussion on osteomyelitis..... 124
Discussion on painful feet..... 82
Discussion on rickets..... 107
Discussion on transplantation of the epiphysis..... 173
O'Reilly, J. A.: report of committee on therapeutic methods and results in joint tuberculosis..... 219
Orr, H. W.: report of committee on therapeutic methods and results in joint tuberculosis..... 219
Orthopedic surgery and the crippled; paper by N. Allison..... 13
Osteochondritis of hip, juvenile deforming; paper by G. J. McChesney 210
Discussion 216

Digitized by Google

Osteomyelitis, subperiosteal resection in; paper by D. B. Phemister.. 109
Discussion on same..... 120
Pahl, P. C. H.: discussion on fractures..... 152
Phemister, D. B.: paper on subperiosteal resection in osteomyelitis.. 109
Discussion on same..... 125
Discussion on syphilis of the spine..... 208
Discussion on transplantation of the epiphysis..... 172
Report of committee on therapeutic methods and results in joint tuberculosis 219
Rich, E. A.: discussion on painful feet..... 82
Discussion on the operative treatment of bunions..... 45
Rickets, roentgenographic appearances in; paper by R. W. Lovett... 99
Discussion 107
Ridlon, J.: discussion on congenital dislocation of the hip..... 64
Discussion on lumbosacro-iliac lesions..... 36
Discussion on the operative treatment of bunions..... 44
Discussion on painful feet.....81, 83
Roentgenographic appearances in rickets; paper by R. W. Lovett... 99
Discussion 107
Rugh, J. T.: discussion on knee joint disability..... 136
Discussion on lumbosacro-iliac lesions..... 35
Discussion on operative treatment of bunions..... 45
Discussion on osteomyelitis..... 125
Discussion on rickets..... 107
Discussion on transplantation of the epiphysis..... 173
Ryerson, E. W.: discussion on excision of vertebral process..... 27
Discussion on the operative treatment of bunions..... 43
Discussion on osteomyelitis..... 123
Discussion on painful feet..... 82
Sherman, H. M.: discussion on fractures..... 153
Discussion on juvenile deforming osteochondritis of hip.... 216
Sinus infection and arthritis; paper by R. Hammond..... 176
Discussion 193
Smith, E. H.: discussion on osteomyelitis..... 125
Spine, syphilis of; paper by J. L. Whitney and W. I. Baldwin.... 196
Discussion 207
Syphilis of the spine; paper by J. L. Whitney and W. I. Baldwin.. 196
Discussion 207
Teeth and arthritis; paper by T. B. Hartzell..... 184
Discussion 193
Transplantation of the epiphysis; paper by S. L. Haas..... 155
Discussion 172
Tuberculosis and lymphoid marrow; paper by L. W. Ely..... 84
Discussion 97
Tuberculosis, joint, report of committee on therapeutic methods and results in; L. W. Ely, J. A. O'Reilly and H. W. Orr..... 219
Vertebra, fifth lumbar, excision of transverse process of; paper by F. J. Fassett..... 19
Discussion 26
Watkins, J. T.: paper on congenital dislocation of hip reduced by manipulation followed by arthrotomy..... 52
Discussion on same..... 65
Whitney, J. L.: paper on syphilis of the spine..... 196
Discussion on same..... 208

Digitized by Google

Digitized by Google

Digitized by Google

UNIVERSITY OF MICHIGAN
3 9015 06985 4928

DO NOT REMOVE
OR
MUTILATE CARD

Cat No 23 520

Digitized by Google

Digitized by Google